

## Case Report

# What Lurks Beneath: Lacrimal Gland Adenocarcinoma Dedifferentiation to Sarcomatoid Carcinoma

Farrah-Hani Imran<sup>1</sup>, Muthukumaran Guhan<sup>2</sup> (✉), Enda Kelly<sup>3</sup>, Jegan Thanabalan<sup>2</sup>, Farizal Fadzil<sup>2</sup>, Faridah Hanum<sup>4</sup>

<sup>1</sup>Plastic and Reconstructive Surgery, <sup>2</sup>Division of Neurosurgery, Department of Surgery, Faculty of Medicine, Universiti Kebangsaan Malaysia Medical Centre, Jalan Yaacob Latif, Bandar Tun Razak, 56000 Cheras, Kuala Lumpur.

<sup>3</sup>Department of Orthopaedics, Cappagh National Orthopedic Hospital, Finglas, Dublin 11, Ireland.

<sup>4</sup>Department of Ophthalmology, Faculty of Medicine, Universiti Kebangsaan Malaysia Medical Centre, Jalan Yaacob Latif, Bandar Tun Razak, 56000 Cheras, Kuala Lumpur.

### Abstract

This was a case of a young lady presenting with 10 year history of a mass in the right eye. It was found to be an adenocarcinoma of the lacrimal gland from histopathological biopsy. She underwent wide excision, orbital exenteration and reconstruction with a free rectus abdominis flap. Unfortunately, she had a tumour recurrence which was not controlled by radiotherapy and a second excision. The behavior of the tumour was aggressive, resulting in widespread metastases. She passed away within a year of her presentation. Of note, the histopathology report from the second excision turned out to be sarcomatoid carcinoma. This is described in the literature as dedifferentiation, or high grade transformation (HGT). Occurrence of dedifferentiation in salivary gland tumours is well-established, but not as well-described in lacrimal gland tumours. In this case, there was a severely delayed presentation of a lacrimal gland adenocarcinoma in a young person, which underwent dedifferentiation into a sarcomatoid carcinoma. This phenomena is associated with aggressive tumour biology behavior and poor prognosis, despite surgery and radiotherapy.

**Keywords:** Adenocarcinoma, lacrimal gland, pathology, dedifferentiation, high-grade transformation, sarcoma, orbit, reconstruction

### Correspondence:

Guhan Muthukumaran, Department of Surgery, Faculty of Medicine, Universiti Kebangsaan Malaysia Medical Centre, Jalan Yaacob Latif, Bandar Tun Razak, 56000 Cheras, Kuala Lumpur, Malaysia. Tel: +603-91456202 Fax: +603-91456684 Email: guhan\_m83@yahoo.com.

Date of submission: 10 Oct, 2015

Date of acceptance: 2 Dec, 2015

### Introduction

There is an old English proverb, “*the eyes are the windows to the soul*”. Thus, any disease of the eye is distressing, as it not only impairs vision but also disfigures the patient.

Our patient was a 33-year-old female who presented with a right orbital mass for a decade. Histopathological biopsy returned as adenocarcinoma of the lacrimal gland. She subsequently had wide

excision of the tumour, orbital exenteration and reconstruction with a free rectus abdominis flap. The tumour unfortunately recurred a soon after and was unresponsive to further oncological management. She passed away a few months later. The histopathology from the excision of recurrent tumour returned as a sarcomatoid carcinoma. It shows the malignancy had undergone dedifferentiation, or high grade transformation (HGT), with a poorer prognosis. Despite her late presentation, we decided on

aggressive intervention as she was young. The present rare case is being discussed.

Lacrimal adenocarcinoma commonly occurs in middle age, with a multitude of symptoms ranging from visual disturbances, to mechanical disruption and pain. Although slow-growing, there is a 4-36% chance of neural, bony and/or intracranial extension. Metastases and recurrence account for poor prognosis (1).

Dedifferentiated sarcomatoid carcinoma has been reported in the palate, facial sinuses and salivary glands. However, dedifferentiation in the lacrimal gland has not been widely reported in the literature, therefore the clinical course is relatively unknown. It is known that dedifferentiated tumours that have been reported show aggressive behaviour with poor outcomes. This highlights the importance of meticulous sampling and histological examination of orbital tumours with pathology similar to salivary gland malignancies, and its subsequent clinical implications (2).

### Case Report

We present a 33-year-old female who complained of a 10 year history of a gradually enlarging right orbital mass. It was painless but associated with gradual blurring of vision.

Upon formal examination by the ophthalmology team at initial presentation, the right eye was totally blind with no light perception and a WHO blindness score of 5, with non-axial proptosis and complete ophthalmoplegia. The ocular surface was dry, but otherwise, anterior chamber examination was normal. Fundoscopy revealed pale optic disc with presence of macular striation. The left eye was normal (Fig. 1). Magnetic resonance imaging (MRI) revealed a large lacrimal gland mass extending to the optic canal with involvement of adjacent bones, paranasal sinuses and intracranial extension. Radical exenteration and craniectomy was performed, by a multidisciplinary team. A rectus abdominis muscle free flap with anastomosis to the superficial temporal vessels was used to cover the defect (Fig. 2).

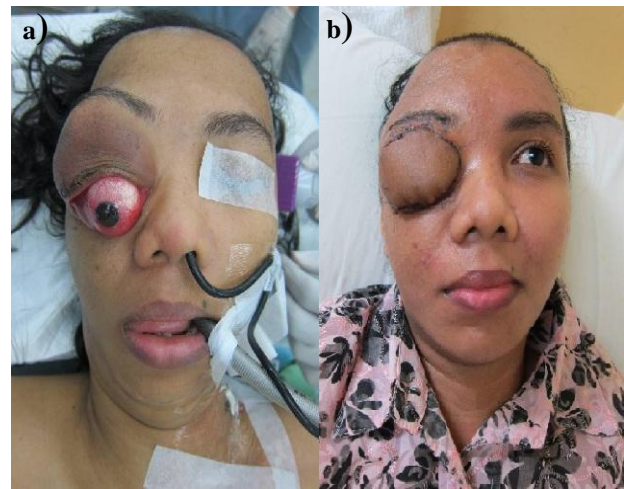Patient was fairly well after surgery however noted a painless swelling over the right side of her forehead 6 months post operatively. A repeat MRI was performed and was suggestive of tumour recurrence. Patient then underwent a course of radiotherapy 66Gy/33#, completed on 16/1/2014.

Despite this, the tumour progressed and was re-excised. Intra operatively tumour had encroached the

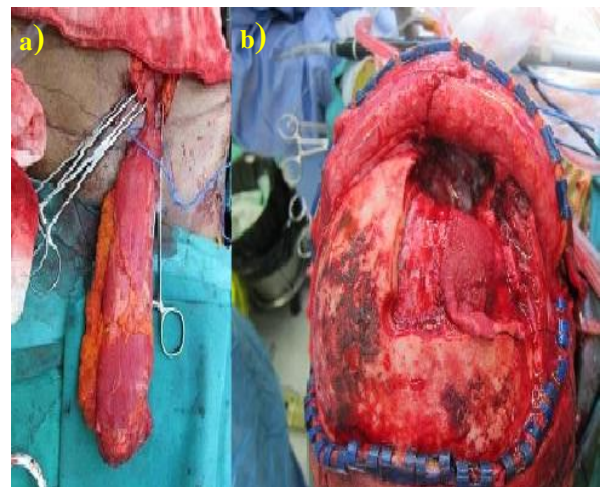
frontal region and into the overlying flap. Post operatively she had a stormy recovery complicated with pneumonia.

The histopathology of the second excision showed malignant cells extensively infiltrating the stroma forming sheets and crowded nests. Bone infiltration was also seen. When compared to the previous biopsy it appeared similar in morphology however with marked sarcomatous changes.

Eight months later, MRI and computed topography imaging revealed distant metastases to the bones, brain, adrenal glands and lungs.



**Figure 1:** a) Pre-operation b) Post-operation with successful free-flap



**Figure 2:** a) Rectus abdominis musculocutaneous flap and deep inferior epigastric vessels b) Bone and soft tissue orbital defect post-excision of tumour

Her general condition gradually deteriorated and she was managed palliatively. Patient eventually passed away 15 months after her initial presentation.

## Discussion

Timing of presentation possibly played a significant role in the outcome. She had sought medical attention almost 10 years from the onset of symptoms. The apparent reason she delayed her presentation was, focusing on marriage and having children. It was on the insistence of her family coupled with the loss of vision that she eventually sought consultation.

In reported cases, the timing of presentation was within months of the onset of symptoms. In this case, the delayed presentation of a decade no doubt exacerbated the poor prognosis. The clinical outcome was affected by 3 factors. Firstly the delay in presentation due to patient's own fixed mindset and refusal for medical attention, secondly the histopathological of polymorphous adenocarcinoma, and finally the dedifferentiation or HGT. This would have given the aggressive biological nature of the process plenty of time to infiltrate and dedifferentiate (1).

Adenocarcinoma of the lacrimal gland is the most common malignant epithelial tumor of the lacrimal gland, it is however a rare disease. It is notorious slow growing and frequently recurs despite therapy. Approximately 10% of space occupying lesions of the orbits arise from the lacrimal gland. Twenty percent of these masses are epithelial in origin and around 55% of masses of epithelial origin are malignant (3).

Overall the most common tumour type is lymphoma both within and outside the lacrimal gland (67%) followed by rhabdomyosarcoma (12%) followed by adenocarcinoma 6% and adenocystic carcinoma 5% the remainder include melanomas and metastatic disease (4).

There is no general consensus on how to manage this disease. An aggressive approach, that includes orbital exenteration followed by local radiotherapy, is recommended. Aggressive management including orbital exenteration and radiotherapy has recommended by some others, however there is debate in the literature as to the gold standard (5). There is however no apparent difference in median survival rate when compared to a more conservative approach (6). Radiation therapy may be an adjuvant in the management of extensive or recurrent adenocarcinomas even following complete excision. On the other hand, it could be argued that radiation

therapy is of little value as a salvage procedure for recurrent or residual tumours. Although irradiation can provide short-term palliation, it apparently achieves little in the long-term (7). Chemotherapy may occasionally be clinically efficacious for the recurrence of adenocarcinoma. The role of radiation therapy in management of adenocarcinoma is debatable, be it in recurrent or aggressive tumours. It may have an adjuvant role with short-term palliative benefit, yet may have limited capacity in long-term control (7).

A point to note in the repeat excision, the histopathology was sarcomatoid carcinoma. Such a difference could be attributed to either dedifferentiation of the carcinoma. Dedifferentiation is a well-established phenomenon in salivary gland tumors that is associated with aggressive behavior and poor prognosis. However, its exact nature remains unclear (6).

The exact transformation method in dedifferentiation in lacrimal gland tumours has not been fully established (2). Although reported literature on this phenomena is scarce, salivary gland tumours have been associated with dedifferentiation or high-grade transformation (HGT). Aggressive clinical progression and guarded prognosis ensues regardless of the histopathological features of the initial tumour. Links with p53 abnormalities in the HGT lesion has been shown in few cases, however the exact pathway from a molecular and genetic point of view is yet to be explored (8).

## Conclusion

The recommended management of lacrimal gland carcinoma, with or without HGT, is wide excision of the initial tumour with clear surgical margins. If the margins are involved with intracranial extension, radiotherapy and chemotherapy may be considered. Complex tumours benefit from multidisciplinary management. This is especially true in retro-orbital tumours. This case was surgically managed by the neuro, ophthalmic and plastic surgeons working together with extensive preoperative planning discussions and family meetings, working towards a common goal for successful excision and reconstruction. As clinicians, awareness and high index of suspicion for HGT tumours may help in establishing the challenging diagnosis of such cases.

**References**

1. Argyris PP, Pambuccian SE, Cayci Z, Singh C, Tosios KI, Koutlas IG. Lacrimal gland adenoid cystic carcinoma with high-grade transformation to myoepithelial carcinoma: report of a case and review of literature. *Head Neck Pathol* 2013; 7(1): 85-92.
2. Panarelli JF, Zoumalan CI, Mukkamala K, Maher EA, Iacob C, Della Rocca DA. Dedifferentiated adenoid cystic carcinoma of the lacrimal gland. *Ophthal Plast Reconstr Surg* 2011; 27(5): e119-21.
3. Shields JA, Shields CL, Epstein JA, Scartozzi R, Eagle RC Jr. Review: primary epithelial malignancies of the lacrimal gland: the 2003 Ramon L. Font lecture. *Ophthal Plast Reconstr Surg* 2004; 20(1): 10-21.
4. Koopman JH, van der Heiden-van der Loo M, van Dijk MR, Bijlsma WR. Incidence of primary malignant orbital tumours in the Netherlands. *Eye (Lond)* 2011; 25(4): 461-5.
5. Font RL, Smith SL, Bryan RG. Malignant epithelial tumors of the lacrimal gland: a clinicopathologic study of 21 cases. *Arch Ophthalmol* 1998; 116: 613-16.
6. Esmaeli B, Ahmadi MA, Youssef A et al. Outcomes in patients with adenoid cystic carcinoma of the lacrimal gland. *Ophthal Plast Reconstr Surg* 2004; 20(1): 22-6.
7. Brada M, Henk JM. Radiotherapy for lacrimal gland tumours. *Radiother Oncol* 1987; 9(3): 175-83.
8. Nagao T. "Dedifferentiation" and high-grade transformation in salivary gland carcinomas. *Head Neck Pathol* 2013; 7 (Suppl 1): 37-47.