

## Case Report

# Parameatal Cyst : A report of Two Cases and Review of Literature

Rajan Kumar SINHA, Subhabrata MUKHERJEE, Nilanjan MITRA, Barun SAHA, Jay KUMAR

Submitted: 18 Sep 2014  
Accepted: 31 Dec 2014

24, Gorachand Road, Beniapukur, Department of Urology, Calcutta National Medical College, Kolkata 700014, India

## Abstract

Cyst formation in the parameatal area is a relatively rare entity and not many cases have been reported in the literature. Two such cases are reported here. First patient was a 46 year old sexually active male who developed a spherical, cystic swelling of 1 cm in size on right lip of external urethral meatus. The second case was a 4 year old boy who presented with asymptomatic recurrent left parameatal swelling. In both the cases, cysts were completely excised and defects were sutured. Histologically, the cyst walls were lined by tall squamous and columnar epithelium. Good cosmetic results were obtained in these two cases without any recurrence at 2 two months follow up.

**Keywords:** cyst, excision, external meatus, recurrence, parameatal swelling, recurrence

## Introduction

Cyst formation in parameatal area is comparatively unusual disease entity which was first reported by Thompson and Latin in 1956 (1). These cysts generally occur on one side of urethral meatus. They are mostly asymptomatic but can cause alteration of urinary stream or occasionally interfere with sexual intercourse. Simple excision is the preferred treatment option as aspiration or marsupialisation results in recurrence.

## Case Report 1

A 46 year old married male presented with a gradually increasing cystic lesion arising from the glans penis for one and half year. The patient did not have any complain except poor cosmesis. Clinical examination revealed a non tender cystic swelling of 1 cm x 1 cm in diameter arising from left lip of urethral meatus (Figure 1). The cyst was excised completely under local anaesthesia and the cut margins were sutured with 3-0 catgut suture. The wound healed well within seven days with satisfying cosmesis. Histopathology revealed that the cyst wall was lined by squamous and columnar epithelium (Figure 2a and 2b ). The patient has no recurrence on follow up at two months.

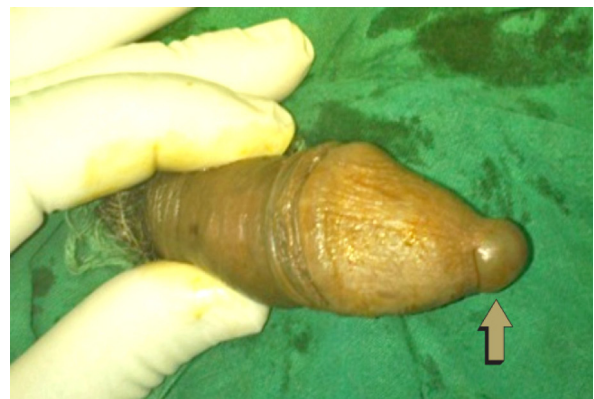## Case Report 2

A 4 year old boy presented with asymptomatic slowly increasing left parameatal swelling for

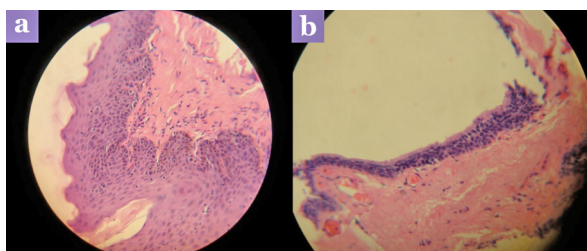
three months (Figure 3). Cyst was punctured twice by the local physician, but unfortunately it recurred within three days in both the times. When he came to us, the cyst was around 0.5 cm in diameter. We did complete excision of the cyst with suturing of edges under general anaesthesia (Figure 4). Post-operative period was uneventful and patient has no recurrence on follow up at two months.

## Discussion

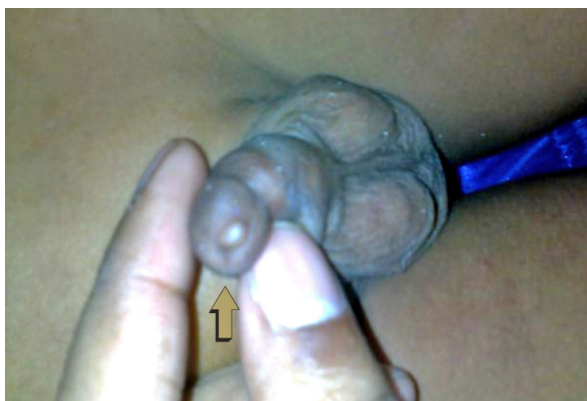Parameatal cyst is a rare lesion in male patients and till now around 50 cases have been reported in the literature (2,3). It can occur at any age (4) and the etiology is not fully understood.



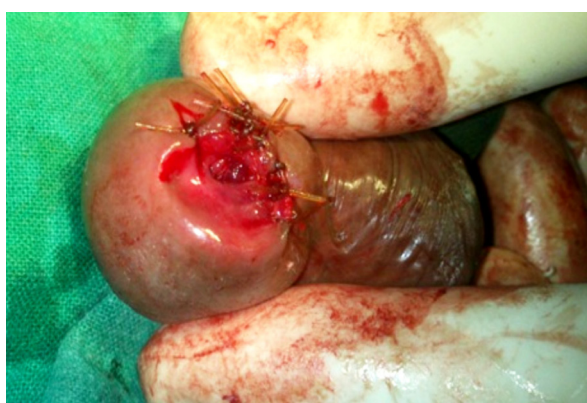**Figure 1:** Picture depicting parameatal cyst in an adult.



**Figure 2:** (a) Microscopic picture (Hematoxylin & Eosin, 400x magnification) showing squamous cell epithelial lining the cyst wall, and (b) Microscopic picture (Hematoxylin & Eosin, 100x magnification) showing transitional cell epithelial lining the cyst wall.



**Figure 3:** Picture depicting parameatal cyst in a child.



**Figure 4:** Per-operative picture of urethral meatus after cyst excision and suturing.

It can be congenital or acquired. Thompson and Lantin proposed that it occurs due to delamination or separation of the foreskin from the glans (1). Shiraki suggested that occlusion of paraurethral duct is the probable cause (5). Oka et al., (6) and Yoshida et al., (7) also supported the view of Shiraki. Hill and Ashken were of view that the obstruction of duct is probably due to infection (8). They are usually small cystic mass located at lateral margin of external urethral meatus averaging about 1 cm in maximum diameter (9). Although majority of the patients are asymptomatic, some of them may present with poor cosmesis of genitalia, disturbance in urinary flow, painful sexual intercourse, or urinary retention (4). Cyst may get traumatised and patient may present with bleeding, infection or may spontaneously resolve after rupture. The cyst wall epithelium may be columnar, squamous, or transitional (9). The differential diagnosis includes inflammatory lesion of urethral meatus (9). The treatment of choice is complete excision. Other treatment modalities include needle puncture or aspiration, which invariably results in recurrence, as it happens in one of our cases. Marsupialisation of the cysts results in cosmetically unsatisfactory result. Parameatal cyst is a benign, usually asymptomatic condition. Only a physical examination is sufficient to make the diagnosis and complete surgical excision yields good cosmetic results without recurrence.

## Conclusion

The parameatal cyst is a quite unfamiliar lesion occurring in males. Although the cysts are usually asymptomatic, patient may present for poor cosmesis of genitalia or splaying of urinary stream. The treatment of choice is complete excision as marsupialisation of the cysts result in cosmetically unsatisfactory outcome.

## Acknowledgement

None.

## Conflict of Interest

None.

## Funds

None.

## Correspondence

Dr Rajan Kumar Sinha  
MBBS (Ranchi University), MS (Ranchi University),  
MCh (West Bengal University of Health Sciences)  
24, Gorachand Road; Beniapukur  
Department of Urology  
Calcutta National Medical College  
Kolkata 700014  
India  
Tel: +91-900720 5371  
Email: rajan\_rims@yahoo.co.in

## References

1. Thompson IM, Lantin PM. et al. Parametatal cysts of the glans penis. *J Urol.* 1956;**76**:753–755.
2. Nerli RB, Patil S, Hiremath MB. et al. Parametatal Urethral Cyst Presenting with Painful Intercourse. *Med Surg Urol.* 2012;**1**:104. doi: 10.4172/2168-9857.1000104.
3. Lal S, Agarwal A, Parametatal Cyst: A presentation of rare case and review of literature. *J Clin Diagn Res.* 2013;**7(8)**:1757–1758. doi: 10.7860/JCDR/2013/5503.3257.
4. Neeli SI, Patne P, Kadli S, Hiremath S. Parametatal cysts of the glans penis. *J Sci Soc.* 2012;**39(1)**:45–46. doi:10.4103/0974-5009.96476.
5. Shirraki IW. Parametatal cysts of glans penis: A report of 9 cases. *J Urol.* 1975;**114(4)**:544–548.
6. Oka M, Nakashima K, Sakoda R. Congenital urethral cyst in the male. *Br J Urol.* 1978;**50**:340–341.
7. Yoshida K, Nakame Y, Negishi T, Negishi T. Parametatal urethral cysts. *Urology.* 1985;**36**:490–491.
8. Hill JT, Handley AM. Parametatal urethral cysts: A review of 6 cases. *Br J Urol.* 1977;**49(4)**:323–325. doi: org/10.1111/j.1464-410X.1977.tb04146.x.
9. Aggarwal K, Gupta S, Jain VK, Goel A. Parametatal urethral cyst. *Indian J Dermatol Venereol Leprol.* 2008;**74(4)**:430. doi: 10.4103/0378-6323.42884.