

Urogenital Vascular Anomalies with Bilateral Kinking of Ureter: A Case Report

Suresh TADIPI, Roshni SADASHIV, Sangeeta M, Maegyvear PIMID

Submitted: 23 May 2014

Accepted: 7 Dec 2015

Sri Devaraj Urs Medical College, Banglore Tirupathi Highway, Tamaka, Kolar, Karnataka 563101, India

Abstract

Variations in the urogenital vascular anomalies in the abdomen are very common. However, they warrant attention due to their importance in operative, diagnostic, and endovascular procedures. During routine dissection of abdomen in a male cadaver, unique urogenital vascular anomalies were observed. On the right side, the right renal artery was found to be originated from the abdominal aorta at the level of L2 and divided into five branches; the right testicular artery and inferior suprarenal artery originated from the lower branch. We also observed, accessory renal artery arising from abdominal aorta at the level of L3 and double renal veins on right side. On the left side, we found left renal artery originating from the abdominal aorta at the level of L2 and divided into two branches. Double testicular (medial and lateral) arteries were also observed. In addition to these vascular variations, bilateral kinking of ureter at the pelviureteric junction was also observed. Although the variations in the origin of urogenital vessels in the abdomen are common, deeper understanding of the urogenital vascular variations and their relations to adjacent structures is significant during surgical and radiological procedures.

Keywords: renal artery, accessory, testicular, artery, renal veins, ureter

Introduction

The renal arteries usually arise from the anterolateral or lateral aspect of the abdominal aorta, immediately below the origin of the superior mesenteric artery (1). Entering through the hilum of kidney, one renal artery usually supplies each kidney. The most common variation of renal artery is the presence of an accessory renal artery, which according to Dhar and Lal (2), is unilateral in 15% cases and bilateral in 5% of cases. This may enter through the hilum or superior or inferior poles or through the surfaces of the kidney. Alternative nomenclatures have been used to describe the accessory renal artery as supernumerary, multiple, aberrant, additional arteries, etc. Any artery arising from the aorta in addition to the main renal artery should be named as 'accessory' renal arteries, while the renal arteries arising from sources other than the aorta should be called 'aberrant' renal arteries (3). It is very important to note that accessory renal arteries are end arteries; therefore, if an accessory artery is ligated or damaged, the part of kidney which gets supply by it is likely to become ischemic (4). The presence of accessory renal arteries, if remains unrecognized, poses hazard in surgery. With the ever increasing demand for kidney transplant, it is essential for the surgeons to be aware of the possibility of donors with

multiple renal arteries (5).

Testicular arteries are paired vessels that usually arise from the antero-lateral surface of the abdominal aorta at the level of second lumbar vertebra (6). The testicular arteries may vary at their origin. One or both arteries may arise from the renal artery (4.7%–17%), suprarenal artery or lumbar artery or from a common trunk or be doubled, tripled, or quadrupled at very rare variations (7). Variations in the renal and gonadal vessels may influence the blood flow to the kidney and gonadal glands, causing some pathological conditions (8).

Therefore, a sound knowledge of the variations in the renal and gonadal vessels is important for urologists, radiologists, and surgeons in general. Here we report, a case of 54 year old male cadaver with variation in the origin and course of renal and testicular arteries, with the objective of bringing awareness to clinicians regarding the variations in the origin and course of those vessels. We hope the report would be useful to clinicians, particularly while performing invasive procedures and vascular surgeries.

Case report

During the routine dissection of posterior abdominal wall of a 54-year-old embalmed male cadaver, we observed variations in the origin

and course of renal as well as testicular vessels. The cadaver dissection was performed as a part of regular undergraduate teaching class in the department of Anatomy, at Sri Devaraj Urs Medical College, Tamaka, Kolar.

The case showed the right renal artery originating from the abdominal aorta at the level of L2 of the cadaver were divided into five branches, and the right testicular artery and inferior suprarenal artery originated from the lower branch of the right renal artery. We also observed the accessory renal artery, arising from the abdominal aorta at the level of L3, run upwards obliquely in front of the inferior vena cava and behind the ureter and testicular vessels before reaching the lower pole of the kidney. Double renal veins were also observed. The anterior renal vein passed in front of the renal arteries at the hilum and ascended obliquely before ending in the inferior vena cava, while the posterior renal vein passed behind the renal arteries and drained into inferior vena cava at the level of hilum. The testicular artery, after its origin from abdominal aorta, was seen passing downwards through the space in between those two renal veins.

The left renal artery originated from the abdominal aorta at the level of L2 and divided into two branches; at the hilum, the renal artery passed in front of renal vein. Double testicular (medial and lateral) arteries were also observed. We observed the medial testicular artery arising from the ventral surface of the aorta at the level of origin of renal artery behind the left renal vein and it then arched over the left renal vein before passing downwards along with testicular vein. On the other hand, the lateral testicular artery was seen arising from the lower branch of left renal artery. We also found arterio-venous anastomoses between lateral testicular artery and testicular vein. Both the right and left testicular veins drained into the corresponding renal veins. In addition to these vascular variations, the case also showed bilateral kinking of ureter at the pelvi-ureteric junction and dilatation of the ureter at pelvic brim. No evidence of stones, hydronephrosis, perirenal streakiness and pelvi-ureteric junction obstruction were observed.

Discussion

The renal arteries, a pair of lateral branches of abdominal aorta, arise from the aorta, immediately below the level of origin of the superior mesenteric artery. One or two accessory renal arteries are frequently found entering the kidney either above or below the hilum. Many abnormalities of renal

arteries are due to developmental position of the kidney. In the present case, we observed both the kidneys showed incomplete medial rotation. Supernumerary arteries supplying the lower pole have been reported (9). These arteries might arise from abdominal aorta or inferior mesenteric artery. In case of this cadaver, we observed the accessory renal artery on the right side arising from abdominal aorta and supplying the lower pole.

Dhar and Lal found accessory renal arteries in 20% of the specimens they dissected; as mentioned before, the anomaly was unilateral in 15 % cases, while bilateral in 5 % of cases. In the present case, we found the accessory renal artery arising unilaterally at the level of L3 on the right side. Since each accessory renal artery is connected to segmental arteries, it increases the risk of bleeding during urological surgery or renal transplantation, segmental ischemia, and postoperative hypertension.

R.J. Merklin and N.A. Michels observed, The supernumerary renal arteries may originate either from aorta or main renal artery, or from other arterial sources (10). We found the supernumerary renal artery originated from the main right renal artery in the cadaver specimen. A supernumerary renal artery is a common arterial variation, which warrants consideration in a variety of urologic and retroperitoneal operations. Supernumerary renal arteries can be associated with other uro-vascular variations and anomalies such as duplicated renal veins, aberrant origin of the gonadal arteries and kidney malrotation, as found in our case.

Pick and Anson observed multiple renal veins on the right side; in their series 27.8% additional veins were on the right side, while only 1% on the left side (11).

According to Satyapal et al., the incidence of additional renal vein was 26 % on the right side as compared to 2.6% on the left side (12). In the present case, we observed double renal veins on the right side, while one anterior and one posterior renal veins encircling the testicular artery (Figure 1).

The embryological explanation of accessory renal artery has already been discussed by Felix (13). In an 18 mm foetus, the developing mesonephros, metanephros, suprarenal glands, and gonads are supplied by nine pairs of lateral mesonephric arteries arising from the dorsal aorta. Felix divided these arteries into three groups as follows: the first and second arteries as the cranial, the third to fifth arteries as the middle, and the sixth to ninth arteries as the caudal group.

The middle group gives rise to the renal arteries. Persistence of more than one arteries of the middle group results in multiple renal arteries. Felix was the first to note the embryological origin of the gonadal artery. One of the caudal arteries usually persists and differentiates into the definitive gonadal artery. However, the persistence of a cranial lateral mesonephric artery may result in a high origin of the gonadal artery e.g., from suprarenal artery (13).

According to Çiçekcibaşı et al, the persistence of middle group of lateral mesonephric arteries gives rise to a gonadal artery that originated from the renal artery (14). In the present case, the lateral testicular artery might have developed from the middle group of lateral mesonephric arteries, while the medial testicular artery might have developed from the cranial group of lateral mesonephric arteries.

Deepthinath et al. found that in case of double left testicular arteries, one originates from an accessory renal artery, while the other from the main renal artery (15). In the present

case, the double left testicular arteries have the following origins: while the medial testicular artery arises from the aorta (cranial group), the lateral testicular artery originates from the left renal artery (middle group) (Figure 2).

Rusu also described a case of bilateral doubled testicular arteries with a left testicular arterial arch around the left renal vein, much similar to our variation (16). We found unilateral double testicular arteries on the left side, and the medial testicular artery was seen arching over the left renal vein. Arching of the testicular arteries over the left renal vein may cause compression of left renal vein resulting in left renal vein hypertension.

Conclusions

Although the urogenital vascular anomalies are common, they should not be neglected. Such variations are important from the academic, surgical and radiological point of view. We believe that the present case study involving a 54-year-

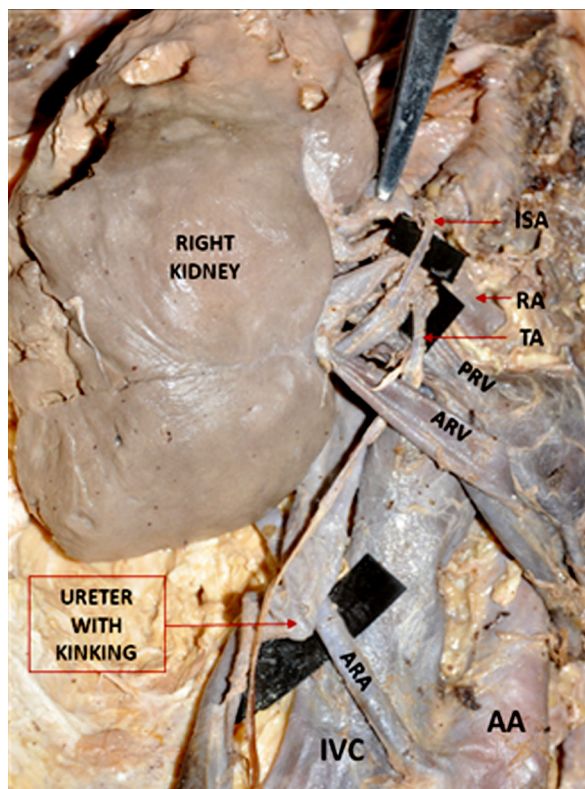


Figure 1: Right kidney with five pre-hilar branches of renal artery. RA: renal artery, ARA: accessory renal artery, ARV: anterior renal vein, PRV: posterior renal vein, kinking of ureter.

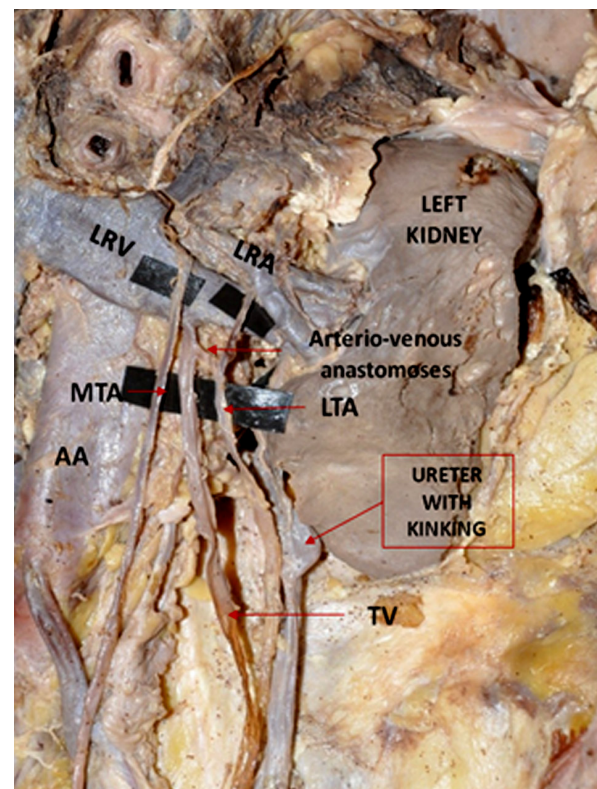


Figure 2: Left kidney with left renal artery (LRA), left renal vein (LRV), medial testicular artery (MTA), lateral testicular artery (LTA), and kinking of ureter.

old male cadaver would generate awareness regarding the presence of such variations among the medical fraternity, and surgical hazards due to unrecognised variation can be minimised.

Acknowledgement

None.

Conflicts of Interest

None.

Funds

None.

Authors' Contributions

Conception and design: ST

Analysis and interpretation of the data: RS

Drafting of the article: SM

Collection and assembly of data: MP

Correspondence

Dr Suresh Tadipi
MSc Medical, PhD (India)
Sri Devaraj Urs Medical College
Banglore Tirupathi Highway
Tamaka, Kolar
Karnataka 563101
India
Tel: +9109535958560
Email: sureshadipi@gmail.com

References

1. William PL, Bannister LH, Berry MM, Collins P, Dyson M, Dussek JE et al. *Cardiovascular system*. In: William PL, editor. *Gray's Anatomy* .38th ed. Edinburg (UK): Churchill Livingstone;1995:1547.
2. Dhar P, Lal K. Main and accessory renal arteries- a morphological study. *Ital J Anat Embryol*. 2005; **110**:101-110.
3. Graves FT. The aberrant renal artery. *J Anat*. 1956;**90**(4):553-558.
4. Nayak S. Presence of accessory renal artery and kinking of aorta due to the abnormal origin of renal arteries. *Internet J Biol Anthropology*. 2008;**1**(2):1-4.
5. Anson BJ. The cardiovascular system- arteries and veins in Morris human anatomy. 12th ed. New York (NY): The Blakiston Division, McGraw-Hill Book Company;1966.
6. Hollinshead WH. *Anatomy for surgeons*. Vol 2. New York (NY): Harper and Row; 1971. p. 579-580.
7. Bergman RA, Cassel MD, Sahinoglu K, Heidger PM. Human doubled renal and testicular arteries. *Ann Anat*. 1992;**174**(4):31-315.
8. Notkovich H. Variation of the testicular and ovarian arteries in relation to the renal pedicle. *Surg Gynecol Obstet*. 1956;**103**(4):487-495.
9. Bayramoglu A, Demiryurek D, Erbil KM. Bilateral additional renal arteries and an additional right renal vein associated with unrotated kidneys. *Saudi Med J*. 2003;**24**(5):535-537.
10. Merklin RJ, Michels NA. The variant renal and supra renal blood supply with data on the inferior phrenic, ureteral and gonadal arteries: a statistical analysis based on 185 dissections and review of the literature. *J Int Coll Surg*. 1958;**29**(1):41-76.
11. Pick JW, Anson BJ. The renal vascular pedicle. An anatomical study of 430 body halves. *J Urol*. 1940;**44**:411-434.
12. Satyapal KS, Rambiritch, PillaiG. Additional renal veins: incidence and morphometry. *Clin Anat*. 1995;**8**(1):51-55.
13. Felix W. Mesonephric arteries(aa.mesonephrica). In: Keibel F, Mall FP, editors. *Manual of Human Embryology*. Vol 22. Philadelphia (PA); Lippincott: 1912. p. 820-825.
14. Çiçekcibaşı AE, Salbacak A, Seker M, et al. The origin of gonadal arteries in human fetuses: anatomical variations. *Ann Anat*. 2002;**184**(3):275-279.
15. Deepthinath R, SatheeshaNayak B, Mehta RB, et al. Multiple variations in the paired arteries of the abdominal aorta. *Clin Anat*. 2006;**19**(6):566-568.
16. Rusu MC. Human bilateral doubled renal and testicular arteries with a left testicular arterial arch around the left renal vein. *Rom J Morphol Embryol*. 2006;**47**(2):197-200.