

Case Report

External Inflammatory Root Resorption in Mandibular First Molar: A Case Report

Meghanand T NAYAK¹, Anjali NAYAK²

Submitted: 30 Jun 2015
Accepted: 28 Jul 2015

¹ Department of Oral and Maxillofacial Pathology, Teerthanker Mahaveer Dental College and Research Centre, Teerthanker Mahaveer University, Moradabad

² Department of Oral Medicine and Radiology, Teerthanker Mahaveer Dental College and Research Centre, Teerthanker Mahaveer University, Moradabad

Abstract

External root resorption (ERR) is an irreversible loss of external tooth structure. Its etiology is multifactorial, but in many aspects remain unclear. Periapical inflammation sustained by infection can cause apical root resorption in permanent teeth. The infection may be asymptomatic for many years, although it is rarely misdiagnosed. Treatment of such lesions should include use of intracanal medicaments for complete debridement of the microbes. Here, we present a case of 21-year-old male patient who presented with external inflammatory root resorption.

Keywords: Root resorption, inflammatory, mandibular, molar

Introduction

Root resorption is defined by Ne et al. as “a condition associated with either a physiologic or a pathologic process resulting in the loss of dentin, cementum or bone” (1). Root resorption is classified into two types – internal and external resorption (2). External root resorption (ERR) may be physiological or pathological. Physiological root resorption is a process encountered during the exfoliation of primary dentition. ERR of permanent teeth is a multifactorial process and usually has a pathologic basis (2,3). From a clinical and applied perspective, ERR may be divided into three categories: 1) progressive inflammatory resorption; 2) cervical resorption; and 3) replacement resorption (4).

Case Report

An Indian male in his early twenties reported to the out-patient department with pain in the lower right back region of his mouth, which he had for two months. The pain was continuous and throbbing in nature. The pain was aggravated by hot food and was relieved by cold water.

On examination, a silver amalgam restoration of the permanent mandibular right first molar (FDI #46) was noticed, which was tender on percussion (Figure 1). On pulp vitality testing, an exaggerated pain response was produced and a provisional diagnosis of irreversible pulpitis was

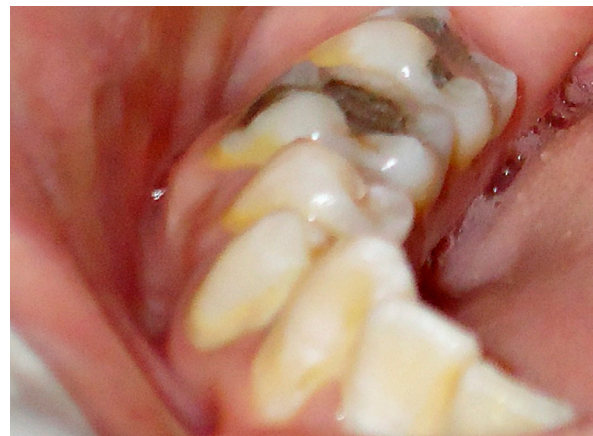

Figure 1: Intraoral photograph of silver amalgam filling i.r.t #46, 47.

made. The periodontal sulcus was probed using a standard periodontal probe. A probing depth of 2 mm – 4 mm was recorded, and the clinical attachment of the gingiva was considered to be normal. There was no swelling, discharge or sinus opening in relation to (i.r.t) #46. The patient was otherwise healthy and his medical history was non-contributory.

Intra oral periapical radiograph (IOPAR) of the mandibular right posterior region revealed a radiopaque restoration on the occlusal surface of #46 & #47 (Figure 2). The restoration was seen close to the distal pulp horn in #46. The shortening

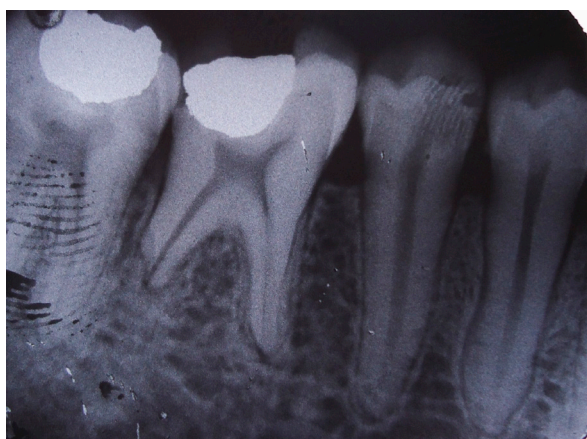


Figure 2: Pre-treatment intraoral periapical radiograph showing external root resorption of the distal root of #46.

of the distal root of #46 was also noted. Ragged and concave areas were seen in the margin of the distal root of #46. Altered trabecular pattern was seen around the periapical region of the distal root of #46. Loss of lamina dura was noticed i.r.t the apical third of the distal root. Widening of periodontal space and loss of lamina dura was detected i.r.t the mesial root of #46. Fingerprint artifact was also noted. A radiological diagnosis of external root resorption i.r.t #46 was made. A final diagnosis of acute apical periodontitis along with external inflammatory resorption i.r.t the distal root #46 was made.

A differential diagnosis of a short root anomaly and periapical abscess i.r.t #46 was also considered. However, the short root anomaly was ruled out as it is a developmental anomaly with generalized short, blunt roots. Periapical abscess refers to the localized accumulation of pus in the apical regions of the tooth and is secondary to pulpal pathoses.

Nonsurgical root canal therapy was conducted following the administration of antibiotics (amoxicillin 50 mg/kg body weight) to control infection and analgesics to relieve pain. A good prognosis for the case was documented. An uneventful healing was recorded and the initial symptom of pain was comforted. The patient was followed up for two years and the follow-up radiographs showed complete healing of the periapical area with bone formation. No further root resorption was noticed.

Discussion

Resorption of the mineralized structures of the teeth is carried out by the multinucleated cells called odontoclasts. The speed of progression can vary and the resorption can occur in different periods (5). The possible etiology of ERR can be periapical inflammation, acute trauma, tumours and cysts, chronic trauma, impaction, and idiopathic elements (6). As suggested by Fuss et al., the etiopathogenesis of different types of root resorption occurs in two phases. During phase 1, mechanical or chemical injury to the protective tissues occurs; in phase 2, stimulation by infection or pressure occurs (7). An infectious inflammation is associated with the production and release of the macrophage-chemotactic factor, osteoclast-activating factor, and prostaglandins, which are known stimulators of hard tissue resorption (4).

The classification of tooth resorption is confusing as different terms are used to describe the same processes. According to the stimulation factors, root resorption can be due to pulpal infection, periodontal infection, orthodontic pressure, impacted tooth or tumour pressure, or ankylosis (7).

In general, injury or irritation to the periodontium initiates an inflammatory response within the periodontal ligament and leads to resorption (1). It is noted that use of pulp-capping agents with antimicrobial activity is required under permanent restoration, as microorganisms remain in dentin even after cavity preparation and may induce pulp damage (8).

Non-surgical endodontic therapy involves the removal of inflamed, infected or necrosed pulp tissue through an access opening prepared through the crown of the tooth. The tooth is cleaned through copious irrigation and disinfected using intracanal medicaments. The tooth is finally shaped to receive sterile filling material to prevent reinfection.

Heithersay GS (1994), suggests that few resorptions are self-limiting, while some resorptions, such as inflammatory root resorption, require active and prompt endodontic preparation and medication to control odontoclastic activity (9).

External inflammatory root resorption (EIRR) is considered a major resorptive condition without symptoms (10). Depending on location, EIRR can be classified as cervical and apical. Cervical EIRR is mainly associated with tooth trauma, bruxism, surgical or orthodontic treatment, and periodontal root planing

and scaling, while apical EIRR is related to luxation types of traumatic injury, periradicular periodontitis and orthodontic treatment.

Seltzer and Bender (1975), claimed that the presence of resorption is usually indicative of irritation of the area caused by chronically inflamed or necrotic pulp (11). It is noted that all teeth with apical periodontitis will exhibit apical resorption. The inflammatory response can be exacerbated in the presence of bacteria and bacterial byproducts inside the root canal system, and in dental tubules after pulp necrosis, and in the absence of protection of cementum barrier (12). Endodontic treatment should be initiated promptly to prevent further hard tissue loss and root perforation (13).

The treatment of EIRR depends on its etiology. Orthodontic treatment induced ERR is arrested with removal of the pressure of the orthodontic treatment. Infection induced or infection sustained tooth resorption requires the removal of the micro-organisms by endodontic therapy including intra-canal medication, which can also facilitate repair of the resorbed tooth structure (9).

Conclusion

Improper restoration may induce pulpal damage and thus root resorption. External root resorption can occur as a result of various etiologies and the prognosis of the affected tooth is usually poor. Early detection and identifying the etiology of root resorption is required for proper management and better prognosis.

Acknowledgement

None.

Conflict of Interest

None.

Funds

None.

Authors Contributions

Conception and design, analysis and interpretation of the data, drafting of the article, final approval of the article: AS, MTN

Provision of study materials or patient, obtaining of funding, collection and assembly of data: MTN

Correspondence

Dr Meghanand Nayak
BDS (Bangalore University), MDS (RGUHS, Bangalore)
Department of Oral and Maxillofacial Pathology
Teerthanker Mahaveer University/Teerthanker
Mahaveer Dental
College and Research Centre, Delhi Road
Moradabad-244001, Uttar Pradesh
India
Tel: +91591 247 6823
Email: drmeghanand@gmail.com

References

1. Ne RF, Witherspoon DE, Gutmann JL. Tooth resorption. *Quintessence Int.* 1999;**30(1)**:9–25.
2. Bolhari B, Meraji N, Nosrat A. Extensive idiopathic external root resorption in first maxillary molar: a case report. *Iran Endod J.* 2013;**8(2)**:72–74.
3. Bakland LK. Root resorption. *Dent Clin North Am.* 1992;**36(2)**:491–507.
4. Tronstad L. Root resorption-etiology, terminology, and clinical manifestations. *Endod Dent Traumatol.* 1988;**4(6)**:241–252.
5. Mohan RPS, Verma S, Singh U, Agarwal N. Internal resorption. *BMJ Case Rep.* 2013;**2013**: pii: bcr2013008665. doi: 10.1136/bcr-2013-008665.
6. Tamse A, Littner MM, Kaffe I. Roentgenographic features of external root resorption in the permanent dentition. *Quintessence Int Dent Dig.* 1982;**13(1)**:51–54.
7. Fuss Z, Tsesis I, Lin S. Root resorption--diagnosis, classification and treatment choices based on stimulation factors. *Dent Traumatol.* 2003;**19(4)**:175–182. doi: 10.1034/j.1600-9657.2003.00192.x.
8. Neelakantan P, Rao CV, Indramohan J. Bacteriology of deep carious lesions underneath amalgam restorations with different pulp-capping materials--an in vivo analysis. *J Appl Oral Sci.* 2012;**20(2)**:139–145. doi: 10.1590/S1678-77572012000200003.
9. Heithersay GS. External root resorption. *Ann R Australas Coll Dent Surg.* 1994;**12**:46–59.
10. Trope M. Root resorption of dental and traumatic origin: Classification based on etiology. *Pract Periodont Aesthet Dent.* 1998;**10(4)**:515–522.

11. Seltzer S, Bender. The Dental Pulp. 2nd ed. Philadelphia and Toronto (CAN): JB Lippincott Co; 1975. p. 236.
12. Utneja S, Garg G, Arora S, Talwar S. Nonsurgical endodontic retreatment of advanced inflammatory external root resorption using mineral trioxide aggregate obturation. *Case Rep Dent.* 2012;**2012**:624792. doi: 10.1155/2012/624792.
13. Guzeler I, Uysal S, Cehreli ZC. Treatment of severe inflammatory root resorption in a young permanent incisor with mineral trioxide aggregate. *J Can Dent Assoc.* 2011;**77**:b108.