

A Case of Amelanotic Malignant Melanoma of the Maxillary Sinus Presented with Intraoral Extension

Abhishek SINGHVI¹, Ashish JOSHI²

Submitted: 18 Sep 2014

Accepted: 25 Dec 2014

¹ Department of Oral and Maxillofacial Pathology, Vyas Dental College and Hospital, Kudi Haud, Pali Road, Jodhpur PIN 342008, Rajasthan, India

² Post graduate student, Department of Oral and Maxillofacial Pathology, Vyas Dental College and Hospital, Kudi Haud, Pali Road, Jodhpur PIN 342008, Rajasthan, India

Abstract

Melanoma of the sinonasal cavity has a high incidence of amelanotic presentation. Its diagnosis is difficult for clinicians and pathologists because of its hidden location and lack of pigmentation at the microscopic level. We reported a case of amelanotic melanoma of the maxillary sinus that showed aggressive extension to the oral cavity after extraction of the maxillary tooth. Histologically, the lesion resembled a plasmacytoid tumour. Diagnosis was made through the positive immunohistochemical staining for S100 and HMB-45.

Keywords: maxillary sinus, amelanotic melanoma, oral cavity, immunohistochemistry

Introduction

Amelanotic melanoma (AM) is a malignant tumor of the skin and mucous membrane in which the tumor cells fail to produce melanin (1). This variant of melanoma with aggressive behaviour may involve the nasal cavity and paranasal sinuses (2). Microscopic diagnoses of these tumours are difficult as they may reveal variable histological patterns and the absence of melanin pigmentation. Immunohistochemistry (IHC) is an essential ancillary technique in the diagnosis of AM. S-100 and HMB-45 are sensitive immunohistochemical markers that confirm diagnosis (1,2). Our case of mucosal AM, centred in the maxillary sinus, extended to the nasal and oral cavities.

Case Report

A 72-year-old male patient presented with the chief complaint of swelling over the left cheek at duration of five months. He also had pain in the same region in the last six months, followed by a one-month history of decreased vision of the left eye. The patient was evaluated by a dentist one month previously for pain in the left upper tooth. Extraction of the tooth was conducted, following which the patient started noticing a progressively increasing mass associated with

pain at the extraction site. The patient underwent an incisional biopsy procedure and was found to have poorly differentiated squamous cell carcinoma. Afterwards, the patient was referred to us for further evaluation.

Clinical examination of the patient's face revealed facial asymmetry, narrowing of the palpebral aperture of the left eye, and erythematous bulbar conjunctiva. Moreover, finger counting was not possible beyond a 3 feet distance. A hard, fixed irregular mass measuring approximately 8 x 6 cm was found in the left maxillary region that was not tender. Intraoral examination showed two separate masses palpated on the entire left hard palate and left vestibule. Both masses had smooth surfaces and firm consistency, and were pink to red in colour (Figure 1). They appeared to protrude from the left maxillary antrum. No clinically palpable lymphadenopathy was identified upon neck examination. The impression of carcinoma of the left maxilla was made upon clinical examination.

Radiological examinations were conducted to rule out any metastatic disease in the lungs and to determine the extent of the lesion. Chest radiograph revealed no metastatic disease in the lungs. Using a Philips Magnetometer 1.5 Tesla system, contrast enhanced magnetic resonance imaging (MRI) of the head and neck was performed. A large invasive left sinonasal mass, measuring 7.2 x 4.2 x 4.7, centred in the left

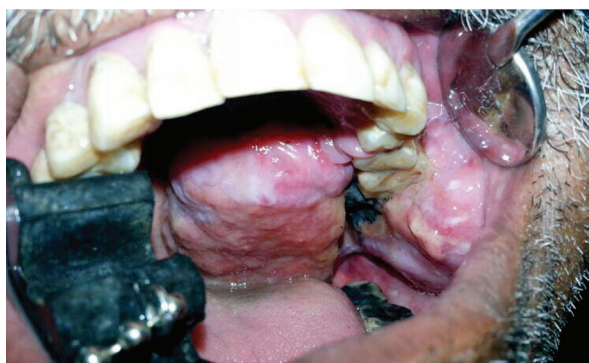

Figure 1: Intraoral examination revealed two large masses on the left hard palate and on the left buccal vestibule.

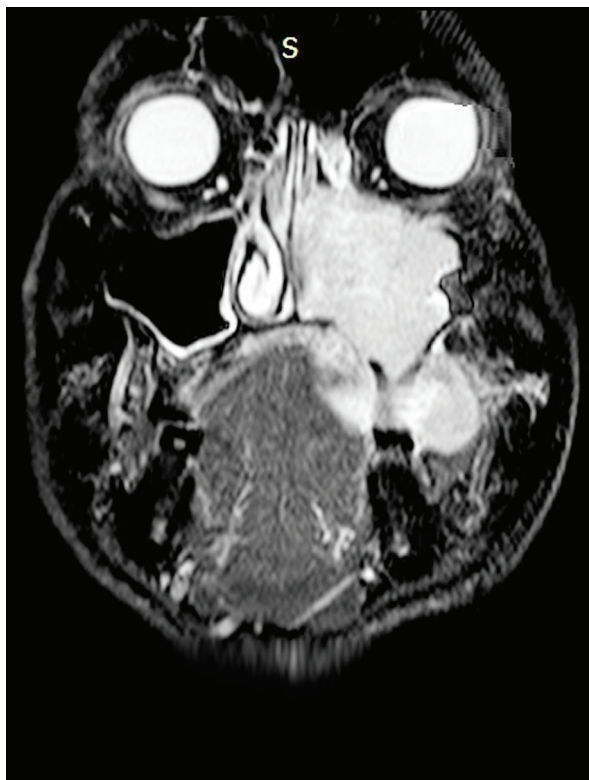

Figure 2: Axial MRI of the lesion showing a large invasive sinonasal mass centred in the left maxillary antrum.

maxillary antrum was found to cause prominent osseous destruction. A massive inferior extension of the tumor was determined through the destruction of the floor of the maxillary antrum and left hard palate. Compression of the left posterior tongue from above, with tumor infiltration of the left buccal space, was observed. Medially, no tumoural extension across the midline to the right side was found. Superiorly, scalloping of the floor of the left orbital, without direct intraorbital tumor invasion, was observed (Figure 2). No metastatic lymph nodes were identified in the imaging. Radiological differential diagnoses were squamous cell carcinoma, adenoid cystic carcinoma, mucoepidermoid carcinoma, or undifferentiated malignant lesion of the left maxillary sinus.

An incisional biopsy of the lesion was performed, and the specimen was referred for histopathological evaluation. The microscopic examination showed cells that were round and plasmacytoid with a fibrillary background along with sparsely arranged myxomatous stroma in several places. These cells showed a high frequency of mitotic activity (Figure 3). Blood vessels showed perivascular hyalinisation and endothelial proliferation. These microscopic features presented the impression of a malignant round cell tumor. To confirm these tumour cells, we performed IHC with Pan cytokeratin, vimentin, S-100, HMB-45, desmin, and myogenin. IHC examinations revealed that the tumor cells showed strong staining for S-100 and HMB-45 (Figure 4). These results indicated that the lesion was amelanotic malignant melanoma.

Surgical innervations were not suggested as the lesion involved a large intracranial region and showed proximity to other vital structures. Radiotherapy was planned for the patient. Unfortunately, the patient did not respond to the radiotherapy and did not survive after one month of initiation of therapy.

Discussion

Mucosal melanoma of the head and neck (MMHN) region is uncommon and constitutes only 1% of all melanomas. MMHN commonly involves the nasal cavity, sinonasal complexes, and oral cavity. These tumours are associated with aging and commonly occur in the sixth to eighth decades of life (3,4). The incidence of amelanotic presentation (20%–25%) is higher than that of cutaneous melanoma (1.8–8.1%) in the mucous membrane (5). Amelanotic mucosal melanoma

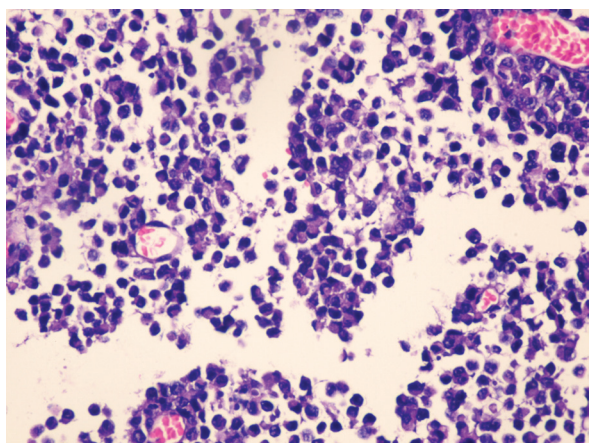


Figure 3: Section showing the sheets of round plasmacytoid cells with mitotic activity. (Hematoxylin and eosin stain; 400× magnification).

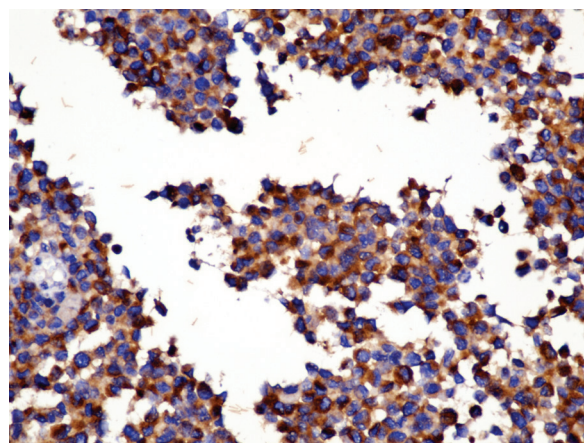


Figure 4: Tumor cells showing positive immunohistochemical staining for HMB-45, (HMB-45; 100× magnification)

has nonspecific symptoms. Its hidden localisation in the majority of cases often leads to delay in diagnosis (4). The reported patient was initially evaluated by a dentist, who failed to identify the cause of pain in the maxillary tooth region.

The etiological factors responsible for MMHN are clearly not identified. Several researchers postulated that tobacco smoke and occupational exposure to formaldehyde have a potential role in the development of these lesions (6,7). All melanocytes have the same embryologic origin despite the different microenvironments, and thus differences exist in the adhesion molecule or signal pathway required for their growth and development. As different melanomas carry different genetic mutations, distinct biological entities exist with different clinical features. Cutaneous melanoma shows mutation in the BRAF gene unlike mucosal melanoma, which shows V-kit Hardy-Zuckerman 4 feline sarcoma viral oncogene homolog (KIT) mutation (7). The present case history revealed no habits of chewing tobacco, smoking, and alcohol and opioid intake. The patient was not exposed to formaldehyde.

Mucosal melanoma represents a different clinical course and is more aggressive than cutaneous melanoma. Melanomas of the maxillary sinus may be associated with pain and extension to several subsites, such as the nasal cavity, orbital invasion, and skull base (8). This case exhibited extensive destruction of the floor of the orbital and nasal cavities. The lesion showed a massive

expansion to the oral cavity through the oroantral route, which was a unique presentation for a maxillary sinus melanoma, after the extraction of a maxillary tooth.

Histologically, AM is difficult to diagnose because it may show several subtypes of tumor cells, such as epithelioid, spindle, pleomorphic, round, and plasmacytoid cell variants. The lack of melanin pigmentation at the microscopic level makes the diagnosis even more complicated. These lesions are similar to undifferentiated carcinoma or sarcoma. Such lesions require further and thorough IHC investigations for the identification of tumor cells. Mucosal melanomas show negative staining for cytokeratin, but S-100 and HMB-45 are strongly positive in the absence of melanin pigmentation (1,2,9). The histological features of this case revealed the plasmacytoid pattern of the tumor, which is considered a rare variant. These cells showed strong staining for S-100 and HMB-45.

The management of sinonasal melanoma is uncertain because of delayed diagnosis and paucity of reported cases. Complete surgical excision with wide margins is the conventional strategy for treatment. Other adjuvant techniques, such as radiotherapy, chemotherapy, and immunotherapy have not been well established. Several authors observed that post-operative radiotherapy increased the survival rate for a period of four to five years in sinonasal melanomas (10). In the present case, as the patient was in an enervating

state and the disease was in its advanced stage, radiotherapy should have been the preferred mode of treatment instead of surgery. The prognosis was so poor that it seemed indefensible to emphasise the massive removal of the tumor.

In clinical practice, the clinician may encounter rare tumours with unusual presentation. Such cases require special attention for prompt diagnosis and management. These lesions should be examined thoroughly, and all possible diagnostic techniques should be considered for final diagnosis so that we can gain better understanding.

Conflict of Interest

None

Acknowledgement

None

Funds

None

Authors' Contributions

Drafting of the article: AS, AJ

Conception and design, critical revision of the article for the important intellectual content, final approval of the article: AS

Provision of study materials or patient, administrative, technical or logistic support, collection and assembly of data: AJ

Correspondence

Dr Abhishek Singhvi
MDS (Rajasthan University of Health Sciences)
Department of Oral and Maxillofacial Pathology
Vyas Dental College and Hospital Kudi Haud
Pali Road
Jodhpur PIN 342008
Rajasthan, India
Tel: +91 946164 5441
Fax: +0291-272 0784
Email: me.singhvi@yahoo.co.in

References

1. Nothani K, Shindoh M, Yamazaki Y, Nakamura H, Watanabe M, Kogoh T et al. Amelanotic Malignant Melanomas of Oral Mucosa. *Br J Oral Maxillofac Surg.* 2002;**40(3)**:195–200.
2. Gupta S, Pant MC, Husain N, Sundar S, Khan H. Primary Amelanotic Melanoma of the Nasal Cavity: A Case Report. *Ear Nose Throat J.* 2014;**93(1)**:E12–4.
3. Marcus DM, Marcus RP, Prabhu RS, Owonikoko TK, Lawson DH, Switchenko J et al. Rising Incidence of Mucosal Melanoma of the Head and Neck in the United States. *J Skin Cancer.* 2012;**2012**:231693. doi: 10.1155/2012/231693.
4. Baderca F, Vincze D, Balica N, Solovan C. Mucosa Melanomas in The Elderly: Challenging Cases and Review of the Literature. *Clin Interv Aging.* 2014;**9**:929-937. doi: 10.2147/CIA.S64361.
5. Seetharamu N, Ott PA, Pavlick AC. Mucosal Melanomas: A Case-Based Review of the literature. *Oncologist.* 2010;**15(7)**:772–781. doi: 10.1634/theoncologist.2010-0067.
6. Benevenuto de Andrade BA, Pina AR, Leon JE, Paes de Almeida O, Altemani A. Primary Nasal Mucosal Melanoma in Brazil: Clinicopathologic and Immunohistochemical Study of 12 Patients. *Ann Diagn Pathol.* 2012;**16(5)**:344–349. doi: 10.1016/anndiagpath.2012.02.001.
7. Mihajlovic M, Vlajkovic S, Jovanovic P, Stefanovic V. Primary Mucosal Melanomas: A Comprehensive Review. *Int J Clin Exp Pathol.* 2012;**5(8)**:739–753.
8. Norhafizah M, Mustafa WM, Sabariah AR, Shiran MS, Pathmanathan R. Mucosal Malignant Melanoma of the Maxillary Sinus. *Med J Malaysia.* 2010;**65(3)**:218–220.
9. Bothale KA, Maimoon SA, Patrikar AD, Mahore SD. Mucosal malignant melanoma of the nasal cavity. *Indian J Cancer.* 2009;**46(1)**:67–70. doi: 10.4103/0019-509X.48600.
10. Kim HS, Kim EK, Jun HJ, Oh SY, Park KW, Lim do H et al. Noncutaneous Malignant Melanoma: A Prognostic Model from a Retrospective Multicenter Study. *BMC Cancer.* 2010;**28(10)**:167. doi: 10.1186/1471-2407-10-167.