

## Peri-orbital electrodes as a supplemental recording for detection of ictal discharges in medial temporal lobe epilepsy

<sup>1</sup>Hiroshi Shigeto MD PhD, <sup>2</sup>Ayumi Sakata, <sup>3,4</sup>Takato Morioka MD PhD, <sup>1</sup>Kei-ichiro Takase MD PhD, <sup>1</sup>Ko-ichi Hagiwara MD PhD, <sup>1</sup>Takashi Kamada MD, <sup>1</sup>Yuji Kanamori MD, <sup>3</sup>Kimiaki Hashiguchi MD PhD, <sup>5</sup>Shozo Tobimatsu MD PhD, <sup>6</sup>Natsumi Yamashita, <sup>1</sup>Jun-ichi Kira MD PhD

Departments of <sup>1</sup>Neurology, <sup>3</sup>Neurosurgery, and <sup>5</sup>Neurophysiology, Neurological Institute, Graduate School of Medical Sciences, Kyushu University; <sup>2</sup>Division of Clinical Chemistry and Laboratory Medicine, Kyushu University Hospital; <sup>4</sup>Department of Neurosurgery, Kyushu-Rosai Hospital; <sup>6</sup>Department of Medical Informatics, Kyushu University Hospital, Japan

### Abstract

**Objective:** The feasibility of peri-orbital electrodes, which are not invasive and do not induce pain, as a supplemental electrode for detection of ictal discharges in medial temporal lobe epilepsy (MTLE) was examined. **Methods:** Patients with MTLE, who underwent video-EEG monitoring with simultaneous peri-orbital and sphenoidal electrodes and obtained good outcome following standard anterior temporal lobectomy, were subjects in this study. Initial ictal discharge amplitudes were compared between sphenoidal (Sp1/2), standard anterior temporal in 10-20 system (F7/8), peri-orbital (superior orbital lateral: SOL, inferior orbital medial: IOM), frontopolar (Fp1/2), frontal (F3/4) and ear (A1/2) electrodes. **Results:** A total of 34 consecutive seizures from 20 patients were analyzed, with a maximum amplitude observed at Sp1/2 (57.57±5.59), followed by F7/8 (54.89±5.59), SOL (50.97±5.59), IOM (46.95±5.59), A1/2 (45.07±5.69), Fp1/2 (44.78±5.62), and F3/4 (37.75±5.66) (mean±standard error,  $\mu$ V). There was no statistical difference between Sp1/2, F7/8, SOL, and IOM values. When the sphenoidal electrode was omitted, 13 seizures (13/34, 38.2%) resulted in the highest amplitude at peri-orbital electrodes and 10 seizures (10/34, 29.4%) at F7/8.

**Conclusions:** Peri-orbital electrodes could detect ictal discharges in MTLE as well as sphenoidal and standard anterior temporal electrodes in 10-20 system and are useful for supplemental recording for detecting ictal epileptiform discharges in MTLE.

### INTRODUCTION

The medial temporal lobe is a key structure involved in seizure activity. However, detection of electrical activities in the medial temporal lobe when the electrode is situated on the scalp is extremely difficult, because the electrical activities are located deep inside the skull and the surrounding bones distort the electrical activity conduction. To overcome this, a sphenoidal (Sp) electrode technique has been developed and is widely used to monitor seizures.<sup>1,2</sup> The Sp electrode is inserted beneath the zygomatic arch, and the electrode tip is usually placed at an antero-ventral position within the basal temporal region. However, it remains unclear whether Sp electrodes detect electrical activity in the medial temporal lobe.<sup>3-5</sup> In addition, it is often accompanied by pain. Therefore, several electrode placements

have been analyzed as substitutes for the Sp electrode, e.g., nasopharyngeal electrodes<sup>6,7</sup>, subdermal sphenoidal electrodes<sup>8</sup>, additional closely spaced anterior temporal electrodes<sup>9-11</sup>, and cheek electrodes.<sup>12</sup> These alternative methods significantly improve detection of epileptic foci compared to the use of 10-20 electrodes. However, the results are not superior to the Sp electrodes.<sup>1,2,12,13</sup>

Incidentally, recordings from the peri-orbital electrodes, which were initially positioned to detect eye movements, also detected seizure activities in temporal lobe epilepsy patients. The present study examined the feasibility of peri-orbital electrodes for the detection of ictal epileptiform discharges in medial temporal lobe epilepsy (MTLE). In addition, these results were compared with Sp electrode detection results.

## METHODS

Patients with MTLE, who underwent video-EEG monitoring with simultaneous peri-orbital electrodes and Sp electrodes during November 1996 to June 2002, were enrolled in the present study. MTLE diagnosis was made based on semiology, electroencephalographic recordings, and neuroimaging. Only patients who obtained a good outcome (Engel class 1 and 2) following standard anterior temporal lobectomy were included in the study. Encephalographic seizure activities were analyzed retrospectively.

Sp electrodes were composed of twisted stainless steel, which was 0.2 mm in diameter and isolated, except 1 mm at the tip (Unique Medical, Tokyo, Japan). Sp electrodes were blindly inserted immediately inferior to the zygomatic arch and bone intersection, approximately 4-5 cm deep. The electrode tip position was confirmed by X-ray and was corrected if necessary. Conventional Ag-CI-Ag electrodes were used for peri-orbital recordings, which were placed above the upper lateral (superior orbital lateral: SOL) and lower medial (inferior orbital medial: IOM) position of the orbital fossa (Figure 1). Impedance was maintained below 5 kOhm. EEG data were digitally acquired at a sampling rate of 1 kHz (Neurofax, Nihon Koden, Tokyo, Japan). High-

frequency data > 30 Hz were digitally filtered with a time constant of 0.1 s. Seizure electrical activity onsets were visually identified by two experienced electroencephalographers (HS and AS). The amplitude from peak to baseline of the initial three peaks of rhythmic seizure activities was measured using a digital scaling system (Nihon Koden), and the average of three amplitudes was compared between Sp electrodes (Sp1/2), peri-orbital electrodes (SOL and IOM), standard anterior temporal electrodes in 10-20 system (F7/8), frontopolar electrodes (Fp1/2), frontal electrodes (F3/4), and ear electrodes (A1/2). A Pz electrode was used as the reference electrode for amplitude measurement. The mean and standard error were estimated using a linear mixed effect model with seizures as the random effect and electrodes as the fixed effect. This model was considered intra-seizure amplitude dependent, by including a random effect in the model. The difference in mean of amplitude was tested between all pairs and was adjusted using the Tukey-Kramer method for multiple comparison.

## RESULTS

Interictal spikes exhibited maximum amplitude at the anterior temporal region. Among 20 patients,

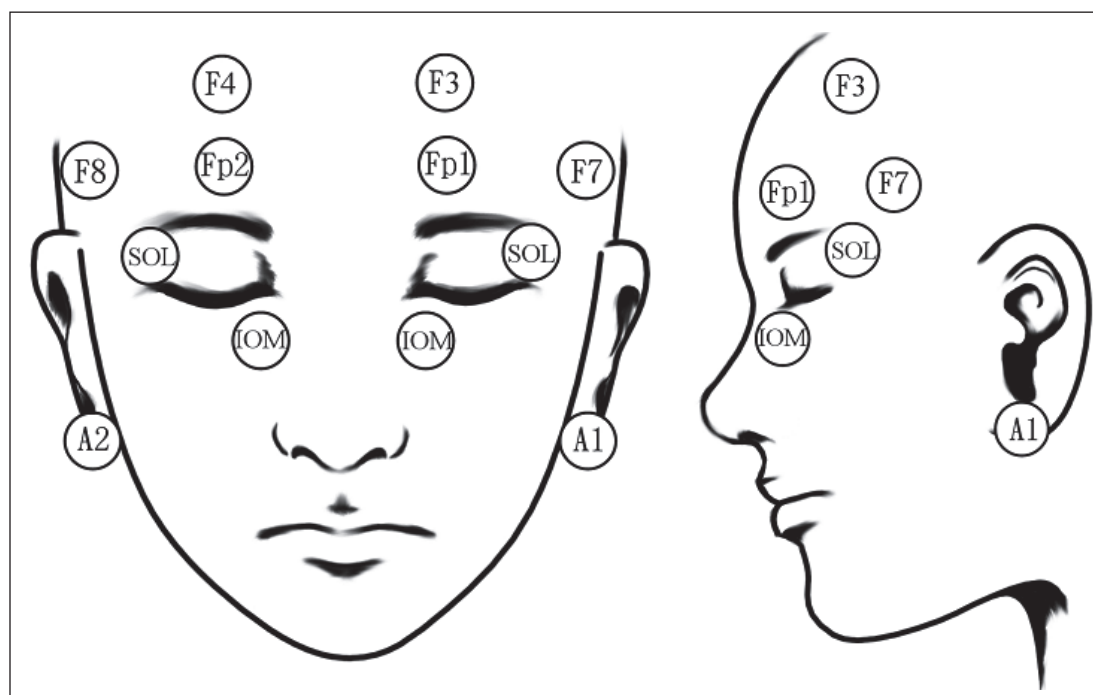


Figure 1: A schema of peri-orbital electrodes.

IOM represents inferior orbital medial electrodes; SOL is superior orbital lateral electrodes.

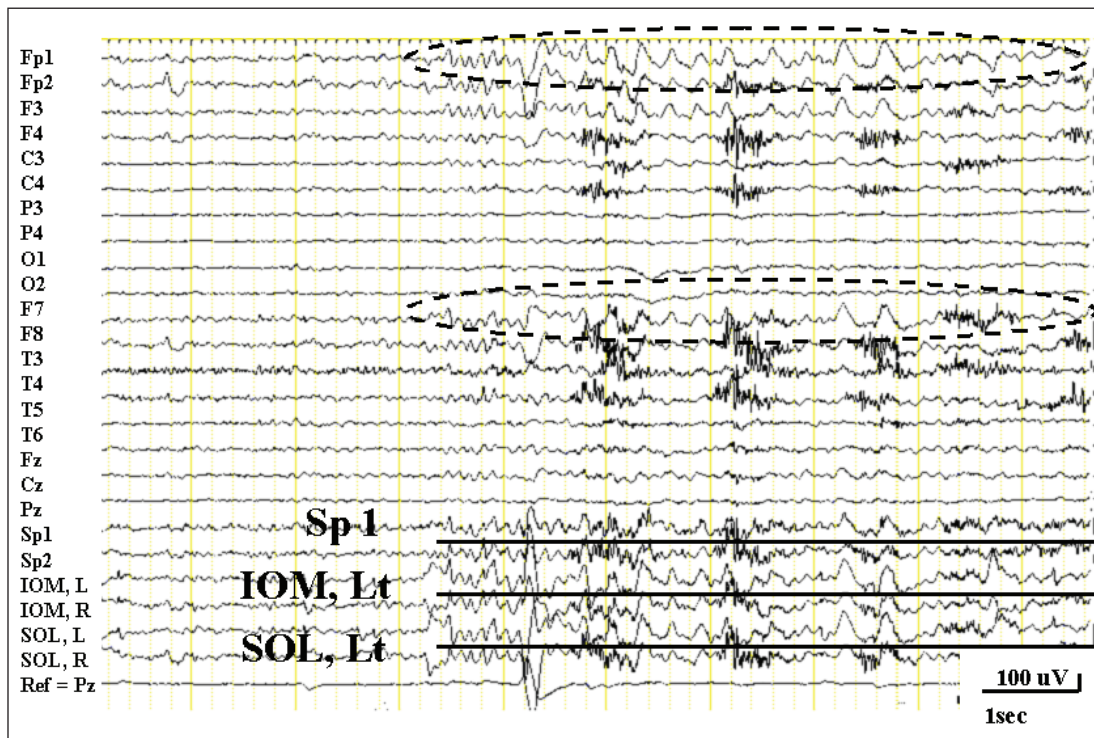


Figure 2: Simultaneous EEG recording from scalp, sphenoidal, and peri-orbital electrodes. Ictal activities from peri-orbital electrodes exhibit greater amplitude than sphenoidal electrodes. Similar rhythmic ictal discharges are observed at the frontopolar and anterior temporal region with left lateralized distribution (dotted oval). All electrodes are referred to an electrode at Pz.

9 patients had maximum amplitude at Sp1/2, 7 patients at F7/8, 2 patients at SOL, 1 patient at left IOM, and 1 patient at Fp1.

A total of 34 consecutive seizures from 20 patients were analyzed. The greatest amplitude was observed at Sp1/2 ( $57.57 \pm 5.59$ ), followed by F7/8 ( $54.89 \pm 5.59$ ; 0.996), SOL ( $50.97 \pm 5.59$ ; 0.741), IOM ( $46.95 \pm 5.59$ ; 0.194), A1/2 ( $45.07 \pm 5.69$ ; 0.084), Fp1/2 ( $44.78 \pm 5.62$ ; 0.063), and F3/4 ( $37.75 \pm 5.66$ ; 0.0003) (mean  $\pm$  standard error,  $\mu$ V; *P*-value following adjustment). There was no statistical difference between Sp1/2, F7/8, SOL, and IOM (Figures. 2 and 3). In 20 seizures, the maximum highest amplitude was observed at

Sp1/2. In the remaining 14 seizures, 6 were at F7/8, 4 were at Fp1/2, 2 were at SOL, 1 was at IOM and 1 was at A1/2 electrodes. Of the 20 seizures that peaked at the sphenoidal electrode, the second highest amplitude was observed at IOM in 6 seizures, followed by SOL in 4 seizures, F7/8 in 4 seizures, A1/2 in 3 seizures, F3/4 in 2 seizures, and Fp1/2 in 1 seizure (Table 1). When the sphenoidal electrode was omitted, 13 seizures resulted in the highest amplitude at peri-orbital electrodes (6 at SOL and 7 at IOM, total 13 out of 34, 38.2%) and 10 seizures (10/ 34, 29.4%) at F7/8 (Table 1).

**Table 1: Comparison of electrodes for seizure detection rate**

	Sp1/2	F7/8	SOL R/L	IOM R/L	Fp1/2	F3/ 4	A1/ 2	Total
Max	20	6	2	1	4	0	1	34
Max next to Sp	—	4	4	6	1	2	3	20
Max excluding Sp	—	10	6	7	5	2	4	34

Max; the number of seizures with the highest amplitude at seizure onset. Max next to Sp; the number of seizures with the second highest amplitude next to the sphenoidal electrode. Max excluding Sp; the number of seizures with the highest amplitude when the sphenoidal recording was excluded.

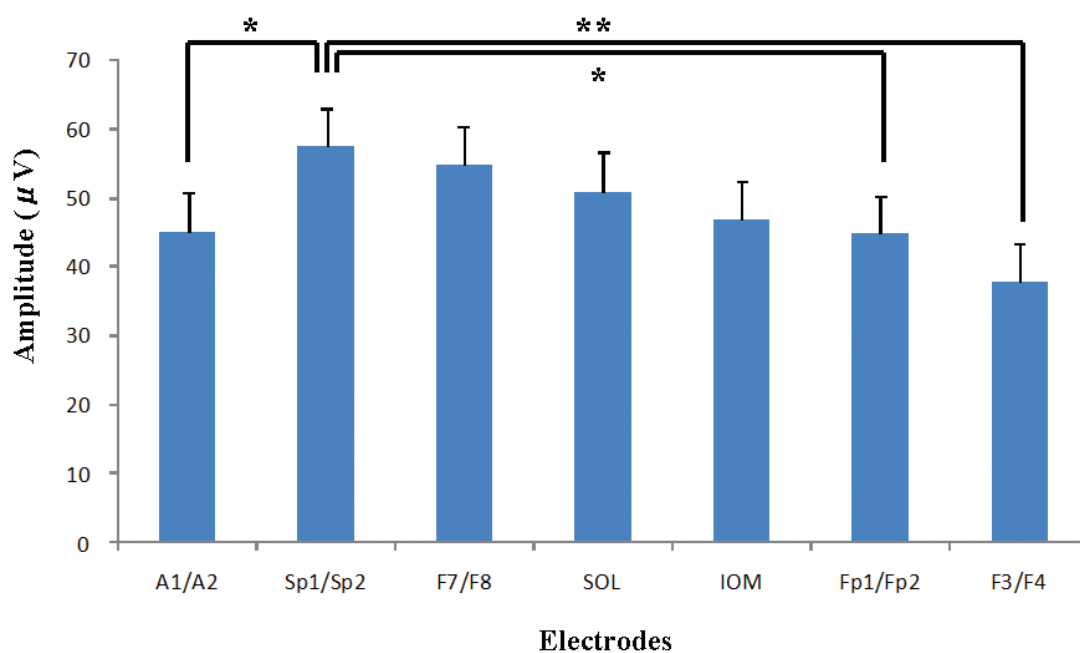


Figure 3: Mean amplitude and standard error of sphenoidal (Sp1/ Sp2), peri-orbital (SOL and IOM), anterior temporal (F7/ F8), frontal (F3/ F4), frontopolar (Fp1/ Fp2), and ear electrodes (A1/ A2).

Mean amplitude of sphenoidal electrode is greatest. There is no statistical difference between Sp1/2, F7/8, SOL, and IOM (\*:  $P < 0.1$ , \*\*:  $P < 0.05$ ).

Sp: sphenoidal electrode; SOL: superior orbital lateral electrode; IOM: inferior orbital medial electrode

## DISCUSSION

Sp electrodes mainly detect electrical activity in the basal temporal lobes and possibly in the posterior portion of orbital frontal lobes.<sup>14</sup> However, Sp electrodes do not necessarily distinguish between spikes originating from antero-medial temporal areas or antero-lateral temporal areas.<sup>1,4,12,15</sup> Even though seizure semiology, electroencephalographic recordings and neuroimaging suggested that these patients had medial temporal lobe epilepsy, the precise epileptogenic region might not have been the same and subtle field differences may have occurred. Therefore, to ensure that the patients were as homogeneous as possible, we selected patients with a good outcome after standard anterior temporal lobectomy. These patients had possible ictal discharges that arose primarily from medial temporal lobe structures.

Simultaneous recordings from sphenoidal and additional closely spaced anterior temporal electrodes were not performed, because the study was retrospective and sphenoid electrodes were already in place in all cases. Therefore, peri-orbital, conventional, and sphenoidal electrodes were compared. It is interesting that the second

largest initial ictal discharge amplitude was observed most frequently at the peri-orbital electrode in seizures, which peaked at the Sp electrode (4 at SOL and 6 at IOM, total 10 out of 20 seizures). This might suggest that distributions of epileptic discharge with maximum amplitude at sphenoidal electrode are similar to maximum amplitude at peri-orbital electrodes. Sparkes *et al.* reported that interictal anterior temporal epileptiform discharges were conducted to the outer canthus and inferior orbital electrodes *via* the skull foramen and exhibited amplitude similar to anterior temporal electrodes.<sup>16</sup> This same mechanism may take place in the present ictal discharge recordings. In addition, the greatest amplitude was observed more frequently at peri-orbital electrodes than standard anterior temporal electrodes in 10-20 system. These results suggested that peri-orbital electrodes should be considered for increasing the detection rate of ictal discharges from medial temporal structures.

However, eye movement may disturb peri-orbital electrode recording, recordings from peri-orbital electrodes are rarely obscured by muscle activities, unlike other anterior temporal surface electrodes, and are easily replaced if contaminated by artifacts. Most importantly,

peri-orbital electrodes are non-invasive and do not induce pain. Results from the present study demonstrated that peri-orbital electrodes can be an effective supplemental electrodes for detecting MTLE ictal epileptiform discharges.

## DISCLOSURE

No authors have any conflict of interest to disclose.

## REFERENCES

1. Kissani N, Alarcon G, Dad M, Binnie CD, Polkey CE. Sensitivity of recordings at sphenoidal electrode site for detecting seizure onset: evidence from scalp, superficial and deep foramen ovale recordings. *Clin Neurophysiol* 2001; 112:232-40.
2. Kanner AM, Parra J, Gil-Nagel A, *et al*. The localizing yield of sphenoidal and anterior temporal electrodes in ictal recordings: a comparison study. *Epilepsia* 2002; 43:1189-96.
3. Binnie CD, Marston D, Polkey CE, Amin D. Distribution of temporal spikes in relation to the sphenoidal electrode. *Electroenceph clin Neurophysiol* 1989; 73:403-9.
4. Mintzer S, Nicholl JS, Stern JM, Engel J. Relative utility of sphenoidal and temporal surface electrodes for localization of ictal onset in temporal lobe epilepsy. *Clin Neurophysiol* 2002; 113:911-6.
5. Nayak D, Valentin A, Alarcón G, *et al*. Characteristics of scalp electrical fields associated with deep medial temporal epileptiform discharges. *Clin Neurophysiol* 2004; 115:1423-35.
6. Goodin DS, Aminoff MJ, Laxer KD. Detection of epileptiform activity by different noninvasive EEG methods in complex partial epilepsy. *Ann Neurol* 1990; 27:330-4.
7. Zijlmans M, Huiskamp GM, van Huffelen AC, Spetgens WP, Leijten FS. Detection of temporal lobe spikes: comparing nasopharyngeal, cheek and anterior temporal electrodes to simultaneous subdural recordings. *Clin Neurophysiol* 2008; 119:1771-7.
8. Laxer KD. Mini-sphenoidal electrodes in the investigation of seizures. *Electroencephalogr Clin Neurophysiol* 1984; 58:127-9.
9. Silverman D. The anterior temporal electrode and the ten-twenty system. *Electroencephalogr Clin Neurophysiol* 1960; 12:735-7.
10. Morris HH 3rd, Lüders H, Lesser RP, Dinner DS, Klem GH. The value of closely spaced scalp electrodes in the localization of epileptiform foci: a study of 26 patients with complex partial seizures. *Electroenceph clin Neurophysiol* 1986; 63:107-11.
11. Homan RW, Jones MC, Rawat S. Anterior temporal electrodes in complex partial seizures. *Electroenceph clin Neurophysiol* 1988; 70:105-9.
12. Krauss GL, Lesser RP, Fisher RS, Arroyo S. Anterior "cheek" electrodes are comparable to sphenoidal electrodes for the identification of ictal activity. *Electroenceph clin Neurophysiol* 1992; 83:333-8.
13. Buchhalter JR, Schomer DL, Schachter SC. Standard sphenoidal and mini-sphenoidal electrodes: a direct comparison. *J Epilepsy* 1991; 4:29-31.
14. Schomer DL. The sphenoidal electrode: myth and reality. *Epilepsy Behav* 2003; 4:192-7.
15. Marks DA, Katz A, Booke J, Spencer DD, Spencer SS. Comparison and correlation of surface and sphenoidal electrodes with simultaneous intracranial recording: an interictal study. *Electroenceph clin Neurophysiol* 1992; 82:23-9.
16. Sparkes M, Valentin A, Alarcón G. Mechanisms involved in the conduction of anterior temporal epileptiform discharges to the scalp. *Clin Neurophysiol* 2009; 120:2063-70.