

**Abstract**

Emphysematous pyelonephritis is a rare life-threatening condition caused by a severe acute necrotising infection of the renal parenchyma and its perinephric tissues, and it is commonly seen in diabetic patients. There is a rare association between emphysematous pyelonephritis and hepatic portal venous gas. Hepatic portal venous gas is an uncommon radiological finding, which implies a significant underlying abdominal disease. The management of emphysematous pyelonephritis has evolved from prompt nephrectomy to medical therapy. In the present report, we present a case of a diabetic woman diagnosed with bilateral emphysematous pyelonephritis with hepatic portal venous gas that was successfully managed medically despite the presence of poor prognostic factors, such as acute renal failure and thrombocytopenia.

**Keywords:** acute renal failure, diabetes mellitus, hepatic veins, necrotizing pyelonephritis, nephrectomy

**Introduction**

Emphysematous pyelonephritis (EPN) is an acute, rare and life-threatening condition that bilaterally occurs in 5–7% cases (1). EPN is commonly seen in patients with obstructive uropathy and/or in immunocompromised patients, often due to diabetes mellitus (2). Hepatic portal venous gas (HPVG) is associated with underlying abdominal diseases, ranging from benign conditions to potentially fatal diseases that require urgent surgical interventions. Since 1994, only five cases of EPN associated with HPVG have been reported (3–7). We herein report a case of a poorly controlled diabetic patient diagnosed with bilateral EPN with HPVG who was successfully managed medically.

**Case Report**

A 58-year-old hypertensive diabetic woman presented with right flank and suprapubic pain that was associated with fever of one week duration. On presentation, the patient was alert and afebrile, with pulse of 110 beats/minute, a blood pressure (BP) of 101/67 mmHg and a random blood glucose of 21 mmol/L. An abdominal examination demonstrated suprapubic tenderness and a ballotable right kidney. The patient was in acute renal failure with a blood urea of 35 mmol/dL and serum creatinine of 448.8  $\mu$ mol/L.

Blood investigations revealed leukocytosis (white blood cell [WBC] count,  $17.2 \times 10^3/\text{mm}^3$ ),

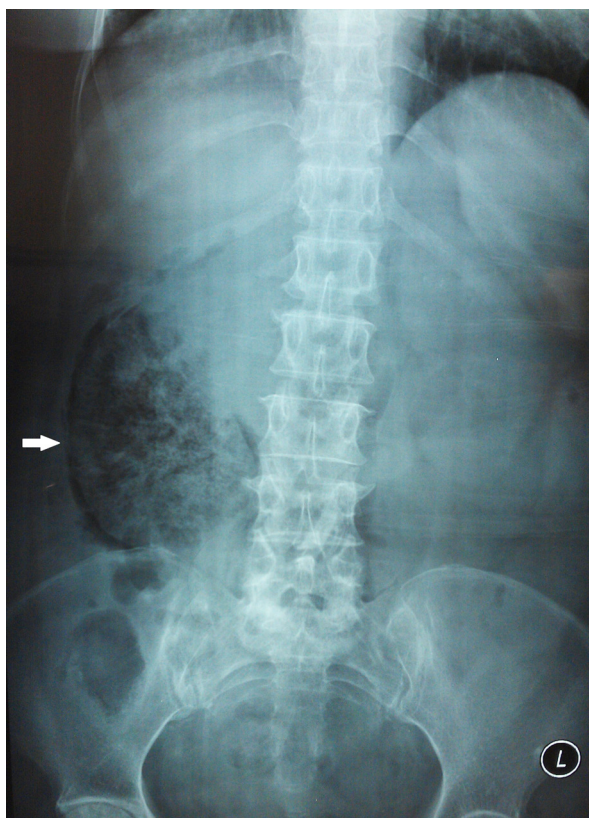
thrombocytopenia (platelet count,  $28 \times 10^3/\text{mm}^3$ ) and compensated metabolic acidosis (pH 7.410;  $\text{PCO}_2$ , 24.5 mmHg;  $\text{PO}_2$ , 102.9 mmHg;  $\text{HCO}_3^-$ , 15.2 mmol/L; and base excess  $-7.8$  mmol/L). Numerous blood cells and proteins were identified by urine microscopic examination. However, leucocytes and ketones were absent. A plain abdominal radiograph revealed mottled gas over the right renal area (Figure 1), suggesting EPN; intravenous meropenem (1 g) was empirically administered.

An urgent non-contrast computed tomography (CT) scan of the abdomen revealed the loss of normal appearance of the right kidney with parenchymal destruction, which was replaced with air (Figure 2). Moreover, the air tracked into the right ureter, extending into the right perinephric and posterior pararenal space. In the left kidney, an air locule was seen within the calyx, and portal venous gas was noted in the liver (Figure 3).

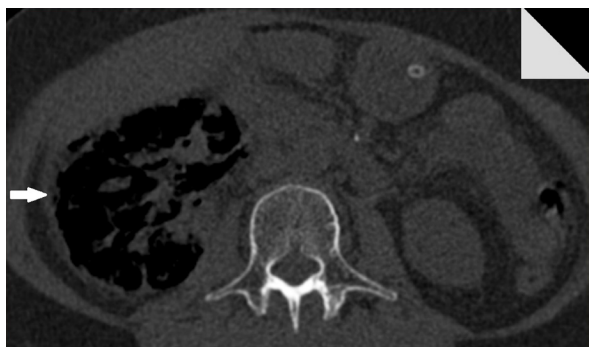The patient was managed in the high-dependency unit, and thrombocytopenia was corrected with platelet transfusion prior to urgent haemodialysis. Her blood glucose was optimised using an insulin infusion. The patient was discharged to the general ward the following day. Urine and blood cultures obtained prior to the commencement of intravenous antibiotic grew no organisms. In addition, intravenous meropenem was continued for 10 days, and the patient was

discharged and prescribed oral amoxicillin/clavulanic acid for another two weeks.

At a two weeks follow-up, her general condition was unremarkable, and her Modification of Diet in Renal Disease (MDRD) eGFR was 54 mL/min/1.73 m<sup>2</sup>. Further improvement of MDRD eGFR (67 mL/min/1.73 m<sup>2</sup>) was noted at 4 months.



**Figure 1:** A plain abdominal radiograph revealed mottled gas over the right renal area.



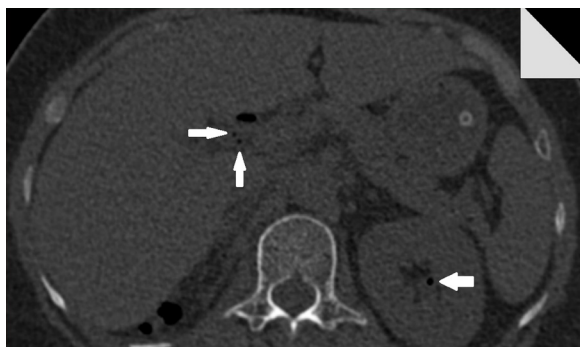**Figure 2:** A non-contrast CT scan of the abdomen revealed gas collection in the right kidney.

## Discussion

This is the first case of bilateral EPN with HPVG. In 1994, Chen et al. first described a case of unilateral EPN associated with HPVG (3). An additional four cases were described in the last five years. Of them, two cases were successfully treated conservatively with systemic antibiotic and percutaneous catheter drainage (4,5), and the other two patients underwent left nephrectomy for a non-functioning left kidney after initial medical treatment (6,7). There was a history of ureterorenoscopic lithotripsy and double-J stenting in one of these former patients (6). All four cases were adult diabetic patients, involving the left kidney (4–7).

HPVG is a radiological finding first described by Wolfe and Evens in infants with necrotising enterocolitis (NEC). It is commonly seen in cases of mesenteric ischemia (43–70%). Although the mechanism of HPVG is not fully understood (8,9), two theories have been postulated: (1) the migration of swallowed gas via the mural capillaries into the portal venous circulation due to high gastrointestinal luminal pressure, as seen in patients with gastrointestinal dilatation and (2) the presence of gas-forming bacteria either within the bowel, an abscess or portomesenteric pyelophlebitis (8,9).

The mechanism by which HPVG is associated with EPN is unclear. Theoretically, gas from a kidney migrates to the renal vein and subsequently into the inferior vena cava. It does not drain into the hepatic portal venous system. Therefore, the most likely mechanism is the presence of gas-forming bacteria from EPN that haematogenously spread into the hepatic portal venous system. The two most common organisms



**Figure 3:** A non-contrast CT scan of the abdomen revealed hepatic portal venous gas and a locule gas over the left kidney.

cultured in EPN are *Escherichia coli* (69%) and *Klebsiella pneumonia* (29%) (2). Therefore, the mixed acid fermentation of glucose by these Enterobacteriaceae in the hepatic portal venous system may cause HPVG. The second possibility by which HPVG is associated with EPN is the passage of gas from the renal tissues to the portal vein via the portosystemic collaterals. The final possibility is that a low-grade bowel infection in the immunocompromised state leads to HPVG in EPN (6).

The early reported mortality rate of HPVG was 56–90% (9). However, with the increasing use and advancement of the computed tomography (CT) scan, more benign conditions were detected. Therefore, the mortality rate of HPVG varies according to the underlying pathology (8). The prognosis of EPN is based on the clinicoradiological classification and the management of the disease. In 2000, Huang and Tseng described the clinicoradiological classification, management and prognosis of EPN based on CT scan findings. They classified 48 cases of EPN into 4 classes:

- Class 1: Gas in the collecting system only (mortality rate, 0%)
- Class 2: Gas in the renal parenchyma without extension to the extrarenal space (mortality rate, 10%)
- Class 3a: Extension of gas or an abscess to the perinephric space (mortality rate, 29%)
- Class 3b: Extension of gas or abscess to pararenal space (mortality rate, 19%)
- Class 4: Bilateral EPN or solitary kidney with EPN (mortality rate, 50%) (2)

In contrast, the mortality rate in patients with EPN treated medically is higher than those treated surgically: 70% versus 30%, respectively (2).

Therefore, the decision-making for managing EPN is based on the clinicoradiological classification of the disease. Nephrectomy provided the best treatment outcome for class 3 and class 4 EPN with a fulminant course (2). Non-operative treatments are reserved for class 1, class 2, and class 3 or class 4 EPN with benign manifestation (2). The fulminant course of EPN was described as the presence of 2 or more poor prognostic factors: thrombocytopenia, acute renal failure, disturbance of consciousness and shock (2). With the advancement in imaging techniques

and newer antibiotics, medical treatment has become an effective alternative to nephrectomy. Dutta et al. reported cases of bilateral EPN with a fulminant course that were successfully treated medically (10).

Our patient, a class 4 EPN with HPVG, was successfully managed medically despite the presence of fulminant features (thrombocytopenia and acute renal failure). The initiation of medical therapy aimed to optimise the patient prior to nephrectomy. She was managed by multidisciplinary teams comprising general surgeons, radiologists, internal medicine physicians, anaesthesiologists, and nurses. However, nephrectomy was avoided because her general condition markedly improved the following day.

The patient presented with right flank pain. However, urine examination did not reveal any pus cells. This was probably due to a transient obstruction, which was relieved by the passage of a calculus.

The case further supports the role of the medical treatment of EPN with HPVG using early diagnosis, aggressive resuscitation, intensive care, and multidisciplinary management. We believe that with current intensive multidisciplinary care, medical management has an important role in the treatment of all classes of EPN, even with the presence of HPVG.

## Conclusion

EPN is a rare life-threatening condition. The occurrence of HPVG in EPN is even rarer. HPVG is a radiological finding that associated with benign to potentially fatal abdominal disease. However, the presence of HPVG in EPN is not an absolute indication for an urgent operative management. Medical management for all classes of EPN, even with fulminant course and presence of HPVG, seem to be effective.

## Acknowledgement

The authors would like to thank the Director of Health Malaysia for the permission to publish this paper.

## Conflicts of Interest

None.

## Funds

None.

## Authors' Contributions

Conception and design, analysis and interpretation of the data, drafting of the article, critical revision of the article for the important intellectual content: MLC

Final approval of the article: MLC, HN, CHL

## Correspondence

Dr Mao Li Cheng  
MB BCh BAO (National University of Ireland)  
Department of Surgery  
Hospital Segamat  
KM 6, Jalan Genuang  
85000 Segamat, Johor  
Malaysia  
Tel: +607-943 3333  
Fax: +607-943 4641  
Email: maoli\_84@hotmail.com

## References

1. Shigemura K, Yasufuku T, Yamashita M, Arakawa S, Fujisawa M. Bilateral emphysematous pyelonephritis cured by antibiotics alone: A case and literature review. *Jpn J Infect*. 2009;**62**(3):206–208.
2. Huang JJ, Tseng CC. Emphysematous pyelonephritis clinicoradiological classification, management, prognosis and pathogenesis. *Arch Intern Med*. 2000;**160**(6):797–805. doi: 10.1001/archinte.160.6.797.
3. Chen KW, Huang JJ, Wu MH, Lin XZ, Chen CY, Ruaan MK. Gas in hepatic veins: a rare and critical presentation of emphysematous pyelonephritis. *J Urol*. 1994;**151**(1):125–126.
4. Sung JM, Shih TE, Wu AB. Hepatic portal vein gas associated with emphysematous pyelonephritis: A rare association. *Nephrology (Carlton)*. 2010;**15**(4):504–505. doi: 10.1111/j.1440-1797.2010.01209.x.
5. Chang CJ, Shun HC, Chuang CC. Hepatic portal venous gas induced by emphysematous pyelonephritis: A rare case in hemodialytic women. *Am J Emerg Med*. 2009;**27**(9):1171. doi: 10.1016/j.ajem.2009.01.005.
6. Sen D, Sandhu AS. A rare occurrence of hepatic portal venous gas in emphysematous pyelonephritis. *Indian J Urol*. 2014;**30**(1):108–109. doi: 10.4103/0970-1591.124218.
7. Mao YC, Wang JD, Wang LM. Hepatic portal venous gas caused by emphysematous pyelonephritis. *Clin Gastroenterol Hepatol*. 2009;**7**(10):A25. doi: 10.1016/j.cgh.2009.02.001.
8. Nelson AL, Millington TM, Sahani D, Chung RT, Bauer C, Hertl M, et al. Hepatic Portal Venous Gas: The ABCs of Management. *Arch Surg*. 2009;**144**(6):575–581. doi: 10.1001/archsurg.2009.88.
9. Abboud B, El Hachem J, Yazbeck T, Doumit C. Hepatic portal venous gas: physiopathology, etiology, prognosis and treatment. *World J Gastroenterol*. 2009;**15**(29):3585–3590. doi: 10.3748/wjg.15.3585.
10. Dutta D, Shivaprasad KS, Kumar M, Biswas D, Ghosh S, Mukhopadhyay P, et al. Conservative management of severe bilateral emphysematous pyelonephritis: Case series and review of literature. *Indian J Endocrinol Metab*. 2013;**17**(Suppl 1):S329–S332. doi: 10.4103/2230-8210.119631.