

## Case Report

# A Rare Case of Undescended Caecum Accompanied by Looped Retroperitoneal Appendix

Ashwini AP, Naveen K (✉), Jyothsna P, Swamy RS, Satheesha NB

Department of Anatomy, Melaka Manipal Medical College (Manipal Campus), Manipal University, Manipal, 567104 Karnataka State, India.

### Abstract

Intestinal malrotations are associated with various anatomical anomalies. We report a unique case wherein the caecum was located in the right lumbar region instead of the right iliac fossa. The ileo-caecal junction was also placed higher up. The appendix was 'uncinate' shaped, highly coiled and retroperitoneal with the absence of meso-appendix. Both, the caecum and appendix were supplied by ascending branch of the ileocolic artery instead of the descending branch. Further, we also observed that the ascending colon was very short and sub-hepatic in position. Such type of variations is of clinical and surgical importance in diagnosis and treatment of appendicitis.

**Keywords:** Appendix, caecum, ascending colon, ileo-caecal junction, malrotation

### Correspondence:

Naveen Kumar, Department of Anatomy, Melaka Manipal Medical College (Manipal Campus), Manipal University, Manipal, 567104 Karnataka State, India. Tel: +91 9880548636 Fax: 0820-2571201 Email: naveentonse@gmail.com

Date of submission: 11 Apr, 2014

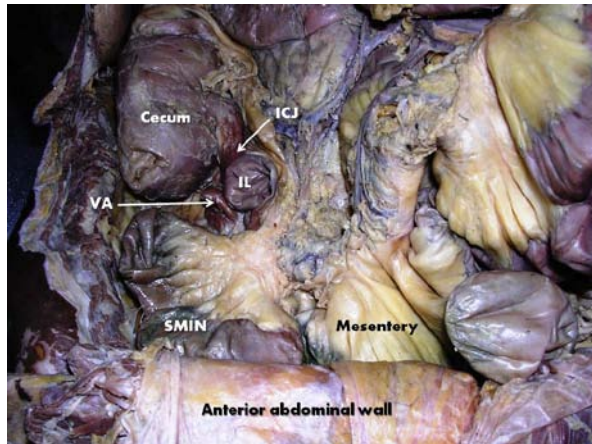
Date of acceptance: 23 Oct, 2014

### Introduction

The caecum is the commencement of large gut. It is usually an asymmetric, cul-de-sac which normally lies in the right iliac fossa. Appendix is a narrow, worm-like tubular diverticulum which arises from the postero-medial wall of the caecum. It is suspended by a peritoneal fold known as the meso-appendix (1). Position of the tip of the appendix is highly variable. It may occupy any one of the following positions such as retrocaecal (65.3%), pelvic (31%), subcaecal (2.3%), pre-ileal, lumbar (1%) and post-ileal (0.4%) positions. Subhepatic, left sided, lateral pouch and mesocolic positions of appendix are reported to be very rare positions (2). The caecum and appendix are supplied by branches arising from the descending branch of ileo-colic artery. In this report, we discuss a rare case of undescended caecum accompanied by retroperitoneal appendix with differential arterial supply.

### Case Report

During routine cadaveric dissection for medical undergraduate students, we noticed multiple variations in the general disposition of abdominal viscera. The caecum and appendix were present in the right lumbar region instead of the right iliac fossa (Fig. 1). The coils of jejunum occupied the region of the right iliac fossa. The ileocaecal junction was vertically placed along the axis of the caecum in contrast to its normal horizontal position and was higher than usual. Appendix was about 8 cm long, retroperitoneal, highly coiled and formed a "U" shaped bend. Its tip was adherent to the parietal peritoneum and was subcaecal in position (Fig. 2). Further, we also observed that the caecal and appendicular arteries which are normally branches of the descending branch of ileocolic artery were arising from the ascending branch of the ileocolic artery. The descending branch was very slender and did not give any branch and ended by anastomosing with superior mesenteric artery. The ascending colon was also very



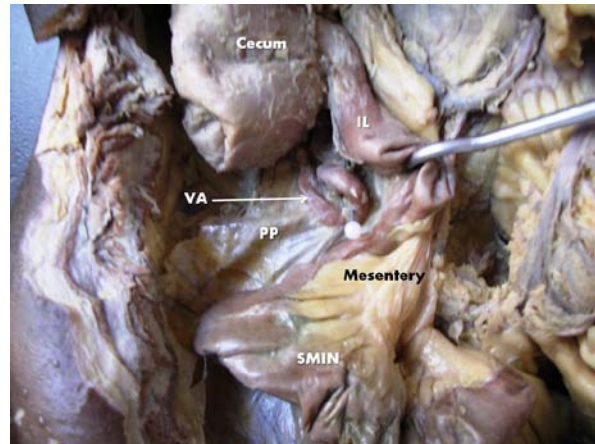
**Figure 1:** Showing the abnormal disposition of contents in the right iliac fossa after reflecting the anterior abdominal wall. Coils of small intestine (SMIN) occupied the right iliac fossa, so that position of cecum, vermiform appendix (VA) and ileum (IL) is displaced upwards. ICJ- ileo-cecal junction.

short and situated below the liver in the sub-hepatic position. No other visceral variations were observed in this male cadaver aged approximately 60 years.

## Discussion

Intestinal malrotations are applied to an extensive developmental abnormality. Development of midgut is divided in to 3 stages. In the first stage intestinal loop rotates through an angle of 90 degrees in an anticlockwise manner and in second stage it shows sequential reduction of the intestinal loop from physiological hernia at the end of tenth week of gestation, until the caecum reaches the subhepatic region. In the third stage, caecum and appendix grow caudally from subhepatic region, pass through right lumbar region and finally occupy the definitive position in right iliac fossa. The total range of rotation around superior mesenteric artery is thus about 270 degrees. When the rotation is complete the derivatives of midgut undergo a process of fixation. Due to defects of fixation the caecum and appendix may occupy the subhepatic, right lumbar or pelvic region (3). This explains the presence of caecum and appendix in the right lumbar region as in the present case.

A case of undescended caecum has been reported by Meera et al. (4). During our literature survey we did not find any case or reports of retroperitoneal appendix. Nayak et al. (5) reported a rare case of uncinat appendix which was associated with subhepatic caecum and retro peritoneal ileum. A sub



**Figure 2:** Showing variant peritoneal relation of the vermiform appendix (VA). Appendix is placed retroperitoneal with a U- shaped bend. PP: parietal peritoneum, SMIN- small intestine, IL- Ileum.

hepatic appendix which was attached to the right side of the cecum and covered by a peritoneal fold was reported by Ahmadpour et al. (6). It has been stated that any symptoms of subhepatic appendicitis can imitate cholecystitis and its perforation can mimic the manifestations of liver abscess which is surgically misleading and may cause serious complications (7, 8). Unusual position of the ileocaecal valve may alter the normal function of the ileocaecal valve (6). So, the radiological imaging and clinical interpretation of the abdominal viscera before performing any surgery is important, especially in abnormal position of caecum and appendix (9).

Acute appendicitis is considered as a common disease (10). Generally, diagnosis of appendicitis is simple as clinical manifestations are common in almost all cases. However abnormal positions of the appendix and ileocaecal junction may lead to difficulty in diagnosis and surgical and laparoscopic procedures (10). In general locating the variant position of appendix will be a challenging task while performing an open appendectomy surgical procedure. Unusual position of appendicular base may cause complications in the diagnosis of acute appendicitis and in such cases the point of maximum tenderness does not correspond to the Mc-Burney's point (11).

A retroperitoneal appendix is not only liable to get cut off from direct superior mesenteric circulation during any surgery, but also it is hazardous to remove it through normal incision used in appendectomy because there is a high probability of rupturing this retroperitoneal appendix (12). Similarly, a laparoscopic appendectomy is not possible in such

cases as the tip of the appendix is not visualized. So, the presence of retroperitoneal appendix should be on a surgeons mind and a retrograde appendectomy is the surgery which is preferred for a retroperitoneal appendix (13).

### Conclusion

Concurrent visceral variations involving undescended cecum and retroperitoneal appendix, is a rare anomaly. Such an anatomical variation as we reported herein may pose different clinical appearance when these organs are affected. Prior knowledge on existence of such variations is necessary for the surgeons performing laparoscopic abdominal operations as this will assist them in best possible diagnosis of related pathological conditions.

### References

1. Standring S. Gray's Anatomy-The Anatomical Basis of Clinical Practice. 39th ed. New York: Elsevier Churchill Livingstone, 2005, pp-1176-8.
2. Tucker O, Rashid Al-fagih S, El-Amin O, Zaki A. Laparoscopic appendectomy: review of 331 cases over 7 years, in a Saudi Arabian hospital. *Endoscopy* 2002; 34(8): 639-42.
3. Datta AK. Essentials of Human Embryology. 8<sup>th</sup> ed. Kolkata: Current Books International, 2008, pp 216.
4. Meera J, Shivarama CH, Bindu S, Rani N, Avadhani R. Undescended caecum and appendix with right sided sigmoid colon - a case report. *NUJHS* 2013; 3(4): 125-7.
5. Nayak SB, George BM, Mishra S, Surendran S, Shetty P, Shetty SD. Sessile ileum, subhepatic cecum, and uncinat appendix that might lead to a diagnostic dilemma. *Anat Cell Biol* 2013; 46(4): 296-8.
6. Ahmadpour SH, Nasirizadeh S, Gorjifard M. Abnormal retroperitoneal ileum, undscended ileocecal junction and subhepatic appendix in a macrosomatic fetus: a case report. *J Morphol Sci* 2012; 29: 120-2.
7. Kulvatunyou N, Schein M. Perforated subhepatic appendicitis in the laparoscopic era. *Surg Endosc* 2001; 15(7): 769.
8. Patel NR, Lakshman S, Hays TV, Thomas E. Subhepatic appendix with fecolith mimicking acute cholecystitis with gallstone. *J Clin Ultrasound* 1996; 24(1): 45-7.
9. Savithri P. Subhepatic caecum and appendix – A rare variant in an adult male cadaver. *NJCA* 2013; 2(2): 93-6.
10. Brogden TG, Streets CG. The management of acute appendicitis. *R Nav Med Serv* 2013; 99(3): 106-10.
11. Varsheney S, Johnson CD, Ramgneker GV. The retrocaecal appendix appears to be less prone to infection. *Br J Surg* 1996; 83(2): 223-4.
12. Small AB. The retroperitoneal appendix. *Texas State JM* 1928; 24: 550-5.
13. Verghese BG, Kashinath SK, Ravikanth R. Retroperitoneal Appendicitis: A Surgical Dilemma. *Euroasian J Hepato-Gastroenterology* 2013; 3(1): 83-4.