

## Case Report

# Variant Origin of the Left Vertebral Artery from a Vertebro-Subclavian Trunk Associated with an Unusual Branch Arising from the Brachiocephalic Trunk

Satheesha BN, Sirasanagandla SR (✉), Surekha DS, Deepthinath R, Sudarshan S, Raghu J

Department of Anatomy, Melaka Manipal Medical College (Manipal Campus), Manipal University, Manipal, Karnataka State, 576104 India.

### Abstract

Variant origin of the left vertebral artery (LVA) from the arch of aorta is well documented in the literature. Involvement of complex sequential developmental steps in the aortic arch formation results in different patterns of origin of LVA. Morphological variations in the LVA are thought to alter the cerebral hemodynamics and can cause the cerebral dysfunction. Knowledge of the morphological variations of the LVA is useful while performing the head and neck and thoracic surgeries. We here report one of the extremely rare patterns of the LVA origin, in a male cadaver aged about 65 years. LVA and left subclavian artery (LSA) arose as a common vertebro-subclavian trunk from the convexity of the aortic arch. Further, brachiocephalic trunk (BT) gave an unusual artery from its anterior surface. This artery divided into thymic and tracheal branches. Variant origin of thymic branch may be crucial during imaging and thymectomy procedures.

**Keywords:** Vertebral artery, subclavian artery, variation, brachiocephalic trunk, thymic branch, tracheal branch

### Correspondence:

Srinivasa Rao Sirasanagandla, Department of Anatomy, Melaka Manipal Medical College (Manipal Campus), International Centre for Health Sciences, Manipal University, Madhav Nagar, Udupi District, Karnataka State, 576104 India. Tel: +91-820-2922644 Fax: +91-820-2571905 Email: seenaih.anat@gmail.com

Date of submission: 13 Aug, 2013

Date of acceptance: 24 March, 2014

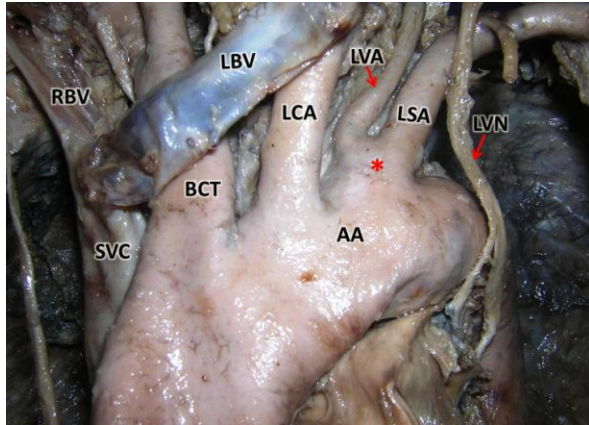
### Introduction

LVA frequently shows variations in its origin. It may arise as a direct branch from the arch of aorta lying between the left common carotid artery (LCA) and LSA or to the left of LSA. It may also arise from the common carotid artery or BT. It usually arises from the LSA, ½ to 2 cm medial to the origin of the thyrocervical trunk. Rarely, it may arise from the thyrocervical trunk or from the root of the LSA, close to aortic arch (1, 2). The developmental errors in the fusion of the aortic arches into aortic sac usually account for the anomalous branching pattern of the aortic arch (3). BT usually arises from the convexity of the aortic arch, posterior to manubrium of sternum. BT divides into the right subclavian and right common carotid arteries, at the level of right sternoclavicular

joint. Rarely, it may give rise to a small branch such as pericardial, tracheal, mediastinal, diaphragmatic, thymic or a bronchial branch. It may also give rise to larger branches such as left common carotid, internal thoracic, vertebral, thyroidea ima and inferior thyroid arteries. It may be completely absent also (4). In the present case, we report a rare case of origin of LVA and LSA through a common trunk from the aortic arch, and an unusual branch arising from BT.

### Case Report

During regular dissections for medical undergraduates, we came across a rare vascular variation in the superior mediastinum of a male cadaver aged about 65 years. LVA and LSA arose through a common vertebro-subclavian trunk (Fig. 1 and 2). This trunk

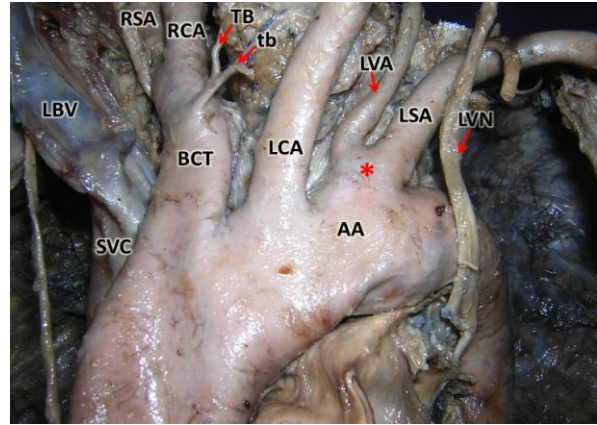


**Figure 1:** Anterior view of the mediastinum showing the variant origin of the left subclavian artery and left vertebral artery. (Asterisk: common vertebro-subclavian trunk; LVA: left vertebral artery; LSA: left subclavian artery; AA: arch of aorta; LBV: left brachiocephalic vein; BCT: brachiocephalic trunk; RBV: right brachiocephalic vein; SVC: superior vena cava; LVN: left vagus nerve)

was short, broad and took its origin from the aortic arch, to the left of the LCA. The common trunk was 1 cm long and 1.5 cm broad. The course of LVA in the superior mediastinum and the neck was normal. Its branching pattern was also normal. Further, BT arose from the convexity of the aortic arch, then ascended on the right side of the trachea and divided into right common carotid and right subclavian arteries at the level of the upper border of the sternoclavicular joint. In addition to the terminal branches, BT gave a small branch from its anterior surface, at a distance of 2 cm from its point of origin (Fig. 2). This artery divided into a thymic branch and tracheal branch to supply thymus and trachea, respectively.

## Discussion

Though, the morphological and anatomical variations of the LVA have been reported in scientific literature, documentation of its variant origin has immense importance in clinical practice (5). It has been demonstrated that variant origin and distributions of the aortic arch branches can affect the cerebral haemodynamics and subsequently result in cerebral abnormalities (6). LVA frequently takes its origin from the arch of aorta. The frequency of such a variation is reported to be 1-3% (7). Lippert and Pabst classified the variant origin of LVA from the aortic arch into following types. Type A: it arises from the aortic arch, between the LCA and LSA; Type B: it takes origin between a common trunk formed by LCA and BT and LSA; Type C: it arises to the left of LSA; Type D: it arises as a third branch next to LSA; Type E: originates as a second branch next to common trunk; Type F: different from Type A, where the right



**Figure 2:** Anterior view of the mediastinum showing the unusual branches of the brachiocephalic trunk (BT). The thymic remnants have been pushed behind the great vessels for clarity. (tb: thymic branch; TB: tracheal branch; asterisk: common vertebro-subclavian trunk; LSA: left subclavian artery, LVA: left vertebral artery; AA: arch of aorta; LBV: left brachiocephalic vein (reflected); BCT: brachiocephalic trunk; SVC: superior vena cava; LVN: left vagus nerve; RCA – right common carotid artery; RSA: right subclavian artery)

subclavian artery arises from descending aorta; Type G: one of two roots as a penultimate branch; Type H: vertebral artery is duplicated and both branches arise from the aortic arch (8). Lippert and Pabst have noted Type A in majority of the cases when compared to other types. Many authors have reported the occurrence of Type A pattern of LVA (2,9,10,11). Contrary to the above classification, in the present case, we report a rare type of origin of LVA through a common vertebro-subclavian trunk from the arch of aorta. Earlier, Alsaif and Ramadan, in their cadaveric study observed the occurrence of such common trunk in only one specimen. The morphological variations of the LVA may be clinically asymptomatic (12). However, knowledge of the various patterns of variant origins LVA has immense importance in thoracic surgeries and cardiac catheterization procedures.

Many authors have attempted to explain the possible mechanisms involved in the variant origin of LVA. Vorster et al. have mentioned that the development of the branches of subclavian artery depends on the blood flow through the least resistance longitudinal channels and tension on the vessels created by the caudal shifting of the heart and aorta (13). Support for their view comes from the following facts of the normal development. Vertebral artery develops from the longitudinal anastomosis between the intersegmental arteries. The caudal shifting of heart and aorta may result in the tension in the initial parts of the intersegmental arteries. It may also lead to bending of these channels which can affect the blood flow (14).

The variant origin of the LVA from the aortic arch may also be associated with the abnormal development of the aortic arch. This anomalous development occurs due to the errors in the embryonic development of aortic arch arteries. The animal models and human genetic models have demonstrated that chromosome 22q is involved in this anomaly (14). Panicker et al. have mentioned that the variant origin may be due to the regression of left 7th dorsal intersegmental artery and persistence of left 6th dorsal intersegmental artery (15).

Usually, thymic artery takes origin from the anterior mediastinal branch of the internal thoracic artery. Rarely, it may arise from the BT (4). In a study by Bell et al., it was observed in two cases out of 77 subjects (16). In the present case, thymic branch and tracheal branch arose as a common trunk from the BT. Knowledge of this anatomical variant may be important to avoid its iatrogenic injuries during the surgical procedures in the mediastinum.

## References

1. Bergman RA, Afifi AK, Miyauchi M. Illustrated Encyclopedia of Human Anatomic Variation: Opus II: Cardiovascular System: Arteries: Head, Neck, and Thorax. Vertebral arteries. <http://www.anatomyatlases.org/AnatomicVariants/Cardiovascular/Text/Arteries/Vertebral.shtml>. Last accessed on 10/08/2013
2. Jayanthi V, Prakash, Devi MN, Geethanjali BS, Rajini T. Anomalous origin of the left vertebral artery from the arch of the aorta: review of the literature and a case report. *Folia Morphol (Warsz)* 2010; 69(4): 258-260.
3. Congdon ED. Transformation of the aortic-arch system during the development of human embryo. *Contrib Embryol Carnegie Inst* 1922; 68: 47-110.
4. Bergman RA, Afifi AK, Miyauchi M. Illustrated Encyclopedia of Human Anatomic Variation: Opus II: Cardiovascular System: Arteries: Head, Neck, and Thorax. Brachiocephalic artery. <http://www.anatomyatlases.org/AnatomicVariants/Cardiovascular/Text/Arteries/Brachiocephalic.shtml>. Last accessed on 10/08/2013
5. Matula C, Trattinig S, Tschabitscher M, Day JD, Kaos WT. The course of the prevertebral segment of the vertebral artery: anomaly and clinical significance. *Surg Neurol* 1997; 48(2): 125-131.
6. Bernardi L, Deton P. Angiographic study of a rare anomalous origin of the vertebral artery. *Neuroradiology* 1975; 9: 43-47.
7. Daseler EH, Anson BJ. Surgical anatomy of the subclavian artery and its branches. *Surg Gynecol Obstet* 1959; 108(2): 149-174.
8. Lippert H, Pabst R. Arterial variations in man. Classification and frequency. Munchen: JF Bergmann Verlag, 1985, pp-30-38.
9. Imre N, Yalcin B, Ozan H. Unusual origin of the left vertebral artery. *IJAV* 2010; 3: 80-82.
10. Patasi B, Yeung A, Goodwin S, Jalali A. Anatomical variation of the origin of the left vertebral artery. *IJAV* 2009; 2: 83-85.
11. Singla RK, Sharma T, Sachdeva K. Variant origin of left vertebral artery. *IJAV* 2010; 3: 97-99.
12. Alsaif HA, Ramadan WS. An anatomical study of the aortic arch variations. *JKAU Med Sci* 2010; 17(2): 37-54.
13. Vorster W, du Plooy PT, Meiring JH. Abnormal origin of internal thoracic and vertebral arteries. *Clin Anat* 1998; 11(1): 33-37.
14. McElhinney DB, Goldmuntz E. Abnormalities of the aortic arch. Orphanet Encyclopedia, 2004. <http://www.orpha.net/data/patho/GB/uk-aortic-arch.pdf>. Last accessed on 10/08/2013
15. Panicker HK, Tarnekar A, Dhawane V, Ghosh SK. Anomalous origin of left vertebral artery-embryological basis and applied aspects - A case report. *J Anat Soc India* 2002; 51(2): 234-235.
16. Bell RH, Knapp BI, Anson BJ, Larson SJ. Form, size, blood supply and relations of the adult thymus. *Q Bull Northwest Univ Med Sch* 1954; 28(2): 156-164.