

Case Report

An Unusual Branching Pattern of the Median Cubital Vein and its Relations with Lateral Cutaneous Nerve of Forearm in the Upper Extremity: Anatomicoclinical Notes

Mona S (✉), Ranjeeta H, Vandana M, Jyoti A, Rajesh S, Gayatri R

Department of Anatomy, Vardhman Mahavir Medical College & Safdarjung Hospital, 110029 New Delhi, India.

Abstract

Cubital fossa is the usual site for performing venepuncture in the clinical settings for health screenings and diagnostic purposes. This procedure is simple and uncomplicated but occasionally can lead to bleeding and pain in the form of complex regional pain syndrome. Superficial veins of the upper limb are often used for venepuncture for transfusion purposes and for obtaining blood samples. These veins are also used for cardiac catheterisation and giving intravenous injections. During routine cadaveric dissection, a cubital venous variation was observed in a 45-yr-old, male cadaver. The median cubital vein initiated from cephalic vein passed upwards and laterally superficial to posterior branch of medial cutaneous nerve of forearm. In the middle of its course, it gave off an ascending channel which further divided into medial and lateral tributaries. The medial tributary terminated into the basilic vein, whereas the lateral tributary ascended laterally superficial to a branch of lateral cutaneous nerve of forearm and drained into cephalic vein at the level of elbow joint. Various patterns of superficial cubital veins have been mentioned in literature. Awareness of such anatomical variations is crucial while performing venepuncture in clinical settings as well as for creating arteriovenous fistulas for hemodialysis purpose.

Keywords: Cephalic, basilic, elbow, cutaneous nerves, hemodialysis

Correspondence:

Mona Sharma, Department of Anatomy, Vardhman Mahavir Medical College & Safdarjung Hospital, 110029 New Delhi, India. Tel: 9968147821 Email: dr.mona18sharma@gmail.com

Date of submission: 10 Jan, 2014

Date of acceptance: 18 April, 2014

Introduction

The upper extremity is drained by superficial and deep veins which are interconnected by perforating veins having valves. The superficial group of veins is usually comprised of cephalic vein, basilic vein and median cubital vein. Cephalic vein and basilic veins initiate from the lateral and medial side of dorsal venous arch respectively. Cephalic vein ascends along the lateral margin of front of forearm and finally drain in to the axillary vein whereas basilic vein ascends posteromedially along forearm, finally pierces deep fascia at middle of arm and accompanies venae comitantes of brachial artery. The basilic vein is joined by median cubital vein just distal to the elbow. Median cubital vein (MCV) is the anastomosing venous

channel present on the anterior aspect of elbow and passes superomedially from cephalic to basilic vein usually between medial and lateral cutaneous nerves of forearm. The medial cutaneous nerve of forearm arising from medial cord passes between axillary artery and vein. It further descends medial to brachial artery and at the middle of the arm, pierces deep fascia along with basilic vein and divides into anterior and posterior branches. Anterior branch is larger and passes anterior or posterior to MCV, descends anteromedially. Posterior branch descends medial to basilic vein and curves backwards to reach the wrist. The musculocutaneous nerve continues downwards as the lateral cutaneous nerve of forearm. It pierces deep fascia just lateral to biceps brachii tendon and further divides into anterior and posterior branches. These

branches descend along the anterolateral and posterolateral aspects of forearm and supply these areas respectively (1).

The cubital venous anatomy has been associated with wide variations. The superficial venous system in the region of arm has been classified in six different types with subgroups having some other minor variations (2). Type 1 is the M shaped pattern where median antebrachial vein divides into median cephalic and median basilic veins which communicate with the cephalic and basilic veins respectively. Type 2 is N shaped arrangement where median cubital vein runs obliquely from cephalic vein and joins basilic vein. Type 3 is the most common H shaped where median cubital vein extends from cephalic vein to basilic vein and runs in front of the cubital fossa. In type 4, there is no communication seen between cephalic and basilic vein. Type 5 includes veins running from lateral to superomedial aspect of forearm. Type 6 includes double median antebrachial veins.

The present study reports another variation of cubital venous anatomy and its relations with cutaneous nerves. The awareness of these variations is important while performing upper limb venographies and arteriovenous fistula construction in hemodialyzed patients. The orientation of cubital cutaneous nerves is highly vital to avoid iatrogenic injuries during venepuncture.

Case Report

A unilateral anomalous arrangement of the cutaneous veins of the upper limb is the highlight of the current case study. This venous variation was found in the left sided upper limb of a 45-yrs-old male cadaver during the course of preclinical training session for medical students. The median cubital vein (MCV), a 10 cms long venous channel commenced from the cephalic vein 13 cms distal to the lateral epicondyle and passed superomedially superficial to medial branch of lateral cutaneous nerve of forearm (MLCNF) and posterior branch of medial cutaneous nerve of forearm (PMCNF). The MCV gave off an ascending channel of 7 cms length (ascending cubital vein, ACV) at the point of its crossing over the MLCNF which passed vertically up and reached just below the elbow joint where it divided into two tributaries (medial and lateral). The medial tributary (MACV) was 5 cms long and it communicated with basilic vein at 2 cms above the medial epicondyle whereas lateral tributary (LACV) was 7 cms long which ascended laterally by passing superficial to lateral branch of lateral cutaneous nerve of forearm (LLCNF). The LACV terminated into the cephalic vein 4 cms above the

lateral epicondyle. The course and termination pattern of basilic and cephalic veins displayed usual pattern on both sides. Medial cutaneous nerve of forearm (MCNF) pierced deep fascia along with basilic vein and divided into anterior and posterior branches. The anterior branch (AMCNF) passed anterior to MCV whereas posterior branch (PMCNF) coursed medial to basilic vein and deep to MCV. Lateral cutaneous nerve of forearm pierced deep fascia lateral to biceps tendon and divided into two branches; lateral and medial. The lateral branch (LLCNF) traversed inferolaterally and reached lateral aspect of lower third of forearm coming superficial to cephalic vein. The medial branch (MLCNF) passed deep to ascending brachial vein. It further coursed along the lateral border of forearm up to the base of thenar eminence (Fig. 1,2,3).

Discussion

The varied patterns of cutaneous nerves and vessels are based on their aberrant mode of development. The growing limb buds receive their vascular supply from the intersegmental artery (primary axial artery) originating from aorta. This artery forms capillary plexuses which drain into the peripheral marginal sinus. This sinus develops within the mesenchyme surrounding the growing limb buds. With the development of the digits, the marginal sinus breaks up and some of its portion develops into superficial venous system of upper limb (basilic and cephalic veins) whereas the remaining part develops into the deep venous system (3). The development of axillary vein in the limb bud takes place in the form of a dense capillary plexus that persists as a consequence of varied hemodynamic influences. Normally, deep vessels are formed as a result of some persistent anastomoses while other anastomoses regress (4). Presumably, the aberrant disposition of superficial venous anatomy of upper limb encountered in the current investigation could be the result of persistence of anastomotic channels which usually regress. The axonal growth cones also migrate simultaneously in the undifferentiated mesenchyme to form cutaneous nerves of upper limb. The aberrant process of breaking up of marginal sinus along with abnormal migration of axonal growth cones can lead to varied patterns of cutaneous veins and nerves in the upper limb. The altered disposition of LCNF in the present report, could possibly be attributed to the altered migration pattern of the axonal growth cones.

The anatomy of cubital veins is highly variable. The commonly mentioned venous variations are cephalic vein draining into basilic vein at distal third of arm (5), absence of cephalic vein and median cubital vein (6)



Figure 1: Dissection of elbow region displaying superficial veins (1. Biceps brachii, 2. Cephalic vein, 3. Basilic vein, 4. Median cubital vein (MCV), 5. Ascending Cubital vein (ACV), 5a1. Medial tributary of ACV (MACV), 5a2. Lateral tributary of ACV (LACV))



Figure 2: Dissection of elbow region displaying cutaneous nerves related to superficial veins (1. Biceps brachii, 2. Cephalic vein, 3. Basilic vein, 4. Median cubital vein (MCV), 5. Ascending Cubital vein (ACV), 5a1. Medial tributary of ACV (MACV), 5a2. Lateral tributary of ACV (LACV), 6. Medial cutaneous nerve of forearm (MCNF), 7. Anterior branch of MCNF (AMCNF), 8. Posterior branch of MCNF (PMCNF), 9. Lateral cutaneous nerve of forearm (LCNF), 10. Medial branch of LCNF (MLCNF), 11. Lateral branch of LCNF (LMCNF))

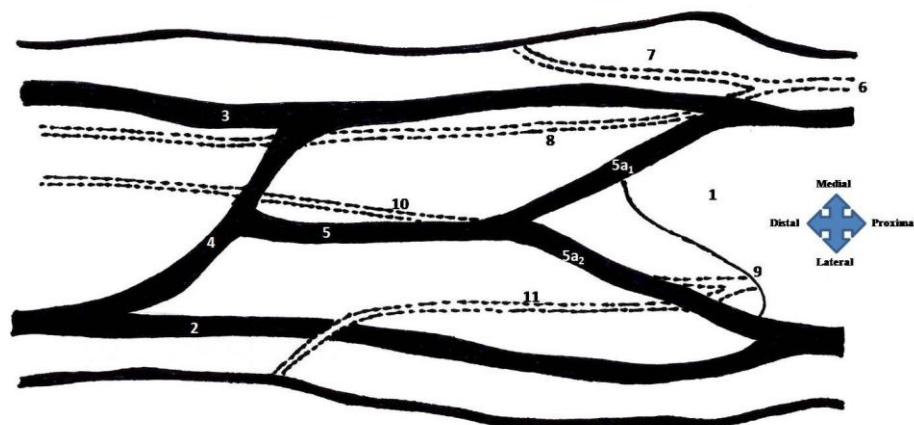


Figure 3: Line diagram showing the superficial veins and nerves (1. Biceps brachii, 2. Cephalic vein, 3. Basilic vein, 4. Median cubital vein (MCV), 5. Ascending Cubital vein (ACV), 5a1. Medial branch. Of ACV (MACV), 5a2. Lateral branch Of ACV (LACV), 6. Medial cutaneous nerve of forearm (MCNF), 7. Anterior branch of MCNF (AMCNF), 8. Posterior branch of MCNF (PMCNF), 9. Lateral cutaneous nerve of forearm (LCNF), 10. Medial branch of LCNF (MLCNF), 11. Lateral branch Of LCNF (LMCNF))

and cephalic vein terminating into external jugular vein (7). Our case report represents an entirely new cubital venous anatomy and does not conform to any of the previously described subtypes. In the present investigation, lateral extremity of MCV commencing at the cephalic vein distal to lateral humeral epicondyle is at unusually lower level. The venous channel ascending from MCV designated as ascending cubital vein (ACV) in the present study is an interesting observation. The ACV bifurcating into two tributaries constitutes a Y shaped pattern which is extremely rare and to the best of our knowledge has not been reported earlier. Further, it also needs to be emphasized that the ascending brachial vein encountered in the present study could also alter the hemodynamics of blood flow in the median cubital vein. Presumably, it could be responsible for engorgement of veins of arm by hampering the venous drainage. Variations in the cubital venous configurations become significant as these veins may get compressed by the tourniquet application for venous occlusion required for various purposes. The aberrant cubital venous anatomy should be considered while performing contrast venography for diagnosing venous malformation (8). Cubital venography is one of the preoperative procedures done in hemodialyzed patients for creating arteriovenous fistulas. Thus, the anatomical orientation of these peripheral veins becomes critical in these patients. Cephalic vein has also been used for creating arteriovenous fistulas and for achieving vascular access for hemodialysis (9). Basilic vein has been used for creating arteriovenous fistulas (10). Brachio-basilic fistulas are considered to be superior to the artificial grafts. Variability of brachio-basilic junction can lead to failure of subsequent graft transpositions. The basilic vein is more commonly considered appropriate for the above purpose as it has the appropriate measurements for hemodialysis and provides a substitute for graft prosthesis (11). The possibilities of creating arteriovenous fistulas at the wrist are limited by recurrent thrombophlebitis due to previous injections. Therefore, cubital veins are the better options for the above procedure (12). Depending upon the cubital venous variations, various types of fistula options have been described (13). The relationship of lateral and medial cutaneous nerves of forearm with the cubital venous anatomy is also important as they are prone to needle injury during venepuncture if the needle penetration breaches the plane of veins and reach the plane of nerves (14). Some reports have also shown these nerves passing superficial to the cubital veins (15). In both conditions, iatrogenic nerve injury may lead to complex regional pain syndrome causing shooting or burning pain in the limb (16). The factors responsible for complex regional pain syndrome

should be revised and should include not only improper technique of venepuncture but also the anatomical locations of accessible phlebotomy veins and underlying nerves. The present investigation revealed an unusual topography of two branches of lateral cutaneous nerve of forearm in relation to variant venous anatomy of the arm. Engorgement of ascending brachial vein could possibly lead to neurological symptoms because of pressure exerted on the underlying MLCNF.

Cephalic vein is easy to cannulate for giving intravenous injections due to relatively larger size (17). Cephalic vein has also been used for carotid patch after carotid endarterectomy instead of saphenous vein which therefore can be spared for further cardiovascular procedures. This patch is cheaper and less prone for bacterial contamination (18). The infrainguinal arterial reconstructions are frequently done and apart from the use of autogenous saphenous vein conduits (19), the use of cephalic vein has been proposed in case great saphenous vein is absent (25-50%) (20). Further, the authors speculate that the ascending brachial vein and its two tributaries as encountered in the present case could serve as an extra available channel for performing various cardiovascular operations.

Admittedly, clinical history of the individual was not available for corroborating the findings of the present report. Nevertheless, relevant clinical data on venous and nervous arrangement of upper extremity can be obtained by performing cadaveric studies such as the present one.

Conclusion

Recognition and awareness of variations pertaining to cubital venous anatomy is vital for surgeons as it may reduce the iatrogenic bleeding during forearm surgeries. A thorough and extensive knowledge of cubital vein variations also promotes a safer venepuncture by clinicians and ensures safer surgical options for the radiologists, cardiovascular and orthopaedic surgeons.

References

1. Standring Susan, Gray's anatomy- The anatomical basis of clinical basis. 39th ed. Philadelphia: Elsevier Churchill Livingstone, 2005, pp- 857-8.
2. Del Sol M, Mardones LM, Bustos JE. Venous formations in the cubital fossa of Mapuche. Bioscopy study. *Int J Morph* 2007; 23: 885-4.

3. Moore KL, Persaud TVN, Torchia MG. The Developing Human-Clinically Oriented Embryology. 8th ed. Philadelphia, PA: Saunders/Elsevier, 2008, pp-371.
4. Kumar N, Aithal AP, Rao MK, Nayak SB. The venous chiasma between the basilica vein and the brachial vein: a case report. *J Clin Diagn Res* 2012; 6(9): 1539-40.
5. Bergman RA, Thompson SA, Afifi AK, Saadeh FA. Compendium of Human Anatomic Variation: Catalogue, Atlas, and World Literature. Baltimore, Munich: Urban and Schwarzenberg, 1988, pp-90-1.
6. Reid CD, Taylor GI. The vascular territory of the acromioclavicular axis. *Br J Plast Surg* 1984; 37(2): 194-212.
7. Le Saout J, Vallee B, Person H, Doutriaux M, Blanc J, Nguyen H. Anatomical basis for the surgical use of the cephalic vein. *J Chir (Paris)* 1983; 120(2): 131-4.
8. Harasawa H, Yamazaki C, Kobayashi M, Takeyama H, Asano M, Masuko K. Utility of venography in shunt surgery on hemodialyzed patients. *Nephron* 1991; 57(2): 167-74.
9. Brescia MJ, Cimino JE, Appel K, Hurwich BJ. Chronic hemodialysis using venipuncture and a surgically created arteriovenous fistula. *N Engl J Med* 1966; 275(20): 1089-92.
10. IVascular Access 2006 Work Group. Clinical practice guidelines for vascular access. *Am J Kidney Dis* 2006; 48(Suppl 1): S176-247.
11. Lazarides MK, Georgiadis GS, Papisideris CP, Trellopoulos G, Tzilalis VD. Transposed brachial-basilic arteriovenous fistulas versus prosthetic upper limb grafts: a meta-analysis. *Eur J Vasc Endovasc Surg* 2008; 36(5): 597-601.
12. Burdick JF, Maley WR. Update on vascular access for hemodialysis. *Adv Surg* 1996; 30: 223-32.
13. Alamshah SM. Cephalic vein anatomy in antecubital fossa during the construction of arteriovenous fistula. *Acta Medica Iranica* 2004; 42(3): 218-22.
14. Horowitz SH. Peripheral nerve injury and causalgia secondary to routine venipuncture. *Neurology* 1994; 44(5): 962-4.
15. Yamada K, Yamada K, Katsuda I, Hida T. Cubital fossa venipuncture sites based on anatomical variations and relationships of cutaneous veins and nerves. *Clin Anat* 2008; 21(4): 307-13.
16. Horowitz SH. Venipuncture-induced causalgia: anatomic relations of upper extremity superficial veins and nerves, and clinical considerations. *Transfusion* 2000; 40(9): 1036-40.
17. Vialle R, Pietin-Vialle C, Cronier P, Brillu C, Villapadierna F, Mercier P. Anatomic relations between the cephalic vein and the sensory branches of the radial nerve: How can nerve lesions during vein puncture be prevented? *Anesth Analg* 2001; 93(4): 1058-61.
18. Khan RSA, Simms M. Cephalic vein for carotid patching. *EJVES Extra* 2005; 9: 35-6.
19. Kunlin J. Long vein transplantation in treatment of ischemia caused by arteritis. *Rev Chir* 1951; 70(7-8): 206-36.
20. Seeger JM, Schmidt JH, Flynn TC. Preoperative saphenous and cephalic vein mapping as an adjunct to reconstructive arterial surgery. *Ann Surg* 1987; 205(6): 733-9.