

Case Report

EXIT Llyod Davies

Mohd Faizal A¹, Vijayan V¹, Sandhya MM², Noor Shahieddah F³, Vinod S³, Tan LK³, Soon R¹

Department of Obstetrics and Gynaecology¹, Department of Radiology², Department of Anesthesia & Intensive Care Unit³, Sabah Women and Children Hospital (SWACH), P.O.Box 187, 88996 Kota Kinabalu, Sabah, Malaysia.

Abstract

The EXIT (Ex utero intrapartum treatment) procedures have been, with a high degree of success, employed to treat a myriad types of fetal airway obstruction most commonly neck masses such as cystic hygroma and lymphangioma with ample plan including prenatal diagnosis by ultrasound scan or MRI. Before the advent of EXIT, formal documentations had been published with descriptions of intubation during intrapartum period and fetal airway protection either during normal or operative delivery. We report a 28-year-old gravida 2 para 1 who was referred to our Maternal Fetal Medicine (MFM) unit at 26 weeks and 3 days gestation with a foetal neck mass. We present a case of an successful EXIT procedure performed in the Lloyd Davies position with the hips abducted and flexed at 15 degrees as is employed during gynecologic laparoscopy surgery minus the Trendelenburg tilt. Both mother and baby are well. The benefits of this position are discussed.

Keywords: EXIT procedure, Llyod Davies, congenital high airways obstruction, prenatal imaging

Correspondence:

Mohd Faizal Ahmad, Department of Obstetrics and Gynecology, Sabah Women and Children Hospital, P.O.BOX 187, 88996 Kota Kinabalu Sabah, Malaysia. Tel: 088-522600 Fax: 088-438512 Email: faizal.hwks@gmail.com

Date of submission: 19 June, 2014

Date of acceptance: 9 Jan, 2015

Introduction

The EXIT (Ex utero intrapartum treatment) procedures have been, with a high degree of success, employed to treat a myriad types of fetal airway obstruction most commonly neck masses such as cystic hygroma and lymphangioma with ample plan including prenatal diagnosis by ultrasound scan or MRI (1). Before the advent of EXIT, formal documentations had been published with descriptions of intubation during intrapartum period and fetal airway protection either during normal or operative delivery (2). Most authors' on EXIT procedures describe the procedure during caesarian section with patient in the usual supine with slight left lateral pelvic tilt (3). We present a case of an EXIT procedure performed in the Lloyd Davies position with the hips abducted and flexed at 15 degrees as is employed during gynecologic laparoscopy surgery minus the Trendelenburg tilt. The benefits of this are discussed.

Case Report

A healthy 28-year-old gravida 2 para 1 was referred to our Maternal Fetal Medicine (MFM) unit at 26 weeks and 3 days gestation with a fetal neck mass. She had no medical or surgical history. Her last childbirth was 2 years prior and it ended in a spontaneous term delivery of a healthy girl weighing 2600 g at birth. A detailed ultrasound examination of the fetus confirmed an isolated left sided avascular cystic mass of 6 cm x 3.5 cm in size. The mass did not extend beyond midline or the cranium and face above. No other abnormalities were seen. An amniocentesis was performed and confirmed aneuploid foetus. Serial ultrasound examination showed proportionately static tumour size with no evidence of thoracic inlet obstruction and no growth impairment. The liquor volume index was normal and stomach bubble was visualized on each subsequent visit. There was no evidence of high output cardiac failure in the foetus.

A magnetic resonance imaging (MRI) scan was performed at 33 weeks to define the lesion and predict airway obstruction. In this case, the foetus was in cephalic position. There was a multiloculated lesion measuring 11.5 x 9.5 x 8.2 (cm) on left side of neck causing right lateral flexion of neck. Radiological features were characteristic of macrocystic variety of lymphangioma /cystic hygroma extending from the level of left pinna to upper thoracic wall. Three major indirect signs of tracheal and oesophageal obstruction, polyhydramnios, small stomach bubble and prominent oropharynx, were absent. There was a prominent oropharynx. The trachea was displaced to the right. It had a luminal diameter of 2.5 mm compared to the normal tracheal diameter of 5-6 mm³.

A joint meeting with the Pediatric Surgeon, Neonatologist and Maternal Foeto-medicine Consultant was made. It was decided that the risk of airway obstruction was significant and the EXIT procedure was justified. A caesarean section and EXIT procedure was scheduled at 37 weeks gestation. Patient was assessed one day prior to operation day and she was classified as ASA 1 (American Society of Anesthesiologists) status. She was counseled for a general anesthetic with a possibility of massive blood loss and transfusion. She received premedication for acid reflux prophylaxis. Standard monitoring was performed. She was induced with rapid sequence induction after administration of 100% oxygen. Oral intubation was performed with a size of 7.0-mm endotracheal tube. At commencement of hysterotomy the sevoflurane was increased to MAC 2.0 and the Fio2 was 1.0. The MAP (mean arterial blood pressure) for this patient was maintained as normal level as possible within 55 and 65 mm Hg by giving 6mg of Ephedrine and 100mcg of phenylephrine. An amount of 10mg of Morphine was given in titrated dose prior delivery of baby.

A pfannenstiell abdominal incision was made for access and transverse lower-uterine-segment incision was performed with care not to prematurely rupture the amniotic membrane. Hemostatic sutures were placed at the angles and bleeding points along the uterine incision. Amniotomy was performed after hemostasis was secured. Delivery of the foetal head was facilitated with forceps without fundal pressure. The foetus was delivered up to mid chest. The left arm was delivered to facilitate oxygen saturation monitoring and an intravenous access was established. Oxygen saturation was 95% under room air. There was a continuous warmed saline infusion in utero to maintain uterine distention and avoid cord compression. With the legs abducted, the maternal pubis acted perfectly as a neck rest causing slight extension to facilitate endotracheal intubation. The foetus was given intramuscular 100 mcg of atropine and 10 mcg of fentanyl. The Pediatric Anesthetist attempted intubation. The glottis was visualized by laryngoscopy. It was not feasible to insert the endotracheal tube under neither direct vision nor bougie guide due to compression of trachea beyond vocal cords. About 130ml of contents of the cystic swelling was drained. The second attempt to intubate the foetus using an uncuffed size of 3.0-mm endotracheal tube was successful. ETCO2 monitoring was connected to T-Piece to have the precise position of the endotracheal tube determined. The foetus was then delivered and the infant was brought to the newborn resuscitation table, attended by paediatric team. The cord umbilical artery pH was 7.218 with BE -5.4 at completed delivery.

After the baby was delivered, she was given 5 international units of syntocinon intravenously. The sevoflurane concentration was decreased to 0.8 MAC. Right after the surgery, a Transversus Abdominis Plane

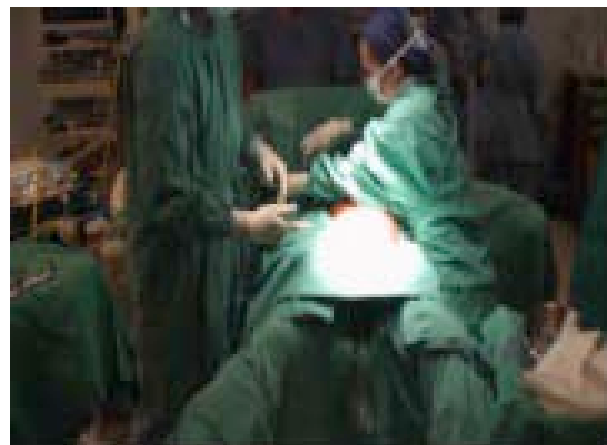
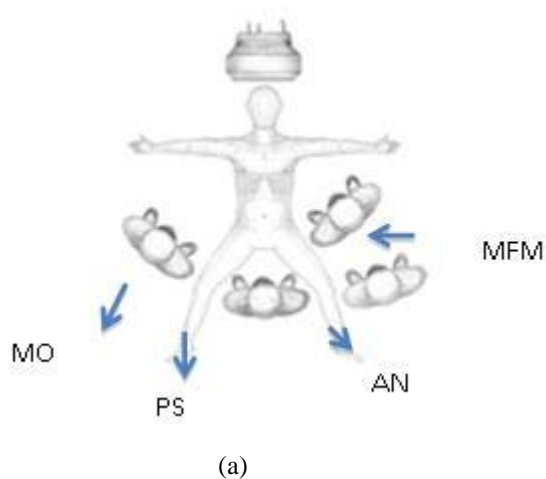


Figure 1: (a) Pediatric standby (PS), Maternal Fetus Medicine (MFM), Anesthetist (AN), Medical Officer (MO). (b) Actual picture.

(TAP) block was done using 25G spinocan by giving 5mg of levobupivacaine was given. Then anesthesia was stopped and she was extubated uneventfully. For 40 minutes she remained in the postoperative care unit and then was sent to the postnatal ward. The estimated blood loss was 600 ml. The baby were then had the hygromatous lesion excised and is currently thriving well.

Discussion

EXIT procedure will always remain controversial because of the difficulty in predicting fetal airway obstruction. Uterine relaxation requires general anesthesia and this increases the hemorrhage risk. In this case, prenatal assessments did not suggest airway obstruction as liquor volume was always normal and stomach bubble always visualized on serial ultrasound

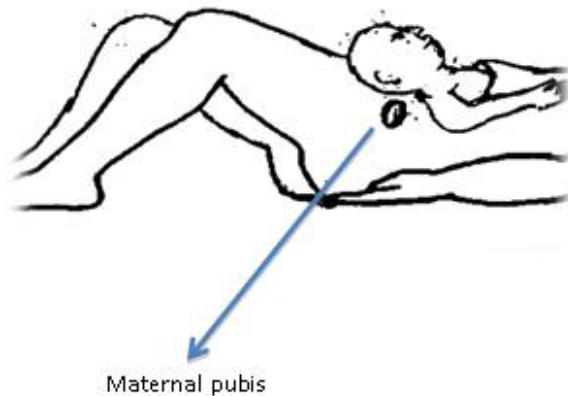


Figure 2: Maternal pubis affecting neck extension in Llyod Davies to secure the airway

scans. The readily visible glottis was also not an indicator of ease of airway intubation. Laryngo-broncho-malacia is not predictable prenatally.

In the literature review by Stevens et al. (2) 27 cases have been described in literature on EXIT up to 2002 but none gave importance to maternal positioning during EXIT. Johnson et al. (4) were first to report in 2008 the usage of Lloyd Davies position. The Lloyd Davies (low lithotomy) position was adopted to allow for an extra team to access to the operating table. This is illustrated in Figure 1(a) & (b).

The Llyod Davies position allowed for third access point into the operating field. This did not obstruct the position of surgeon and neonatologist involved with monitoring the neonate. The lag interval of this procedure was reported to be around 4-60 mins (4). In our case, the procedure was completed within 15 minutes. Upon delivery we found that the fetal neck naturally rested on maternal pubis affecting a neck extension (Fig. 2). This facilitated the task of the paediatricanaesthetist (PA) to secure airway.

Key deciding factor for EXIT is fetal airway compromise assessed by tracheal compression and Tracheo Esophageal Displacement Index (TEDI) (5). TEDI is defined on fetal MRI as sum of the lateral (L) and ventral (V) displacements (in millimeters) of tracheoesophageal complex from its normal anatomical location at the ventral aspect of the cervical spine. L+V values greater than 12mm predict complicated airway at birth. The TEDI for this fetus was 29.5mm (L+ V =16.8+ 12.7) (6). The MRI image of this lesion and airway assessment was shown in Figure 3.

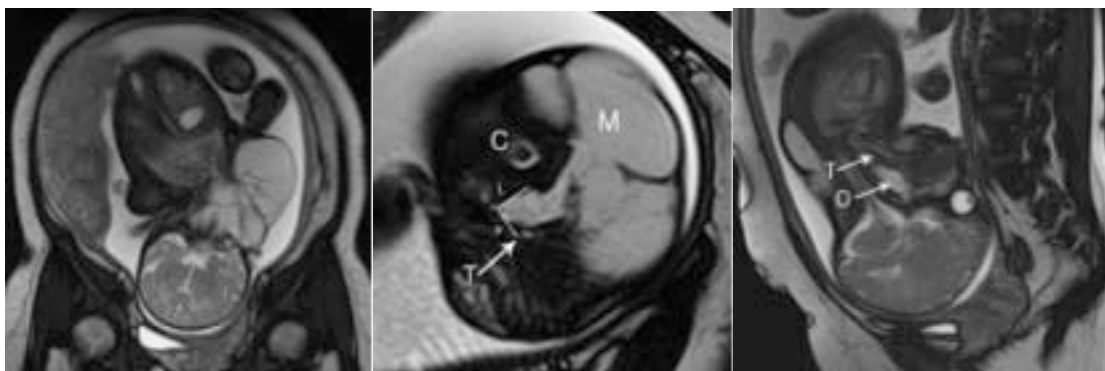


Figure 3 (a): Ultrafast MRI /ssfp coronal images of the fetus demonstrates cystic hygroma on the left side of the neck and right lateral flexion of the fetal neck. Note the placenta in the upper segment on the right lateral wall. (b) Ultrafast MRI /ssfp axial images of the fetus demonstrating the displacement of trachea(white arrow, T) by mass (M) and trachea-esophageal displacement index (TEDI). TEDI is defined on fetal MRI as sum of the lateral (L) and ventral (V) displacements (in millimeters) of tracheoesophageal complex (T) from its normal anatomical location at the ventral aspect of the cervical spine (c).

Conclusion

This case report serves as additional evidence for EXIT procedure using the Lloyd Davies position, which allowed for third access point into the operating field. This did not obstruct the position of surgeon and neonatologist involved with monitoring the neonate and give better benefit compared to lithotomy position.

References

1. Hirose S, Harrison MR. The ex utero intrapartum treatment (EXIT) procedure. *Semin Neonatol* 2003; 8(3): 207-14.
2. Stevens GH, Schoot BC, Smets MJ, et al. The ex utero intrapartum treatment (EXIT) procedure in fetal neck masses: a case report and review of literature. *Eur J Obstet Gynecol Reprod Biol* 2002; 100(2): 246-50.
3. Bilgin F, Cekmen N, Ugur Y, Kurt E, Güngör S, Atabek C. Congenital Cervical Teratoma: Anesthetic Management (The EXIT Procedure). *Indian J Anaesth* 2009; 53(6): 678-82.
4. Johnson N, Medd L, Shah PS, et al. A challenging delivery by EXIT procedure of a fetus with a giant cervical teratoma. *J Obstet Gynaecol Can* 2009; 31(3): 267-71.
5. Dighe KD, Peterson SE, Dubinsky TJ, Perkins J, Cheng E. EXIT procedure: technique and indications with prenatal imaging parameters for assessment of airway patency. *Radiographics* 2011; 31(2): 511-26.
6. Griscom NT, Wohl ME. Dimensions of growing trachea related to age and gender. *AJR Am J Roentgenol* 1986; 146(2): 233-7.