

## Case Report

# Higher and Bulkier Origin of the Lumbricals and their Clinical Relevance

Sushma RK, Chandni G, Bhat KMR (✉)

Department of Anatomy, Kasturba Medical Collage, Manipal University, Manipal-576104, Karnataka, India

### Abstract

Lumbricals are important small intrinsic muscles of the hand, which arise from the tendons of the flexor digitorum profundus in the palm distal to the flexor retinaculum and are inserted on to the dorsal digital expansion. Variations in the unipennate/bipennate pattern of lumbricals, absence of one or more muscles, origin from the superficial flexor tendons and flexor retinaculum have been reported earlier. In the present case, all four lumbricals were arising from the tendons of the flexor digitorum profundus, proximal to the flexor retinaculum in the anterior part of the forearm and extending into the palm through the carpal tunnel. However, there was no variation found with regard to their normal unipennate (first two) and bipennate (last two) pattern of origin. In the palm all the four lumbricals were found to be bulkier than their normal size, first one being the bulkiest. The bulky and high origin of lumbricals within the carpal tunnel makes the tunnel a compact space. Therefore, such variation is one of the predisposing factors for the carpal tunnel syndrome. Thus, the knowledge of such variant origin of lumbricals is helpful not only during carpal tunnel release but also during the magnetic resonance imaging (MRI) and ultrasound based diagnosis of carpal tunnel and during the flexor tendon repair and reconstruction.

**Keywords:** Lumbricals, carpal tunnel syndrome, flexor digitorum profundus, flexor retinaculum, compression

### Correspondence:

Dr. Kumar MR Bhat, Department of Anatomy, Kasturba Medical Collage, Manipal University, Manipal-576104, Karnataka, India. Tel no: +91-820-2922327 Fax: +91-820-2570061 Email: kumar.mr@manipal.edu

Date of submission: 6 Nov, 2012

Date of acceptance: 26 Feb, 2013

### Introduction

Lumbricals are four small muscles which arise from the tendons of flexor digitorum profundus. The first and the second lumbricals originate from the radial side and palmar surfaces of the profundus tendons for the index and the middle fingers, respectively. The bipennate third and fourth lumbricals arises from the profundus tendons of the middle-ring fingers and ring-little fingers respectively. After their origin, each muscle passes to the radial side of the corresponding fingers and inserts on to the lateral margin of the dorsal digital expansion of extensor digitorum tendon. Rarely, the accessory slips from the lumbricals may attach to the nearby flexor digitorum superficialis tendon (1).

There are many reports to show the variations in the origin of the lumbricals. Any of them can be

unipennate or bipennate, may be reduced to three or even to two muscles and in rare instances all four lumbricals may be absent or may contain accessory slips. The origin of one or more lumbrical muscle may be from the flexor retinaculum and from the superficial flexor tendon (2). Further, first lumbrical was shown to have an additional belly arising from the tendon of the flexor digitorum superficialis to the index finger (3), two lumbricals having origin from the flexor digitorum profundus tendons and other two from the tendons of the flexor digitorum superficialis at the proximal bored of the flexor retinaculum (4), tendons of flexor digitorum superficialis of index finger giving rise to the lumbricals and passing through carpal tunnel (5), rare case of bipennate first lumbrical muscle with origin from the flexor digitorum profundus in the hand distal to the flexor retinaculum (6), abnormal origin of the lumbrical muscle from the transverse carpal ligament (7) have been reported. It

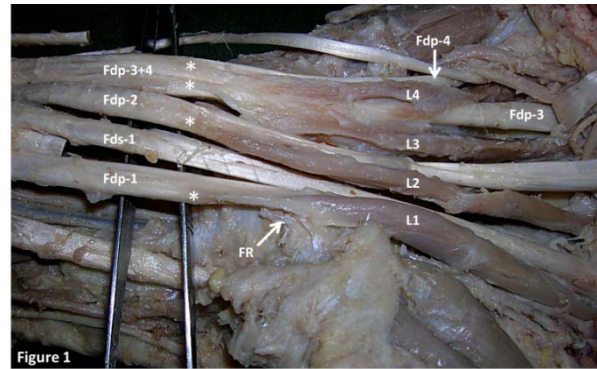
has been reported that only 16% of lumbricals have the text book pattern of attachments. The third lumbrical muscle has been shown to have greatest variation in attachments (45.3%) and the second lumbrical has been shown to have an additional forearm originating from the FDP (2.7%) (8). However, in another study, the third lumbrical muscle is found arising more proximally than usual from the FDP tendon (9). Here, we report a rare case of all four lumbricals having higher origin and all being bulkier in their size with clinical emphasis.

### Case Report

During routine dissection for the undergraduate course in Kasturba Medical College, Manipal, in a 62-year-old male cadaver, we observed that, all four lumbricals were much bulkier than the normal size and were arising from the tendon of the flexor digitorum profundus proximal to the flexor retinaculum. Their origin from the profundus tendon was extending into the front of the forearm and also in the carpal tunnel. Normally, the average length of a lumbrical muscle is about 5-6cm. However, because of the higher origin, all four lumbricals in the present case had an average length of 11-12cm. All the four lumbricals were found to pass deep to the flexor retinaculum, through the carpal tunnel along with their respective profundus tendon before they reach the palm. The first two lumbricals were unipennate and next two were bipennate in origin as usual. The first lumbrical was most bulky and the size was decreased gradually towards the 4th lumbrical muscle. In addition, we also observed a single tendon of the flexor digitorum profundus for the ring and the little finger under the flexor retinaculum and the 3rd and 4th lumbricals arising from its superficial surface (Fig. 1). Then, this common tendon was split into two near the distal palmar crease for the respective fingers. The pattern of insertion and nerve supply and were found normal for all the four lumbricals.

### Discussion

Fine and accurate finger motion and incredible versatility depends on the balance and co-ordination between the actions of the intrinsic muscles of the hand. The hand is among the most frequently injured parts of the body and an appreciation and understanding of its complex normal and abnormal anatomy is important to handle functional assessment, repair, and reconstruction. Since lumbricals have origin from the deep flexor tendons and inserted to the extensor tendon which inserts on to the phalanges, the action of these muscle in the human finger is difficult to visualize (10). Moreover, variations in the site of origin of the lumbricals from the profundus tendons



**Figure 1:** Unusually bulkier lumbricals (L1–L4) were originating (\*) from the corresponding tendons of the flexor digitorum profundus (Fdp1- Fdp4), extending from the forearm and under the flexor retinaculum (FR). The profundus tendons for ring and the little finger were found to be single (Fdp3+4) and separated into two tendons near the distal palmar crease. The third and the fourth lumbricals arose from this common tendon. Fds1=first tendon of the flexor digitorum superficialis.

may also be important in treating the spontaneous intratendinous /closed flexor tendon ruptures (11,12). High origin of lumbricals within the carpal tunnel can further reduce the space in the carpal tunnel and can cause or aggravate the carpal tunnel syndrome (13,14). These types of abnormal bulkier muscles are worth considering while measuring the lumbrical muscle strength to assess the severity of the ulnar nerve/brain damage (15,16). It has also been observed that, the patients with idiopathic carpal tunnel syndrome, the lumbrical muscles originated more proximal in the canal and younger patients whose jobs required repetitive hand motions have shown to have large lumbrical muscles originating more proximal than the lumbricals found in the hands of fresh cadavers (17).

### Conclusion

Thus, the present rare finding of all the lumbricals being bulkier and having high origin within the carpal tunnel may be important in many radiological and ultrasound based diagnosis and worth considering during carpal tunnel release surgeries, tendon repairs, wrist joint repair and may also explain the uncommon symptoms and signs in the hand.

### References

1. Standring S. Gray's Anatomy-The anatomical basis of clinical practice. Philadelphia: Elsevier Churchill Livingstone, 2005, pp- 848.
2. Bergman RA, Thompson SA, Afifi AK, Saadeh FA. Compendium of human anatomic variations. Urban & Schwarzenberg: Baltimore-Munich; 1988, pp-17

3. Nayak SR, Rathan R, Chauhan R, Krishnamurthy A, Prabhu LV. An additional muscle belly of the first lumbrical muscle. *Cases J* 2008;1(1):103.
4. Potu BK, Gorantla VR, Rao MS, et al. Anomalous origin of the lumbrical muscles: a study on South Indian cadavers. *Morphologie* 2008;92(297):87-89
5. Koizumi M, Kawai K, Honma S, Kodama K. Anomalous lumbrical muscles arising from the deep surface of flexor digitorum superficialis muscles in man. *Ann Anat* 2002; 184(4):387-392.
6. Singh G, Bay BH, Yip GW, Tay S. Lumbrical muscle with an additional origin in the forearm. *ANZ J Surg* 2001; 71(5):301-302.
7. Minami A, Sakai T. Camptodactyly caused by abnormal insertion and origin of lumbrical muscle. *J Hand Surg Br* 1993; 18(3):310-311.
8. Mehta HJ, Gardner WU. A study of lumbrical muscles in the human hand. *Am J Anat* 1961; 109: 227-238.
9. Eriksen J. A case of carpal tunnel syndrome on the basis of an abnormally long lumbrical muscle. *Acta Orthop Scand* 1973; 44(3):275-277.
10. Leijnse JN, Kalker JJ. A two-dimensional kinematic model of the lumbrical in the human finger. *J Biomech* 1995; 28(3):237-249.
11. Naam NH. Intratendinous rupture of the flexor digitorum profundus tendon in zones II and III. *J Hand Surg Am* 1995; 20(3):478-483.
12. Coombs CJ, Mutimer KL. Closed flexor tendon rupture in the palm: an unusual but predictable clinical entity. *Aust NZJ Surg* 1993; 63(11):910-913.
13. Asai M, Wong AC, Matsunaga T, Akahoshi Y. Carpal tunnel syndrome caused by aberrant lumbrical muscles associated with cystic degeneration of the tenosynovium: a case report. *J Hand Surg Am* 1986; 11(2):218-221.
14. Weiland W, Lanz U. An unusual cause of carpal tunnel syndrome. *Handchirurgie* 1979; 11(3-4):169-171.
15. Schreuders TA, Stam HJ. Strength measurements of the lumbrical muscles. *J Hand Ther* 1996; 9(4):303-305.
16. Palmer DT, Horn LJ, Harmon RL. Botulinum toxin treatment of lumbrical spasticity: a brief report. *Am J Phys Med Rehabil* 1998; 77(4):348-350.
17. Siegel DB, Kuzma G, Eakins D. Anatomic investigation of the role of the lumbrical muscles in carpal tunnel syndrome. *J Hand Surg Am* 1995; 20(5):860-863.