

## Isolation of *Mycobacterium fortuitum* in sputum specimens of a patient with chronic cough: Is it clinically significant?

Radzniwan MR, Tohid H, Ahmad S, Mohd Ali F, Md Anshar F

Radzniwan MR, Tohid H, Ahmad S, Mohd Ali F, Md Anshar F. Isolation of *Mycobacterium fortuitum* in sputum specimens of a patient with chronic cough: Is it clinically significant? *Malays Fam Physician*. 2014;9(3):38-41.

### Keywords:

chronic cough, nontuberculous mycobacterium, *Mycobacterium fortuitum*, sputum culture, primary care

### Authors:

#### Hizlinda Tohid

(Corresponding author)  
MMed (FamMed)  
Department of Family Medicine,  
Universiti Kebangsaan Malaysia  
Medical Centre, Jalan Yaacob Latiff,  
Bandar Tun Razak, Cheras 56000,  
Kuala Lumpur, Malaysia  
Email: hizlinda2202@gmail.com

#### Radzniwan Mohd Rashid

MMed (FamMed)  
Department of Family Medicine,  
Universiti Kebangsaan Malaysia  
Medical Centre  
(UKMMC), Cheras, Kuala Lumpur,  
Malaysia

#### Saharuddin Ahmad

MMed (FamMed)  
Department of Family Medicine,  
Universiti Kebangsaan Malaysia  
Medical Centre (UKMMC), Cheras,  
Kuala Lumpur, Malaysia

#### Fairuz Mohd Ali

MMed (FamMed)  
Department of Family Medicine,  
Universiti Kebangsaan Malaysia  
Medical Centre (UKMMC), Cheras,  
Kuala Lumpur, Malaysia

#### Fauzi Md Anshar

MRCP, FCCP  
Prince Court Medical Centre, Kuala  
Lumpur, Malaysia

### Abstract

Managing chronic cough is diagnostically challenging especially in primary care. This case report highlights the difficulties experienced in approaching a case of chronic cough from a primary care perspective. The discussion also involves the clinical significance and treatment dilemma of *M. fortuitum chelonae complex* that was isolated from the sputum cultures of an elderly woman who presented with chronic cough for more than a year.

### Introduction

Chronic cough, defined as cough lasting for more than 8 weeks, is one of the most common presenting complaints in primary care.<sup>1,2</sup> The impact of this malady on patients is diverse, ranging from trivial inconveniences to significantly impairing the sufferers' wellbeing. In western countries, the pathologic triad, asthma, gastroesophageal reflux disease (GERD), and upper airway cough syndrome (UACS), are prevalent. However, in Asian countries, virulent infections such as pulmonary tuberculosis (PTB) should be the main concern, especially among people who are immune-compromised, elderly, have close contact with other PTB patients and living in overcrowded settlement.<sup>2,3</sup> According to the Malaysian TB clinical practice guideline, anyone with cough for more than 2 weeks should be assessed for PTB.<sup>4</sup>

Apart from PTB, nontuberculous mycobacteria (NTM) such as *Mycobacterium avium complex* (MAC), *M. kansasii*, and *M. fortuitum* affecting the lungs may present as chronic cough.<sup>5</sup> The aim of this case report is to highlight the management dilemma after isolating NTM from the sputum cultures of an elderly woman investigated for chronic cough.

### Case Summary

An 82-year-old Chinese lady, a nursing home resident, came to a primary care clinic for her follow-up appointment. She had multiple underlying co-morbidities including type 2 diabetes mellitus, hypertension, ischaemic heart disease, complete heart block and heart failure with preserved ejection fraction

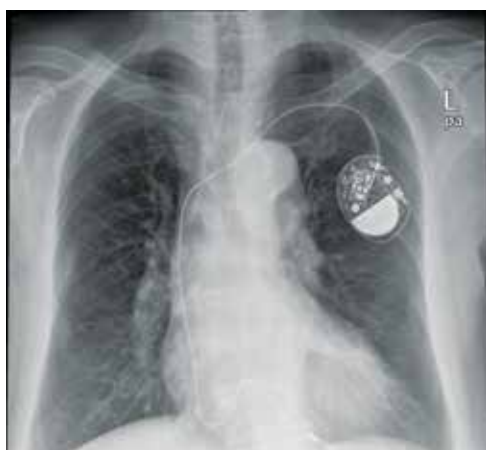(HFPEF). During this visit, the patient complained of persistent mild cough with whitish sputum for the past 1 year. There were no diurnal variations or triggering factors. She denied having fever, night sweats, loss of appetite, haemoptysis and symptoms of UACS and GERD. There was no history of contacts with TB patients. She had never smoked before.

Previously, she had her angiotensin-converting enzyme inhibitor (ACE-I) for her hypertension substituted with an angiotensin receptor blocker (ARB). She also had 1-month trial of proton pump inhibitors. Despite these interventions, her cough persisted.

Clinically, she was not in respiratory distress. She had no pallor or lymphadenopathy. Her body mass index was 25 kg/m<sup>2</sup>. Her blood pressure was 122/66 mm-Hg and pulse rate was 68 beats/min. A BCG scar was present on her left deltoid. Apart from bilateral mild pedal oedema, examinations of other systems were unremarkable.

Investigations showed an ESR of 63 mm/h, WBC count  $7.4 \times 10^9/L$ , lymphocytes 31.7%, monocytes 4.3%, granulocytes 64%, haemoglobin 13.3 g/dL and platelet count  $285 \times 10^9/L$ . Chest radiograph showed evidence of cardiomegaly with a pacer in-situ. Other abnormalities were noted (Figure 1).

Tests for TB were carried out during her subsequent visits. However, all the three samples for direct sputum acid-fast bacilli (AFB) were negative.



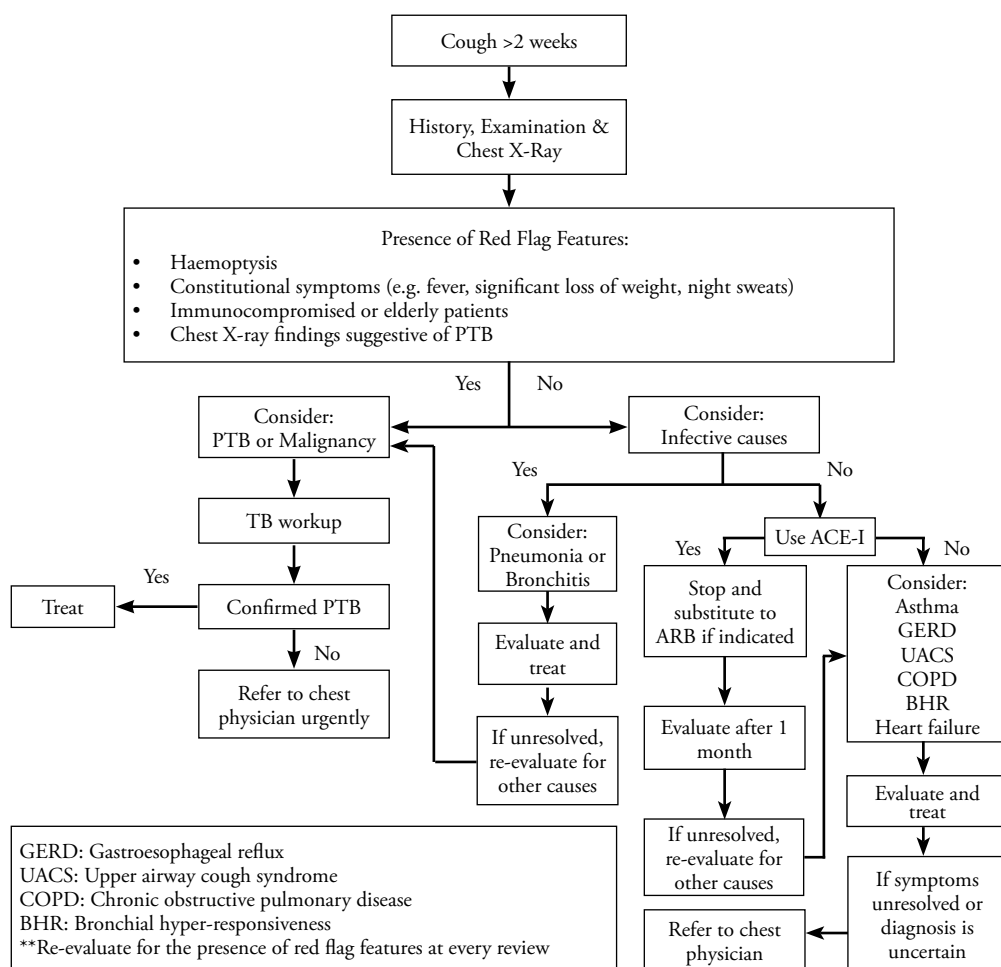
**Figure 1.** Chest radiograph of the patient

After 4 weeks, the culture grew atypical mycobacterium belonging to Runyon group IV (*M. fortuitum chelonae* complex). Subsequently, two more sputum samples were sent for culture and one of the cultures grew the same organism. A respiratory physician was consulted. He advised conservative treatment and not to commence anti-

tuberculosis treatment at that stage. The patient was put on close monitoring and was advised to return for the consultation if she develops new symptoms.

**Discussion**

Managing chronic cough in primary care begins with diagnosing the common causes, which allows the initiation of an effective treatment. (Figure 2). This also entails excluding significant diseases such as malignancy, lymphoma, PTB, bronchiectasis and sarcoidosis.<sup>1,6</sup> In the absence of clinical red flags such as fever, respiratory distress, significant weight loss and hemoptysis, the pathologic triad is high on the diagnostic list.<sup>1-3,6</sup> However, ACE-I induced cough should be suspected among users and its discontinuation is the initial consideration in chronic cough management.<sup>1,3,6</sup> The cough usually resolves after withdrawal within 1-4 weeks, but can be delayed up to 3 months.<sup>1</sup> If the cough persists, other causes of cough should be investigated.<sup>1,3,6</sup> It is important to note in the Malaysian setting, exclusion of PTB must be pursued (Figure 2).<sup>4</sup>



**Figure 2.** Approach to cough persisting for more than 2 weeks at the Primary Care Clinic, Universiti Kebangsaan Malaysia Medical Centre (UKMMC)

Although ARB could cause cough, the incidence is low and comparable to hydrochlorothiazide.<sup>7</sup> As this patient was taking aspirin which is a risk factor for GERD,<sup>8</sup> a trial of proton-pump inhibitor was commenced ('test of treatment' approach).<sup>6</sup> Persistence of cough after the trial likely suggests other etiologies.

Isolation of *M. fortuitum* in two of the three sputum cultures suggested that this could possibly be the cause of the patient's problem, although *M. fortuitum* pulmonary infection is uncommon.<sup>5</sup> It is more likely to cause cutaneous, soft tissue and disseminated infections.<sup>5,9</sup> Nevertheless, lung infections due to *M. fortuitum* have been reported in some studies causing pneumonia, lung abscess and empyema.<sup>10</sup> In Malaysia, *M. fortuitum* infection is not that uncommon. In a study, 26% of the sputum cultures grew *M. fortuitum*.<sup>11</sup> The prevalence had remained unchanged even after 2 decades.<sup>12</sup> However, the clinical significance of *M. fortuitum* infection was questioned by these studies as it is widely found in the environment.

Park, et al. (2008) reviewed 182 patients with positive respiratory specimen culture for *M. fortuitum*.<sup>13</sup> Only 14.2% had at least two positive cultures and most of these patients had significant chest radiographic abnormalities.<sup>13</sup> About one-third of them did not receive antibiotics because the isolation of *M. fortuitum* was considered insignificant.<sup>13</sup> This study supported the decision to follow a conservative approach in our patient whose chest radiograph did not reveal lung abnormalities.

The decision to treat still depends on the significant *M. fortuitum* growth, other positive investigation findings such as chest imaging and the patient's clinical signs and symptoms. According to the American Thoracic Society/ Infectious Disease Society of America (ATS/

IDSA), NTM lung disease can be diagnosed if *M. fortuitum* is isolated in two out of three sputum cultures, accompanying with pulmonary symptoms and abnormalities in the chest radiograph or high resolution computed tomography scan of thorax, together with appropriate exclusion of other diagnoses.<sup>5</sup> Isolation of *M. fortuitum* in respiratory specimen is considered clinically significant if these criteria are met or when it occurs in immunocompromised patients where treatment is warranted as the infection can cause severe complication such as disseminated disease.<sup>14</sup> Various antibiotics, including macrolides, quinolones and doxycycline, can be used under expert guidance.<sup>5</sup>

## Conclusion

Managing chronic cough in primary care should be approached systematically as aetiology is diverse. A holistic approach is crucial so as not to miss any significant cause. If *M. fortuitum* has been isolated from sputum specimens, treatment decision should be based on clinical symptoms and signs supported by significant investigation results. Referral to an experienced respiratory physician is required when management is in a doubt.

## Acknowledgments

We would like to thank Ms. Hilda, a volunteer who has been involved in the care of the patient and accompanied her to every clinic visit.

## Conflict of interest

None.

## Funding

None.

## References

1. Irwin RS, Baumann MH, Boulet LP, et al. Diagnosis and management of cough executive summary: ACCP evidence-based clinical practice guidelines. *Chest*. 2006;129:1S–23S.
2. Chung KF, Pavord ID. Chronic cough 1: Prevalence, pathogenesis, and causes of chronic cough. *Lancet*. 2008;371:1364–74.
3. Morice AH. Review series—chronic cough: Epidemiology. *Chron Respir Dis*. 2008;5:43–7.
4. Ministry of Health Malaysia. Clinical practice guideline: Management of tuberculosis (3rd edition). 2012.
5. Griffith DE, Aksmit T, Brown-Elliott BA, et al. An official ATS/IDSA statement: Diagnosis, treatment, and prevention of nontuberculous mycobacterial diseases. *Am J Respir Crit Care Med*. 2007;175:367–416.
6. Barraclough K. Diagnosis in general practice: Chronic cough in adults. *BMJ*. 2009;338:1267–9.

7. Dicipinigitis PV. Angiotension-converting enzyme inhibitor-induced cough: ACCP evidence-based clinical practice guideline. *Chest*. 2006;129(1 Suppl):169S–173S.
8. Ruzsniwski P, Soufflet C, Barthélémy P. Nonsteroidal anti-inflammatory drug use as a risk factor for gastro-oesophageal reflux disease: an observational study. *Aliment Pharmacol Ther*. 2008;28(9):1134–9.
9. Soo-Hoo TS. Mycobacterium fortuitum soft-tissue infection following intramuscular injection. *Clin Microbiol Newsl*. 1990;12(6):46.
10. Vadakekalam J, Ward MJ. Mycobacterium fortuitum lung abscess treated with ciprofloxacin. *Thorax*. 1991;46(10):737–8.
11. Khor SY, Jegathesan M. Isolation of atypical mycobacteria from clinical material in Malaysia. *Med J Malaysia*. 1983;38(2):158–160.
12. Ong CS, Ngeow YF, Yap SF, et al. Molecular identification of nontuberculous mycobacteria from clinical sources by hsp65 PRA and sequence analysis. *Int J Infect Dis*. 2008;12(Suppl 1):e322–e3.
13. Park S, Suh GY, Chung MP, et al. Clinical significance of Mycobacterium fortuitum isolated from respiratory specimens. *Respir Med*. 2008;102:437–42.
14. Smith MB, Schnadig VJ, Boyars MC, et al. Clinical and pathologic features of mycobacterium fortuitum infections: An emerging pathogen in patients with AIDS. *Am J Clin Pathol*. 2001;116:225–32.