

CASE REPORT

Pleomorphic Adenoma Originating from Submandibular Salivary Gland in an 8-year-old Girl: A Case Report.

Gani AN¹, Megat Shiraz MAR², Siti Aishah MA³, Norazizah M³, Mazita A¹, Sharifah NA³

Department of ¹Otorhinolaryngology, Head & Neck Surgery, ³Pathology, Faculty of Medicine, Universiti Kebangsaan Malaysia

² Columbia Asia Hospital, Puchong, Selangor.

ABSTRAK

Adenoma pleomorfik (PA) ialah neoplasma epitelium kelenjar liur yang membesar perlahan-lahan dan biasanya didapati pada kelenjar liur parotid. Ia jarang didapati pada kelenjar liur submandibular terutama pada kumpulan umur pediatrik. Pembedahan adalah rawatan pilihan. Satu kes PA pada pesakit perempuan Melayu berumur 8 tahun dibentangkan. Pemeriksaan klinikal menunjukkan bengkakan di bahagian submandibular kanan berukuran 2x2sm. Diagnosis adenoma pleomorfik (PA) dibuat melalui sitologi sedutan jarum halus. Pesakit menjalani pembedahan submandibulektomi tanpa komplikasi. Dua tahun selepas pembedahan, pemeriksaan susulan menunjukkan pesakit masih asimptomatik.

Kata kunci: adenoma pleomorfik, kelenjar submandibular, submandibulektomi.

ABSTRACT

Pleomorphic adenoma (PA) typically presents as a benign slow growing, painless neoplasm of the parotid gland. PA arising from the submandibular gland in the paediatric age group is rare. Surgical excision is the treatment of choice. A case of PA in an 8-year-old Malay girl is presented. Clinically she presented with a painless right submandibular mass measuring 2x2cm. A diagnosis of Pleomorphic adenoma was made on Fine Needle Aspiration Cytology (FNAC). She underwent submandibulectomy uneventfully. Postoperatively after two years follow up, she is asymptomatic.

Key Words: pleomorphic adenoma, submandibular gland, submandibulectomy

INTRODUCTION

Pleomorphic adenoma (PA) is characterized by great histological diversity and myoepithelial cells are considered responsible for production of the extracell-

ular matrix. It is the most common of all salivary gland neoplasms, accounting for 50-70% of benign parotid tumours. Salivary gland tumors are comparatively rare dis-

Address for correspondence and reprint requests: Dr Norhaslinda Abdul Gani, Department of Otorhinolaryngology, Faculty of Medicine, Universiti Kebangsaan Malaysia. Jalan Yaacob Latiff, Bandar Tun Razak, 56000 Cheras, Kuala Lumpur, Malaysia. Email: haslinda.gani@yahoo.com

orders in the paediatrics population, comprising of only 1% of all the head and neck tumours and less than 5% of all the salivary gland tumours (Bentz et al. 2000). We report an 8-year-old female with PA arising from the right submandibular gland.

CASE REPORT

An 8-year-old Malay girl presented with a swelling below the right mandible of 10 months duration. The swelling was persistent and not associated with pain, fever, loss of weight, loss of appetite or related to meals. There was no history of exposure or contact with tuberculosis.

Physical examination revealed a right submandibular mass measuring 2x2cm. The mass was non-tender, firm on palpation, with normal overlying skin. The mass was mobile and there was no cervical lymph node palpable. The floor of the mouth and Wharton's duct showed no abnormality. Other systemic examinations were unremarkable. Fine needle aspiration revealed cellular smears composed of a

mixture of epithelial and stromal components. The epithelial cells were arranged in loose sheets as well as singly distributed displaying plasmacytoid nuclei with bland nuclear chromatin and dense cytoplasm. The stromal component is composed of fibrillary chondromyxoid substance admixed with spindle-shaped mesenchymal cells (Figure 1). These cytological features are consistent with PA. Under general anesthesia, submandibulectomy was carried out. Intraoperative examination revealed a tumor measuring about 3x2cm originating from the inferior portion of the submandibular salivary gland. The superior portion of the gland was free of tumor. The tumour was easily separated from the adjacent tissue.

The histopathological examination showed a well-circumscribed and encapsulated mass composed of an admixture of epithelial, myoepithelial and stromal components. Marked keratinisation and squamous cell metaplasia were present (Figure 2). There were no necrosis, nuclear atypia, hyaline-sation, invasion of adjacent tissue or




Figure 1: FNA of pleomorphic salivary adenoma: smear shows cellular aspirate comprising of clusters of epithelial cells in myxoid stroma (Pap stain X100 magnification).

abnormal mitotic activity noted. Salivary acini were present at the surrounding area. The operative and histological findings indicated that the tumor was completely resected and was benign.

Postoperative recovery was uneventful. The patient is currently free from disease 24 months after surgery.

DISCUSSION

Salivary gland neoplasms are rare in children. Not all masses arising in a salivary gland represent tumours of glandular origin. The most common non-epithelial salivary gland tumors are hemangiomas (59.2%) followed by lymphangioma (27.5%) (Bentz et al. 2000). 85% of benign epithelial salivary gland tumours arise from the parotid gland and only 10% in the submandibular gland (Rapidis et al. 2004).

PA is the most common benign type and is found with high incidence in the submandibular glands, while muco-epidermoid carcinoma is the most common malignant epithelial salivary gland tumour found in

children (Cruz Perez et al. 2004). Most of these tumours occur in the second decade of life (Cruz Perez et al. 2004). This finding differs with Bentz's study (Bentz et al. 2000), which showed a mean age at presentation of 7.2 ± 0.7 years. Pleomorphic adenoma has a female predilection with a female : male ratio of 4.4:1, while malignant tumours affected both genders similarly (Cruz Perez et al. 2004).

While relatively rare, PA of the submandibular gland presents a therapeutic challenge in the paediatric population. PA typically presents as a slow growing and painless mass of salivary glands, with predilection for recurrence and risk of malignant transformation (Rodriguez et al. 2007). The incidence of malignancy frequently showed a correlation between the length of the history of the PA and the development of carcinoma. It has been reported that the risk of developing malignancy is about 1.5% up to 5 years and increases to 9.5% after more than 15 years (Seifert et al. 1991).

Besides the parotid and submandibular

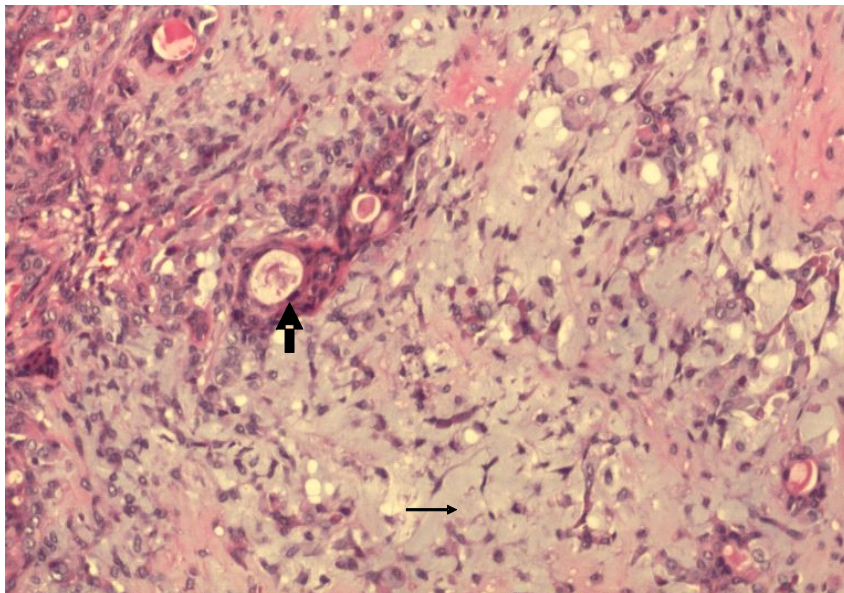


Figure 2: Pleomorphic salivary adenoma. Histological section shows epithelial components arranged in islands, acini and tubules in a background of myxochondroid stroma (thin arrow). The epithelial lining of the inner layer of the duct appears flattened with round to oval nuclei and variable amounts of eosinophilic cytoplasm (thick arrow). (Haematoxylin and Eosin X 100 magnification)

gland, PA also occurs at the palate (Lopez-Cedrun et al. 1996), trachea (Baghai-Wadji et al. 2006) and the lacrimal gland (Faktorovich et al. 1996).

Fine needle aspiration (FNA) biopsy establishes the diagnosis with good accuracy when sufficient specimen is obtained and a skilled pathologist is available (Rodriguez et al. 2004). The positive predictive value of FNA biopsy for PA was 99 % (Tew et al. 1997). However, in children, FNA often require sedation, and there is always the risk of insufficient material for diagnosis. Repeated biopsies or biopsies under computed tomography (CT scan) guidance may be necessary to establish the histological diagnosis. However, some paediatric patients like in this case can tolerate FNA without local anesthesia.

Ultrasonography is a well-tolerated method of evaluating salivary gland masses in children. The technique does not require sedation and does not expose the patient to irradiation. Boccato et al. (1998) advocated that ultrasound should be the first modality in the investigation of salivary gland masses in children, in view of differentiation between intra-glandular and extra-glandular lesions. They also concluded that vascular lesions could be seen clearly with the use of Doppler ultrasound.

CT scan and magnetic resonance imaging (MRI) complement clinical evaluation. CT scan requires shorter imaging time and provides excellent spatial resolution, even though it has limited soft tissue characterisation. MRI provides excellent soft tissue characterisation and has no exposure to irradiation, however, it is costly, is more time consuming and is more likely to require sedation in young children. Both modalities are useful in distinguishing between solid and cystic masses and differentiating lymph nodes from salivary gland tumours (Rodriguez et al. 2004). Imaging characteristics of a PA on MRI have typically been described as a well-circumscribed tumour that is hypointense or isointense to muscle on T1 and hyper-

intense on T2 (Rodriguez et al. 2004). An enhancing capsule on T1 imaging, with contrast and lobulation of the tumour are also predictive of PA (Ikeda et al. 1996).

Surgical excision is the most common diagnostic measure and is often therapeutic. Primary surgery determines the success or failure of the operation for PA of the submandibular gland, because every recurrence increases the risk for further recurrences (Rodriguez et al. 2004). The first operation should involve extirpating the entire gland which could minimize the risk of recurrence. Complications included tumour recurrence, transient and permanent marginal mandibular nerve weakness, ranula formation, postoperative fluid collection, and cellulitis (Hockstein et al. 2004). Untreated PA has a 2 to 25% risk of malignant change (Rodriguez et al. 2004).

CONCLUSION

A high index of suspicion is required for non-inflammatory lesions in the submandibular region to avoid undue delay in definitive treatment. Pleomorphic adenoma does occur in children although rare. Preoperative diagnosis with FNAC has proven to be highly accurate. We advocate surgical excision because of the young age group and the chances of malignant transformation later in life.

REFERENCES

- Baghai-Wadji, M., Sianati, M. & Nikpour, H. 2006. Pleomorphic adenoma of the trachea in an 8-year-old boy: a case report. *Journal of pediatric Surg.* **41**(8):23-26.
- Bentz, B.G., Hughes, C.A. & Ludemann, J.P. 2000. Masses of the salivary gland region in children. *Arch otolaryngol Head Neck Surg.* **126**:1435-1439.
- Boccato, P., Altavilla, G. & Blandamura, S. 1998. Fine-needle aspiration biopsy of salivary gland lesions. A reappraisal of pitfalls and problems. *Acta Cytol.* **42**: 888-898.
- Cruz Perez, D.E., Pires, F.R. & Alves, F.A. 2004. Salivary gland tumors in children and adolescents: a clinicopathologic and immunohistochemical study of fifty-three cases. *International Journal of Pediatric Otorhinolaryngology.* **68**:895-902.
- Faktorovich, E.G., Crawford, J.B. & Char, D.H. 1996. Benign mixed tumor (pleomorphic adenoma) of the lacrimal gland in a 6 year-old boy. *Am J Ophthalmol* **122**:446-447.
- Garcia-Perla, A., Munoz-Ramos, M. & Infante-Cossio,

- P. 2002. Pleomorphic Adenoma of the Parotid in Children. *Journal of Cranio-Maxillofacial Surgery* **30**:242-245.
- Hockstein, N.G., Samadi, D.S. & Gendron, K. 2004. Pediatric submandibular triangle masses: A fifteen-year experience. *Head Neck*. **26**(8): 675-680.
- Ikeda, K., Kato, T. & Ha-Kawa, S.K. 1996. The usefulness of MR in establishing the diagnosis of parotid pleomorphic adenoma. *Am J Neuroradiol* **17**:555-559.
- Laskawi, R., Ellies, M. & Arglebe, C. 1995. Surgical Management of Benign Tumours of the submandibular gland: a follow-up study. *J Oral Maxillofac Surg*. **53**:506-508.
- Lopez-Cedrun, J.L., Gonzalez-Landa & G., Birichinaga, B. 1996. Pleomorphic adenoma of the palate in children: Report of a case. *Int. J Oral Maxillofac Surg*. **25**:206-207.
- Rapidis, A.D., Stavrianos, S. & Lagogiannis, G. 2004. Tumors of the Submandibular Gland: Clinicopathological Analysis of 23 Patients. *J Oral Maxillofac Surg*. **62**:1203-1208.
- Rodriguez, K.H., Vargas, S. & Robson, C. 2007. Pleomorphic adenoma of the parotid gland in children. *Internal J of the Pediatric Otorhinolaryngology*. **71**:1717-1723.
- Seifert, G. & Sobin, L.H. 1991. *Histological Typing of Salivary Gland Tumors*. Ed 2. Geneva, Switzerland: Health Organization.
- Tew, S., Poole, A.G. & Philip, J. 1997. Fine-needle aspiration biopsy of parotid lesions: Comparison with frozen section. *Australia and New Zealand Journal of Surgery*. **67**(7):438-441