

## CASE REPORT

### Unilateral ovarian fibrothecoma with menorrhagia

Danendran KRISHNAN\*,\*\* MBBS, BMedSc, Komal KUMAR\*\* MBBS, BSc, and Anitha Ann THOMAS\*\*\* MD, FRCPA

\*Kalgoorlie Regional Hospital, Western Australia, \*\*King Edward Memorial Hospital for Women, Perth, Australia and \*\*\*PathWest QEII, Australia

#### Abstract

Ovarian fibrothecoma is a relatively new term that is used to describe an ovarian sex cord stromal tumour that has mixed features of both fibroma and thecoma. The prevalence of ovarian fibrothecoma tumours is very rare and is reported to be about 1.2% of all ovarian tumours. We report a case of a 32-year-old woman who presented with acute menorrhagia with no previous medical, surgical or gynecological history. She was amenorrhic for four years after the insertion of a levonorgestrel-releasing intrauterine system (LNG-IUS) for contraception. The efficacy and location of LNG-IUS was reflected due to the sudden onset of menorrhagia. On pelvic examination and ultrasound the LNG-IUS could not be visualized and a uterine fibroid was noted. A diagnostic laparoscopy was done to identify the LNG-IUS, which revealed an incidental large ovarian mass on the left ovary. CA-125 level was elevated to 45 kU/L (Normal range <35 kU/L). Total abdominal hysterectomy, left salpingo-oophorectomy and cystectomy were performed. On histopathology, the mass was proven to be an ovarian fibrothecoma. No signs of malignancy were noted on peritoneal fluid cytology. The LNG-IUS was found inside the uterus. Our case is reported on the basis of the rare incidence of ovarian fibrothecoma and the possible effect it may have on the efficacy of LNG-IUS causing menorrhagia.

**Keywords:** menorrhagia, LNG-IUS, pelvic mass, fibrothecoma

#### INTRODUCTION

Ovarian sex cord tumours are defined as tumours that arise from granulosa cells, theca cells, sertoli cells, leydig cells and fibroblasts of stromal origin.<sup>1</sup> The term 'fibrothecoma' of the ovary is a new term for a tumour of gonadal stromal cell origin and is very rare as it only accounts for 1.2% of all ovarian cancers.<sup>2</sup> Histologically, fibromas are composed of variable amounts of collagen from entirely spindle, oval or round cells. Thecomas resemble theca interna cells of the ovary and are composed of lipids. There is a large histological and immunohistochemical overlap between the two that resulted in the term 'fibrothecoma'.<sup>3</sup> The management of this type of tumour remains surgical and has good prognosis as they usually present as stage 1 lesions.<sup>4</sup> We would like to share a case of a patient who presented with acute menorrhagia four years after having cessation of menstruation following levonorgestrel-releasing intrauterine

system (LNG-IUS) insertion.

#### CASE REPORT

##### Presentation

A 32-year-old woman who was gravida 2 para 2 presented with continuous per vaginal (pv) bleeding for approximately two months. Obstetric history was significant for retained placental products after the second vaginal birth. The patient was treated with dilatation, suction and curettage of the uterus. A LNG-IUS was inserted for contraception purposes. In the past 4 years, the patient had no menstruation reflecting the efficacy of the LNG-IUS. She reported no dyspareunia or dysmenorrhoea. There was no other significant medical, surgical or gynaecological history.

On examination, there were no palpable abdominal masses. Bimanual pelvic examination revealed no lumps or adnexal tenderness. On speculum examination, the LNG-IUS string was not visualised. A trans-vaginal and trans-

abdominal bedside ultrasound of the pelvis was performed. The left ovary could not be visualized. A uterine fibroid was identified but the LNG-IUS was nowhere to be found. Hence, the patient had a diagnostic laparoscopy to locate the LNG-IUS. On laparoscopy a large left sided solid white ovarian mass was noted (Fig. 1). It was lobulated and was an outgrowth of the ovary (Fig. 2). Resection of the mass was delayed till further investigations. Full blood picture, urea and electrolytes, quantitative b-HCG, liver function tests and coagulation profile were unremarkable. Tumour markers were performed appropriately. The only significant positive tumour marker was CA-125, which was mildly elevated at 45 kU/L (Normal Range <35 kU/L). A week later, total abdominal hysterectomy and left salpingo-oophorectomy was performed. The ovarian mass was easily resected with no surgical complications and sent for histopathology. Peritoneal fluid was sent for cytology.

*Pathological findings*

Peritoneal fluid cytology showed no evidence of

malignancy or any form of cellular abnormality. The uterus was not enlarged, had a fibroid and a t-shaped intrauterine device was identified. The endometrium was 1mm in thickness and showed inactive glands with decidualised stroma and haemorrhage within the endometrial cavity. The myometrium was 15 mm in thickness and was unremarkable microscopically. The cervix showed foci of squamous metaplasia, mild non-specific chronic inflammation and nabothian cysts. The sections of left fallopian tube showed unremarkable plicae, inclusion cysts and paratubal cysts. An ovarian mass measuring 105 x 105 x 45 mm was noted and showed features of a fibrothecoma. It consisted of intersecting swathes of collagenous fibrous tissue with focal storiform pattern. The spindle-shaped fibroblastic cells had bland nuclei. The cells focally contained some lipid and areas of prominent stromal oedema were seen. No mitoses or necrosis were present (Fig. 3).

In summary, the cervix showed squamous metaplasia with no atypia of squamous or glandular elements. The endometrium showed hormonal effect consistent with LNG-IUS in situ. The myometrium and left fallopian tube was unremarkable. An ovarian fibrothecoma was diagnosed and there were no signs of malignancy.

**DISCUSSION**

The majority (>90%) of ovarian fibrothecomas are unilateral. They are mostly present in post menopausal women.<sup>5</sup> The presentation of our patient was unusual as she did not complain of abdominal bloating, ascites or pleural effusion that can be present with pelvic tumours as described in Demons-Meigs syndrome.<sup>6</sup>

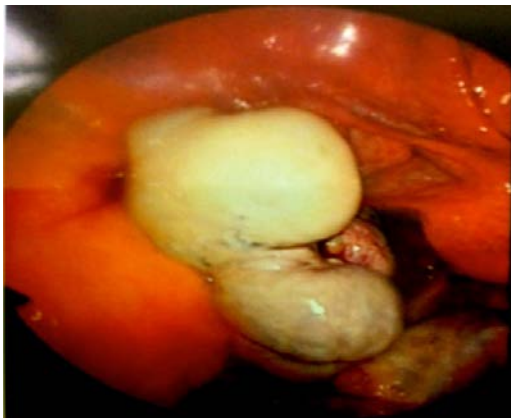

FIG. 1: Laparoscopic view of left ovarian mass

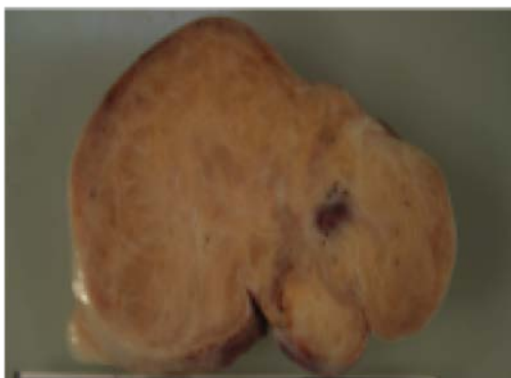

FIG. 2: Macroscopic view of the cut section of left ovarian mass.

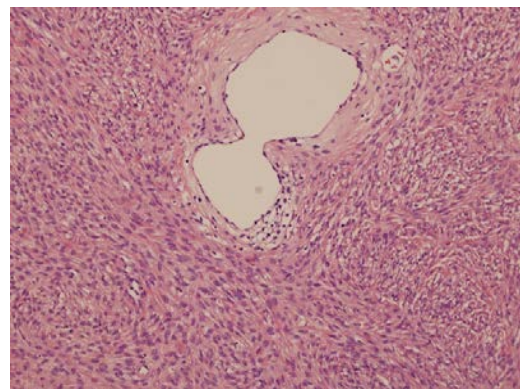


FIG. 3: Histology of left ovarian fibrothecoma showing spindle shaped fibroblastic cells with bland nuclei.

However, an elevated CA-125, as found in our patient, has been reported in some cases of Demons-Meigs Syndrome.<sup>7</sup> Although bedside ultrasound revealed a large uterine fibroid, it was clearly misdiagnosed. It has been previously reported that ovarian fibromas may mimic uterine myomas on ultrasound.<sup>8</sup> In our case, the mass was found to be a fibrothecoma mimicking a uterine fibroid. The main presenting complaint of the patient was pv bleeding with an onset of approximately 4 years post LNG-IUS insertion. She has not experienced any spotting or pv bleeding in the past before this episode. Although the menorrhagia was not significant enough to cause symptoms of anaemia, it did cause the patient to raise concerns regarding the efficacy and location of the LNG-IUS. It has been well evidenced that LNG-IUS reduces the severity of menorrhagia when there is presence of uterine fibroids.<sup>9</sup> As seen in Fig. 1, the discovery of a large left-sided ovarian mass was unexpected. The mass was initially seen as a large uterine fibroid on bedside ultrasound. The mild rise in CA-125 allowed us to confidently resect the ovarian mass without a gynaecological oncology consultation. On gross examination, the LNG-IUS was found inside the uterus with no malposition. An intrauterine fibroid was found, however, she was treated with LNG-IUS that has been a mainstay for conservative management of pv bleeding from fibroids.<sup>9-12</sup> A correlation between ovarian fibrothecoma and our patient's pv bleeding was established. As previously described, the characteristic of a fibroma is a benign non hormonal tumour.<sup>5</sup> A thecoma, on another note is known to be oestrogenic and can cause abnormal uterine bleeding.<sup>13</sup> Fibrothecomas however have a mixed cell type that may present with features of both types of tumours and can have mixed properties.<sup>2</sup> In our case, the ovarian fibrothecoma that was mildly oestrogenic was probably the reason our patient resumed menstruation which prompted her clinical presentation.

### Conclusion

Ovarian fibrothecomas are rare in young women. We have described an occurrence of this sex cord-stromal tumour in a woman of reproductive age whose primary symptom was menorrhagia despite having a LNG-IUS *in-situ*. The hormonal interactions between LNG-IUS and hormone releasing tumours are yet to be established. However, in the setting of unexplained pv bleeding in the background of

previously functioning LNG-IUS, a diagnosis of a fibrothecoma should be considered. The patient had good recovery post surgery with no complications. To our knowledge, this was the first reported case of an ovarian fibrothecoma in a young Australian woman with a malfunctioning LNG-IUS causing menorrhagia.

### ACKNOWLEDGEMENT

The authors thank Dr Keith Arnold McCallum, Obstetrician Gynaecologist, for helping us with the surgery and Dr Susan Sparrow, Pathologist, for providing macroscopic images of the tumour.

### Conflict of interest statement

The authors declare no conflicts of interest from this publication.

### Funding

None

### Ethical approval statement

Verbal consent followed by written informed consent was obtained from the patient prior to publication of this case report. A copy of the consent provided by patient is available upon request for review by the Editor-in-Chief of this journal.

### REFERENCES

1. Wilkinson N, Osborn S, Young RH. Sex cord-stromal tumours of the ovary: A review highlighting recent advances. *Diagn Histopathol*. 2008; 14(8): 388-400.
2. Quirk JT, Natarajan N. Ovarian cancer incidence in the United States, 1992-1999. *Gynecol Oncol*. 2005; 97(2): 519-23.
3. Scully RE, Young RH, Clement PB. Tumors of the ovary, maldeveloped gonads, fallopian tube and broad ligament. In: *Atlas of Tumour Pathology*, 3<sup>rd</sup> Series, No 23. Washington DC: Armed Forces Institute of Pathology; 1998.
4. Jung SE, Rha SE, Lee JM, *et al*. CT and MRI findings of sex cord-stromal tumor of the ovary. *AJR Am J Roentgenol*. 2005; 185(1): 207-15.
5. Chechia A, Attia L, Temime RB, Maklouf T, Koubaa A. Incidence, clinical analysis and management of ovarian fibromas and fibrothecomas. *Am J Obstet Gynecol*. 2008; 199(5): 473. e1-4.
6. Brun JL. Demons syndrome revisited: a review of literature. *Gynecol Oncol*. 2007; 105(3): 796-800.
7. Timmerman D, Moerman P, Vergote I. Meigs' syndrome with elevated serum CA-125 levels: two case reports and review of the literature. *Gynecol Oncol*. 1995; 59(3): 405-8.
8. Jung US, Choi JS, Lee JH, Ko JH. Laparoscopic

- surgical management and clinical characteristics of ovarian fibromas: A study of 47 women in a single centre. *J Minim Invasive Gynecol.* 2012; 19(6): S142.
9. Grigorieva V, Chen-Mok M, Tarasova M, Mikhailov A. Use of a levonorgestrel-releasing intrauterine system to treat bleeding related to uterine leiomyomas. *Fertil Steril.* 2003; 79(5): 1194-8.
  10. Starczewski A, Iwanicki M. Intrauterine therapy with levonorgestrel releasing IUD of women with hypermenorrhea secondary to uterine fibroids. *Ginekol Pol.* 2000; 71(9): 1221-5.
  11. Magalhães J, Aldrighi JM, de Lima GR. Uterine volume and menstrual patterns in users of the levonorgestrel-releasing intrauterine system with idiopathic menorrhagia or menorrhagia due to leiomyomas. *Contraception.* 2007; 75(3): 193-8.
  12. Zapata LB, Whiteman MK, Tepper NK, Jamieson DJ, Marchbanks PA, Curtis KM. Intrauterine device use among women with uterine fibroids: a systematic review. *Contraception.* 2010; 82(1): 41-55.
  13. Aboud E. A review of granulosa cell tumours and thecomas of the ovary. *Arch Gynecol Obstet.* 1997; 259(4): 161-5.