

# Harlequin ichthyosis in a 4-year-old male: case report

Janice Natasha C Ng,<sup>1</sup> Margaret Stephanie L Jimenez,<sup>1</sup> Crystal R Lademora-Dinopol,<sup>1</sup> Mary Jo Kristine S Bunagan,<sup>1,2</sup> Jennifer Aileen A Tangtatco<sup>1,3,4</sup>

<sup>1</sup>Department of Dermatology, Southern Philippines Medical Center, JP Laurel Ave, Davao City, Philippines  
<sup>2</sup>Metro Davao Medical and Research Center, JP Laurel Ave, Davao City, Philippines  
<sup>3</sup>Skin Doctors, Davao City, Philippines  
<sup>4</sup>Brokenshire Hospital Integrated Health Ministries Inc, Brokenshire Heights, Madapo, Davao City, Philippines

#### Correspondence

Janice Natasha C Ng,  
janicenatashang@gmail.com

#### Article editor

Elsa May D Baron  
Joanne Kate M Martinez

#### Received

21 July 2017

#### Accepted

29 June 2018

#### Published online

23 August 2018

#### Cite as

Ng JNC, Jimenez MSL, Lademora-Dinopol CR, Bunagan MJKS, Tangtatco JAA. Harlequin ichthyosis in a 4-year-old male: case report. *SPMC J Health Care Serv.* 2018;4(1):6.  
<http://n2t.net/ark:/76951/jhcs6pm9f8>

#### Copyright

© 2018 JNC Ng, et al.

## ABSTRACT

Harlequin ichthyosis (HI) is a rare type of congenital keratinization disorder that, when left untreated, usually leads to early neonatal demise. A clinical diagnosis of HI is considered when a patient presents with thick plate-like scaling of the skin together with eclabium, ectropion, and nasal hypoplasia. The diagnosis can be confirmed by genetic testing to determine mutation in the adenosine triphosphate-binding cassette A12 gene (ABCA12 gene). Early administration of systemic retinoids to promote desquamation, and emollients to control excessive scaling and dryness of the skin, lead to better prognosis in most cases of HI. We present the case of a 4-year-old male with HI who has been successfully managed with bland emollients and systemic acitretin therapy, which we started when he was 1 year old.

**Keywords.** Harlequin ichthyosis, keratinization disorders, ABCA12 gene mutation, acitretin

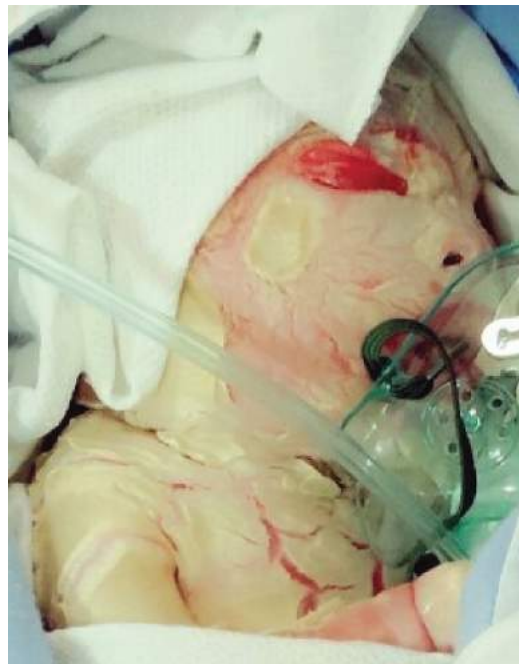## INTRODUCTION

Harlequin ichthyosis (HI) is rare and is considered the most severe form of autosomal recessive congenital ichthyosis.<sup>1,2</sup> Approximately 100 cases have been reported in literature.<sup>2</sup> Only eight patients diagnosed with HI have been recorded in the Philippine Dermatologic Society Health Information System (PDS-HIS) central data from 2011-2017.<sup>3</sup>

A patient with HI is usually reported to have a shiny, tight, parchment-like membrane

stretched over the skin at birth (collodion membrane) that is gradually replaced by thick, plate-like, yellowish scales, separated by deep fissuring.<sup>2,4</sup> Affected individuals also exhibit eversion of eyelids (ectropion), outward turning of the lips (eclabium), poorly developed ears and nose, and flexion contractures of the extremities that lead to restricted mobility.<sup>5</sup> Skin biopsy usually shows massively thickened orthokeratotic stratum corneum, variable acanthosis, and decreased thickness of the granular layer.<sup>6,7</sup> However, the diagnosis of HI is primarily based on clinical characteristics that include eclabium, ectropion, nasal hypoplasia.<sup>8</sup> A genetic test to determine mutation in the ABCA12 gene, may also be done to verify the clinical diagnosis of HI.<sup>9</sup>

The management of HI involves a multidisciplinary care team and is geared towards



**Figure 1** Generalized, thick, yellowish plate-like scales with deep erythematous fissures at five days of life and ectropion, right eye.

## IN ESSENCE

Harlequin ichthyosis (HI) is a congenital disease of keratinization characterized by severe generalized skin thickening with plate-like scaling.

HI is fatal in the first three months of life, but intensive management with systemic retinoids and emollients lead to better outcomes.

In this case report, we describe a 4-year-old male who clinically presented with the classic signs of HI—ectropion, eclabium, nasal hypoplasia, and plate-like scales. We have been successfully managing the patient's excessively thickened scales with systemic acitretin and topical moisturizers.



reduction of hyperkeratosis.<sup>10</sup> Most infants with HI often die within the first few days of life due to electrolyte imbalance, poor nutrition, sepsis, or respiratory failure.<sup>11</sup> We report the case of a 4-year-old male who presented with clinical and histopathologic features of HI at 10 months. The patient did not receive the standard early management for HI right after birth, but has demonstrated good clinical improvement for three years now after initiation of acitretin.

### CLINICAL FEATURES

The patient was 10 months old when he was referred to our department due to generalized scaling of the skin. As reported by the mother, the patient had thick, yellowish-white plaques bordered by deep, red fissures covering his skin early in life (Figure 1). His eyelids and mouth were everted. He had no physical deformities noted in the head, trunk and extremities at that time. After a week, the skin lesions dried up and were replaced by generalized thick brownish scales. The extremities became rigid, assuming a semi-flexed position. The patient was seen by a general physician and was prescribed a week's course of oral cloxacillin. The skin lesions persisted even after the antibiotic course. When the patient was two months old, thick dried skin formed tight bands around several areas on his hands and eventually caused autoamputation of all the fingers. The skin around both eyes started to tighten when the patient was four months old, making it difficult for him to close his eyelids.

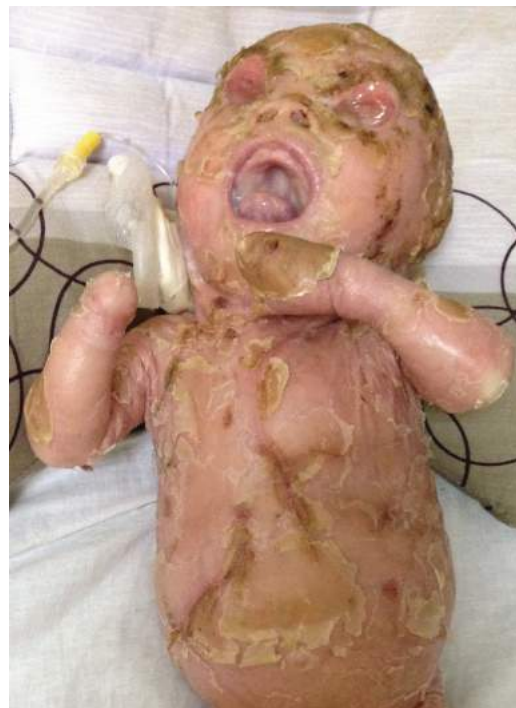During the time of referral to Dermatology service, the patient was admitted in our hospital under Pediatrics service for acute gastroenteritis with moderate dehydration, aspiration pneumonia, and anemia. He was given intravenous clindamycin 10 mg/kg/dose IV every 6 hours and zinc oral drops at 0.5 mg/kg/day once daily for the gastrointestinal and lung infections. The patient was also transfused with a total of 84 mL of packed red blood cells and was started on ferrous sulfate with folic acid 1 ml daily to address anemia.

He was also referred to Ophthalmology service, and subsequently managed for corneal perforation with uveal prolapse, phthisis bulbi, and ectropion on both eyes. He was prescribed tobramycin eye drops three times daily and frequent application of eye lubricants—deproteinized calf blood

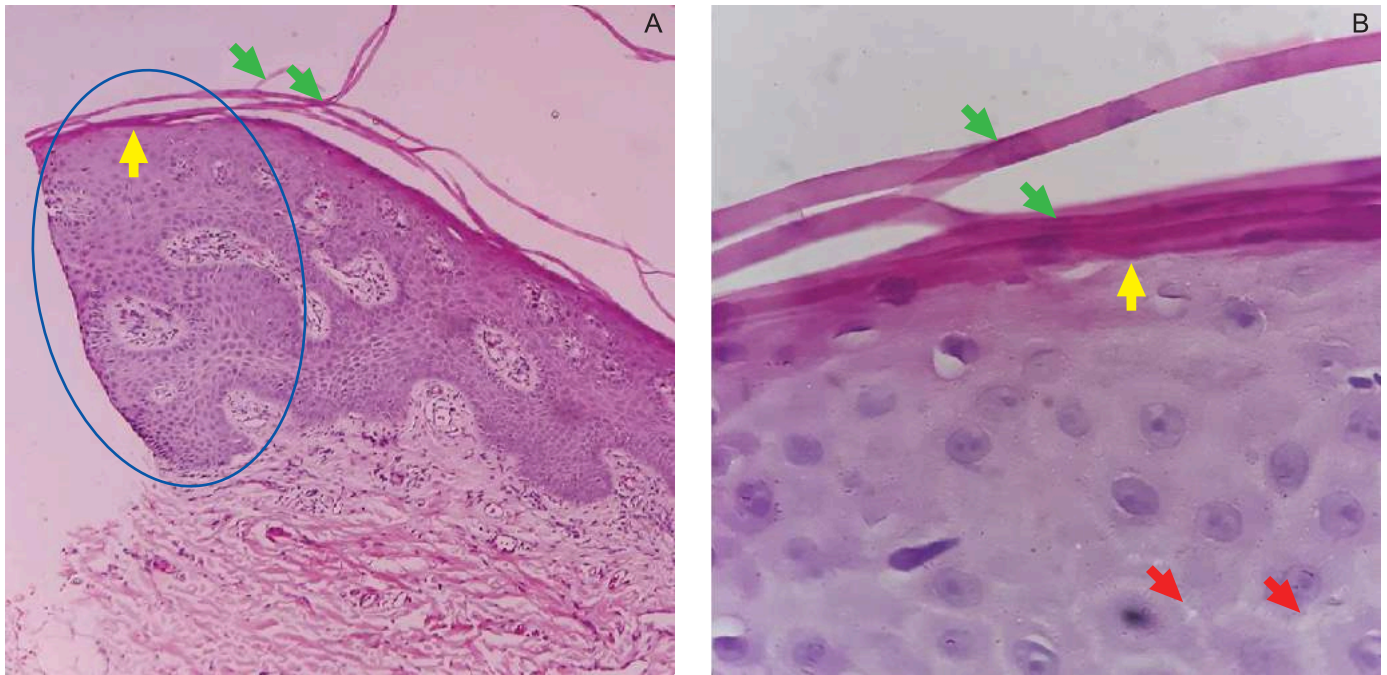
extract (Solcoseryl) gel, glycerin + propylene glycol (Soothe) eye drops, and carbomer eye gel. The patient was referred to Dermatology service for evaluation and management of the skin lesions.

The patient was born full-term by normal spontaneous vaginal delivery in a maternity clinic to a 25-year-old G2P2(2002) mother who had regular prenatal checkup with no known medical illness. The patient had no immunizations since birth. He was both breast- and bottle-fed from birth up to the time of referral. At 10 months, the patient could only lie in supine position, but could not turn to prone position, sit alone or crawl. The patient's parents were non-consanguineous, and the rest of the family history was unremarkable.

On physical examination, the patient had normal vital signs. His weight (3.4 kg; z-score <-3) and length (51cm; z-score <-3) suggested severe underweight and severe stunting. The skin showed generalized thick, large, brownish, adherent, scaly plates with crusting and fissures (Figure 2). The scalp had alopecia. Facial features included bilateral ectropion with purulent eye discharge, bilateral atrophic globes, eclabium, and hypoplasia of the ears and nose. Both upper and lower extremities had limited



**Figure 2** Generalized thick, large, brownish and adherent plate-like scales at 10 months of age.



**Figure 3** Skin punch biopsy, done when the patient was 3 years old, showing confluent parakeratosis (A and B: green arrow) overlying an acanthotic epidermis (A: blue ring) with mild spongiosis (B: red arrows) and focal areas of hypogranulosis (A and B: yellow arrows) (hematoxylin-eosin stain, A: x10 and B: x100).

ranges of motion due to flexion deformities and hypoplastic limbs. All fingers of both hands were missing. The rest of the physical examination findings were unremarkable.

Basing on the patient's presentation of having eclabium, ectropion, nasal hypoplasia, and adherent scaly plates on the skin since birth, we gave the working diagnosis of HI. We decided to proceed with treatment immediately, and it was only much later that we performed a skin punch biopsy to support our initial diagnosis (Figure 3). Histopathology of the biopsy specimen revealed the presence of parakeratotic and mildly spongiotic epidermis with focal areas of hypogranulosis, which is consistent with HI.

#### DIAGNOSTIC APPROACHES

To control skin dryness, we prescribed the application of petroleum jelly all over the face, trunk, and extremities in the morning, after bathing, and three more times during the day. We also prescribed the application of bland emollients (a mixture of unscented moisturizer and virgin coconut oil) in the same areas and use of plastic wrap occlusion around the extremities in the evening. To control the thickness of heavily keratinized skin areas, we prescribed daily application of urea lotion. This skin care regimen was maintained all throughout the patient's

almost three-week admission for the medical conditions. When the patient was discharged, we ordered the same elements in the regimen, except for the plastic wrap occlusion in the evening. After resolution of the medical conditions (gastroenteritis, pneumonia, and anemia), we started the patient on acitretin 0.35 mg/kg/day. Acitretin is an oral retinoid known to be effective in the treatment of several disorders of keratinization, including HI.<sup>11-14</sup> We increased the dose of acitretin to 0.5 mg/kg/day after 6 months. The patient has been on this dose with good compliance up to the present, 3 years since the initiation of acitretin therapy. Because acitretin has been known to cause elevation of liver enzymes, and serum lipids,<sup>15 16</sup> we took baseline and monthly levels of the patient's serum cholesterol panel and SGPT throughout the therapy. We also did a skeletal survey 25 months after initiation of acitretin, since the drug has been reported to cause premature epiphyseal closure, osteophyte formation, and hyperostosis in some patients.<sup>16 17</sup> We saw the patient in our outpatient clinic on numerous occasions for pneumonia, upper respiratory infection, and urinary tract infection, which we managed with appropriate antibiotics.

#### OUTCOMES

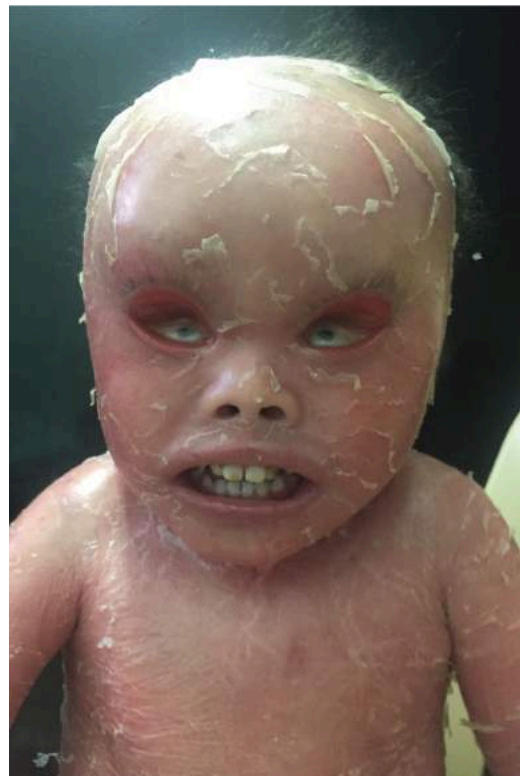After 8 months of low-dose (0.35 mg/kg/day)

acitretin therapy along with the prescribed topical regimen, we observed only minimal reduction in the thickness of the scales. The increase in acitretin dose to 0.5 mg/kg/day, resulted in significant thinning of the scales and marked improvement in the range of motion of the extremities. Now that the patient is four years old, the skin scales look thinner, without visible skin fissures, and the ectropion and eclabium are less prominent (Figure 4). The patient's SGPT levels remained normal, but we noted several spikes of triglyceride and low-density lipoprotein, and very-low-density lipoprotein levels throughout the acitretin therapy (Figure 5). The skeletal survey done two years after initiation of acitretin therapy was negative for pathologic osteophyte formation, osteoporosis, or calcification of ligaments. We regularly see the patient in our outpatient clinic for monitoring of the skin lesions and his general condition, assessment of laboratory results, and adjustment of acitretin dosage. There is no literature supporting lifetime use of acitretin, but since it is an indispensable drug in the maintenance of the normal growth cycle of skin cells and skin integrity, we are planning to give the drug long term and monitor adverse effects accordingly.

## DISCUSSION

HI is an autosomal recessive disorder with mutation in the adenosine triphosphate-binding cassette A12 gene (*ABCA12* gene), which codes for the *ABCA12* lipid transporter.<sup>1</sup> In patients with HI, the absence of the *ABCA12* lipid transporter causes abnormally-shaped, reduced, or absent lamellar granules. Consequently, no desquamation occurs, so the stratum corneum becomes excessively thick.<sup>6</sup>

Clinically, this is manifested as hyperkeratosis and severe breakdown of skin permeability.<sup>18</sup> Severe hyperkeratosis leads to contractures of the upper and lower extremities, which in turn cause limitations in the range of motion of the extremities, as seen in our patient. The movement of other joints and structures, such as temporomandibular joints and chest, with overlying skin contractures may also be affected. Severe hyperkeratosis can also cause constricting bands to form around the fingers,<sup>19</sup> which can lead to necrosis and autoamputation of the digits, as in our patient. Hair loss has also been reported among patients

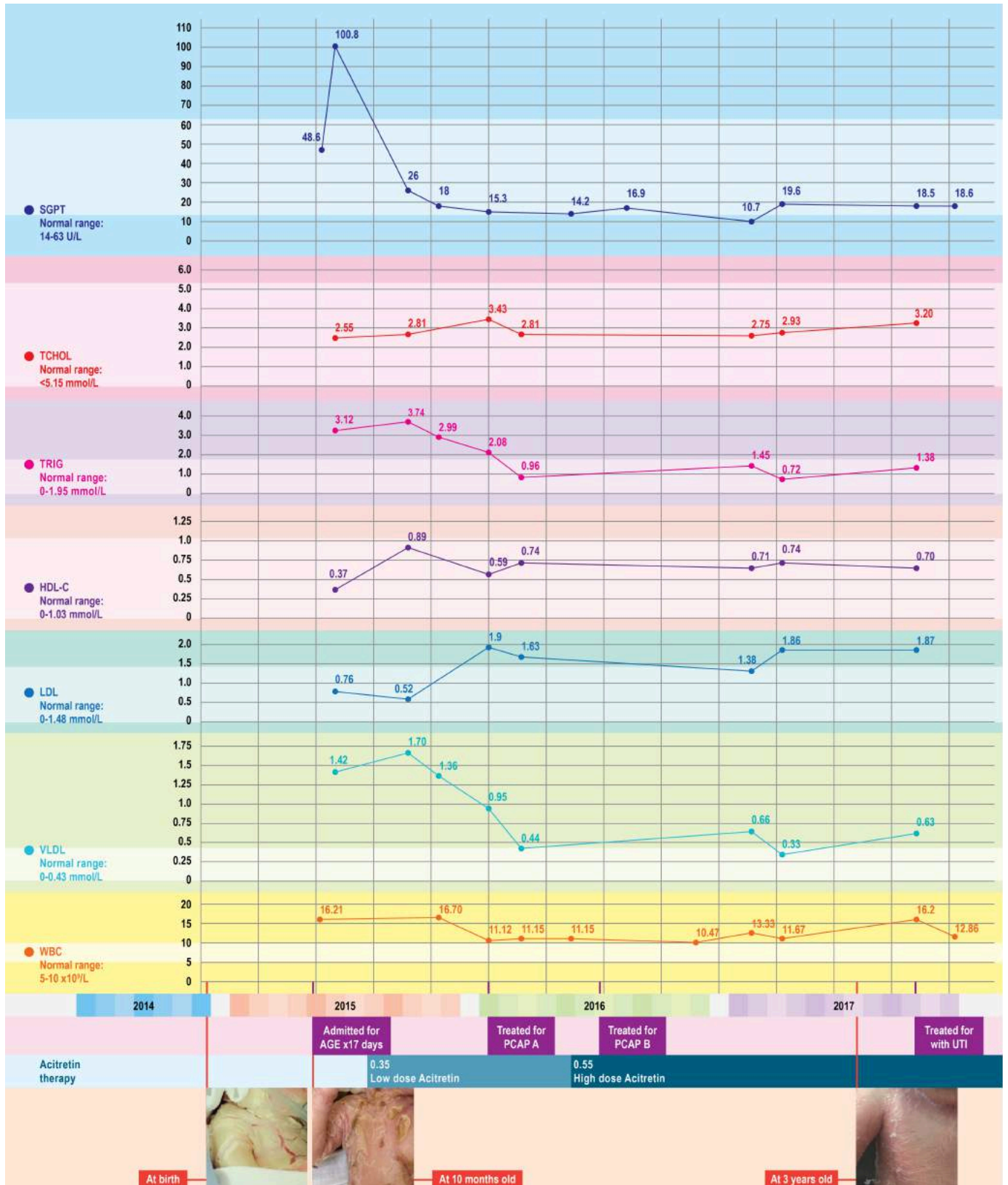


**Figure 4** Generalized thin scales without fissures, and less prominent ectropion and eclabium after 29 months of acitretin treatment.

with HI.<sup>11-14</sup> However, studies done on mouse models displaying hallmarks of HI have shown that, despite the skin defects, normal hair development and differentiation may be observed.<sup>20</sup>

Patients with HI are noted to have impaired nutrition because of an increase in the transepidermal water loss and skin turnover. Malnutrition is further exacerbated by impaired food mastication and intake due to eclabium and jaw constriction. Ectropion and skin contractures around the eyes prevent normal closure of the eyelids. The constant exposure of the eye surface can lead to dryness and cause keratitis. If left untreated, keratitis can result in corneal ulceration and, in extreme cases as in our patient, uveal prolapse and phthisis bulbi.<sup>21</sup> Patients with HI are also prone to secondary infections due to impaired skin barrier function and decreased secretion of antimicrobial peptides.<sup>22</sup> Respiratory failure may result from limited chest expansion due to contracted skin around the chest.<sup>23</sup>

The telltale features of HI, such as ectropion, nasal hypoplasia, and eclabium, may already be visualized through ultra-



**Figure 5** Chart showing the temporal relationships of therapeutic interventions, serum SGPT levels, serum lipid levels, WBC counts, and images of skin lesions. AGE — Acute Gastroenteritis; HDL-C — High density lipoprotein cholesterol; LDL — Low-density lipoprotein; PCAP A — Pediatric community acquired pneumonia minimal risk; PCAP B — Pediatric community acquired pneumonia low risk; SGPT — Serum glutamic pyruvic transaminase; TCHOL — Total cholesterol; TRIG — Triglyceride; UTI — Urinary tract infection; VLDL — Very low-density lipoprotein; WBC — White blood cells.

sonography during the second or third trimester of pregnancy,<sup>24,25</sup> and the diagnosis may be established prenatally.<sup>26</sup> This diagnostic procedure can be done on fetuses with either positive family history of HI or consanguineous parents. Ultrasonography may pose as a challenge in the diagnosis of fetuses with late phenotypic expression of the disease.<sup>24,27</sup> Alternatively, chorionic villus sampling and analysis of amniotic fluid cells,<sup>24</sup> or fetal skin biopsy at 18 weeks of gestation<sup>27</sup> may be done to diagnose HI prenatally. Skin punch biopsy, commonly done among patients clinically diagnosed with HI, usually shows massive hyperkeratosis and parakeratosis with thin or absent granular layer.<sup>28</sup> Genetic confirmation of ABCA12 mutation is both reliable and conclusive in establishing the diagnosis of HI.<sup>9,24</sup>

The clinical presentation of HI is highly distinctive. However, HI must be differentiated from other congenital ichthyosiform disorders such as ichthyosis vulgaris (IV), X-linked recessive ichthyosis (XLRI), congenital ichthyosiform erythroderma (CIE) and lamellar ichthyosis (LI).

Although all these conditions present with generalized scaling, IV lesions consist of fine white scales, XLRI lesions are polygonal, dark-brown scales with erythroderma, while CIE lesions are fine, powdery white scales within a background of generalized erythroderma.<sup>14,29</sup> Furthermore, patients with IV, XLRI, or CIE do not have the ectropion, eclabium, and collodion membrane that are associated with HI.<sup>18</sup> Although LI also present with ectropion, eclabium, collodion membrane and alopecia, these signs are less pronounced compared to those found among patients with HI.<sup>30</sup>

HI was primarily considered in our patient due to the documented presence of generalized brownish scales with fissuring early in life and clinical findings of ectropion, eclabium, and nasal hypoplasia. Hyperkeratosis causing limited range of motion of the extremities and autoamputation of the digits, often seen in patients with HI, is also present in our patient. Other related non-dermatologic conditions that accompany HI, such as keratitis, conjunctivitis, are malnutrition, are also found in our patient.

In patients with HI, hydration and desquamation is promoted through the application of emollients.<sup>2,23</sup> Our patient's skin care regimen included the use of plastic

wrap occlusion to help retain moisture, and application of urea lotion on thick skin areas. We also prescribed the regular application of moisturizing eye drops to control dryness and topical antibiotics to prevent eye infection.

Systemic retinoids, such as acitretin, are the most effective treatments for ichthyosiform disorders, because they accelerate the shedding of the hyperkeratotic plate-like scales.<sup>14</sup> Of the systemic retinoids, acitretin is preferred because it has a better safety profile compared to etretinate.<sup>12</sup> Known adverse effects of acitretin therapy include hepatotoxicity and hyperlipidemia.<sup>17</sup> Osteoporosis and premature epiphyseal closure may also be seen in long-term acitretin use.<sup>11</sup> Constant monitoring of lipid levels and liver function tests are warranted during acitretin therapy.<sup>11</sup> The usual dose of acitretin for disorders of keratinization is 0.5 to 1 mg/kg/day.<sup>31</sup> Because our patient had a high serum SGPT (100 U/L) just before acitretin therapy, we decided to start the drug at a lower dose of 0.35 mg/kg/day, and only increased the dose to the usual 0.5 mg/kg/day after we documented normal serum SGPT levels.

Other than systemic retinoids, tazarotene 0.1% cream, a topical retinoid, has also been reported to improve contractures and ectropion associated with HI.<sup>19</sup> The topical application of tazarotene together with splinting around constricting bands in digits or toes eliminates the need for surgical release of the bands.<sup>32</sup>

There have been accounts of prolonged survival of patients diagnosed with HI, some of whom have reached their third decade with good quality of life, and have enjoyed higher education and independent living.<sup>33-35</sup> Without strict multidisciplinary management and early medical intervention, the overall prognosis of HI is poor.<sup>35</sup> HI presents with a 50% worldwide mortality rate, mostly due to sepsis and respiratory failure in the first 3 months of life.<sup>10,35</sup> The survival rate of patients tends to increase with intensive postnatal care and the use of oral retinoids such as acitretin.<sup>10,18,23,32</sup>

Our patient has been under our care for more than two years now. When we first saw him and before we could intervene, all of his fingers have already been autoamputated and he already had bilateral phthisis bulbi. Earlier intervention with systemic acitretin and topical moisturizers could have prevented these irreversible complications.

**Acknowledgments**

We would like to extend our heartfelt gratitude to Dr Karen Kate Quilat and Dr Jesse Jay Baula of the Department of Ophthalmology for the clarifications and information they provided as we were editing this article.

**Patient consent**

Obtained

**Reporting guideline used**

CARE Checklist

(<http://www.care-statement.org/downloads/CAREchecklist-English.pdf>)

**Article source**

Submitted

**Peer review**

External

**Competing interests**

None declared

**Access and license**

This is an Open Access article licensed under the Creative Commons Attribution-NonCommercial 4.0 International License, which allows others to share and adapt the work, provided that derivative works bear appropriate citation to this original work and are not used for commercial purposes. To view a copy of this license, visit <http://creativecommons.org/licenses/by-nc/4.0/>

**REFERENCES**

- Habib A, Pasha W, Raza N, Hameed A. Harlequin ichthyosis in two siblings. *J Coll Physicians Surg Pak*. 2011; 21(8):503-05.
- Belengeanu V, Stoicanescu D, Stoian M, Andreescu N, Budisan C. Ichthyosis congenita, harlequin fetus type: a case report. *Adv Med Sci*. 2009; 54:113-5.
- Philippine Dermatological Society Health Information Systems [data file]. Philippine Dermatological Society. 2011 [updated 2017 May 5; cited 2017 June 5].
- Chung M, Pittenger J, Tobin S, Chung A, Desai N. Expedient treatment of a collodion baby. *Case Rep Dermatol Med*. 2011.
- Rathore S, David L, Beck M, Bindra M, Arunachal G. Harlequin ichthyosis: prenatal diagnosis of a rare yet severe genetic dermatosis. *J Clin Diagn Res*. 2015; 9(11):4-6.
- Hovnanian A. Harlequin ichthyosis unmasked: a defect of lipid transport. *J Clin Invest* 2005;115(7):1708-10.
- Dale B, Holbrook K, Fleckman P, Kimball J, Brumbaugh S, Sybert V. Heterogeneity in harlequin ichthyosis, an inborn error of epidermal keratinization: variable morphology and structural protein expression and a defect in lamellar granules. *J Invest Dermatol*. 1990; 94(1):6-18.
- Vergotine RJ, de Lobos M, Montero-Fayed M. Harlequin ichthyosis: a case report. *Pediatr Dent*. 2013; 35(7):497-499.
- Sheth J, Bhavsar R, Patel D, Joshi A, Sheth F. Harlequin ichthyosis due to novel splice site mutation in the ABCA12 gene: postnatal to prenatal diagnosis. *Int J Dermatol*. 2018 Apr; 57(4):428-33.
- Milstone L, Choate K. Improving outcomes for Harlequin Ichthyosis. *J Am Acad Dermatol*. 2013; 69:808-809.
- Harvey H, Shaw M, Morrel D. Perinatal management of harlequin ichthyosis: a case report and literature review. *J Perinatol*. 2010 Jan; 30(1):66-72.
- Damodaran K, Bhutada A, Rastogi S. A unique preparation and delivery method for acitretin for neonatal Harlequin ichthyosis. *J Pediatr Pharmacol Ther*. 2018; 23(2):164-7.
- Cakmak A, Baba F, Cakmak S, Shermatov K, Karazeybek H. Treatment of congenital ichthyosis with acitretin. *The Internet journal of pediatrics and neonatology*. 2007;8(1).
- VDiGiovanna JJ, Mauro T, Milstone LM, Schmutz M, Toro J. Systemic retinoids in the management of Ichthyoses and related skin types. *Dermatol Ther*. 2013;26(1).
- Pilkington T, Brogden RN. Acitretin: a review of its pharmacology and therapeutic use. *Drugs*. 1992 Apr; 43(4):597-627.
- Gautam M, Tahiliani H, Nadkarni N, Patil S, Godse K. Acitretin in pediatric dermatoses. *Indian J Paediatr Dermatol*. 2016; 17(2):81-94.
- Drug name: Acitretin. BC Cancer Agency Cancer Drug Manual. 2008 Sep.
- Richard G, Ringpfeil F. Ichthyoses, erythrokeratodermas, and related disorders. In: Bologna JL, Schaffer JV, Cerroni L. *Dermatology*. 4th ed. New York: Elsevier; 2018. p. 888-923.e3.
- Craiglow BG. Ichthyosis in the Newborn. *Semin Perinatol*. 2013 Feb; 37(1):26-31..
- Zhang L, Ferreyros M, Feng W, Hupe M, Crumrine DA, et al. Defects in Stratum Corneum Desquamation Are the Predominant Effect of Impaired ABCA12 Function in a Novel Mouse Model of Harlequin Ichthyosis. *PLoS One*. 2016;11(8): e0161465.
- Al-Amry MA. Ocular manifestation of Ichthyosis. *Saudi J Ophthalmol*. 2016 Jan-Mar; 30(1):39-435.
- Chan A, Godoy-Gijon E, Nuno-Gonzalez A, Crumrine D, Hupe M, et al. Cellular Basis of Secondary Infections and Impaired Desquamation in Certain Inherited Ichthyoses. *JAMA Dermatology*. 2015;151(3):285-292.
- Salehin S, Azizimoghdam A, Abdollahimohammad A, Babaeipour-Divshali M. Harlequin ichthyosis: Case report. *J Res Med Sci*. 2013; 18(11):1004-1005.
- Rathore S, David L, Beck M, Bindra M, Arunachal G. Harlequin ichthyosis: prenatal diagnosis of a rare yet severe genetic dermatosis. *J Clin Diagn Res*. 2015; 9(11):4-6.
- Wen Y, Zhang SL, He J, Zhang XX, Yu XW. Prenatal diagnosis of congenital harlequin ichthyosis with two- and three-dimensional ultrasound in the third trimester. *J Med Ultrasound*. 2013 Dec; 21(4):221-225.
- Basgul AY, Kavak ZN, Guducu N, Durukan B, Isci H. Prenatal diagnosis of congenital harlequin ichthyosis with 2D, 3D, and 4D ultrasonography. *Clin Exp Obstet Gynecol*. 2011;38(3):283-5. PubMed PMID: 21995167.
- Mithwani AA, Hashmi A, Shahnawaz S, Al Ghamdi Y. Harlequin ichthyosis: a case report of prolonged survival. *BMJ Case Rep*. 2014 Mar 7; 2014.
- Weedon D. *Weedon's skin pathology*. 3rd ed. New York: Elsevier; 2010.
- Patterson JW. Disorders of epidermal maturation and keratinization. In: Patterson JW. *Weedon's Skin Pathology*. 4th ed. New York: Elsevier; 2016.
- Metze D. Disorders of keratinization. In: Calonje E, Brenn T, Lazar A. *McKee's Pathology of the Skin*. 4th ed. New York: Elsevier; 2012.
- Lacour M, Mehta-Nikhar B, Atherton DJ, Harper JI. An appraisal of acitretin therapy in children with inherited disorders of keratinization. *Br J Dermatol*. 1996 Jun;134(6):1023-9. PubMed PMID: 8763418.
- Glick JB, Craiglow BG, Choate KA, Kato H, Fleming RE, Siegfried E, Glick SA. Improved management of Harlequin

ichthyosis with advances in neonatal intensive care. *Pediatrics*. 2017 Jan;139(1).

33. Parry L. 'People ask me if I've been in a fire', says mother, 23, with rare condition which causes her skin to grow seven times faster than normal. *Daily Mail*. 2015 Sep. Available from: <http://www.dailymail.co.uk/health/article-3219489/People-ask-ve-fire-says-mother-23-rare-condition-causes-skin-grow-seven-times-faster-normal.html>.

34. Barns S. Meet the woman with a crippling rare skin condition that gives her 'fish scales'. *Express*. 2014 Dec. Available from: <https://www.express.co.uk/life-style/life/546525/Skin-condition-fish-scales-Harlequin-Ichthyosis>.

35. Rajpopat S, Moss C, Mellerio J, Vahlquist A, Gånemo A, Hellstrom-Pigg M, et al. Harlequin ichthyosis: a review of clinical and molecular findings in 45 cases. *Arch Dermatol* 2011; 147(6):681-6.

#### Southern Philippines Medical Center Journal of Health Care Services Editors

**Editor in chief:** Alvin S Concha • **Issue Editors:** Maricarr Pamela M Lacuesta, Mark Anthony Tom • **Associate Editors:** Seurinane Sean B Española, Aura Rhea D Lanaban, Eugene Lee L Barinaga, Alex Ivan Junefourth Bolor • **Managing Editor:** Clarence Xlasi D Ladrero • **Assistant Editors:** Jaryll Gerard Ampog, Rodel C Roño • **Layout Editor:** Clarence Xlasi D Ladrero

**SPMC JHCS OFFICE** Hospital Research Office, Level 1 Outpatient Building, Southern Philippines Medical Center, JP Laurel Avenue, Davao City, Philippines  
**Landline** (+6382) 2272731 loc 4615 • **Website** <http://spmcpapers.com> • **Email** [info@spmcpapers.com](mailto:info@spmcpapers.com)