

Multiple Strategies to Avoid Life-threatening Blood Loss During Intralesional Resection of a Giant Plexiform Neurofibroma: A Case Report

Ma. Katrina B. Guillermo, MD and Rodney B. Dofitas, MD, FPCS

Department of Surgery, Philippine General Hospital, University of the Philippines Manila

Giant plexiform neurofibroma (PNs) are benign peripheral nerve sheath tumors known to contain multiple fascicles of nerve and numerous friable vascular components. Most consult due to significant disfigurement and functional deficit. Though surgery is the current standard of therapy, there is high reservation in pushing through with resection in most cases. The reservation stems from the recognized difficulty in controlling intraoperative life-threatening hemorrhage. A 25-year-old female came in our institution due to multiple debilitating giant PNs on her scalp, back, neck, shoulder, and chest. She opted for debulking surgery despite possible complications and recurrence. Multiple modalities used to prevent massive bleeding in this case included preoperative arterial embolization, energy sealing device, cutting linear stapler, and interlocking retention sutures. The aim of this case report was to discuss the utility of each of these techniques, the advantages and disadvantages of each approach based on our experience.

Key words: Neurofibromatosis type-1, plexiform neurofibroma, hemorrhage, neurofibroma resection, preoperative arterial embolization

Plexiform neurofibromas (PNs) are peripheral nerve sheath tumors commonly found in as much as 30% of patients with Neurofibromatosis (NF) type 1.¹ The incidence of NF-1 has been estimated to be 1 in 3000.² Grossly, PNs appear to have a diffuse and infiltrative growth that gives them the classic description “bag of worms”.³ Though most are congenital in origin, the growth progression usually occurs in early childhood, puberty, and childbearing age.⁴ It rarely grows to be larger than 5cm.⁵ A giant plexiform neurofibroma, because of its size can cause significant disfigurement and functional deficit by pulling down important structures.⁶ The tumor also may involve multiple fascicles of nerves and tissues

that tumor resection risks neurological and functional destruction.⁷ Most surgical interventions for giant PNs are limited to debulking (intralesional resection) and runs the risk of recurrence afterward leading to the cycle of repeated intervention.⁸ Lastly, PNs have a 5% potential for malignant transformation into Malignant Peripheral Nerve Sheath Tumors (MPNST).⁹

Surgery is the only known modality that can effectively manage plexiform neurofibroma.¹⁰ PNs are not radiosensitive and given their slow growth rates, chemotherapy has only limited benefit.¹¹ Ideally, a complete resection must be done to decrease the chance of recurrence.¹² But due to the network-like growth pattern of giant PNs, most can only be debulked.¹³ Prognostic indicators of recurrence after surgical resection include: 1) younger than 10 years at the time of surgery, 2) head/neck, face and trunk lesion, and 3) incomplete resection.¹⁴

Surgical management for PNFs are difficult to manage due to the extensive infiltrative, highly vascularized nature of the lesion and chance of recurrence.¹⁵ Common complications include life-threatening hemorrhage, local wound infection, and extent of skin coverage.¹⁶ Thus, surgical treatment must be decided judiciously and individualized for each patient.¹⁷ Most case reports and case series on Giant PNFs resection touch on their experience handling profuse intraoperative hemorrhage. In this case report, the authors utilized multiple modalities to prevent or control massive life-threatening hemorrhage during intralesional resection of multiple giant plexiform neurofibromas of the scalp, neck, shoulder, back and chest. This paper aimed to provide an account of the utility of each of these techniques, while discussing the

advantages and disadvantages of each approach based on our experience.

The Case

This is the case of a 25-year-old female from Biliran Island who was diagnosed to have Neurofibromatosis (NF) type 1. The disorder started to become evident at

age 6 when pedunculated masses started to appear on the scalp, back, face, shoulder, and chest (Figure 1). Apparently, she was born with a defect in the occipital area of the skull where the mass eventually appeared. The masses were painless but due to their bulk and disfiguring nature, her social interaction and outdoor activities were limited. She was otherwise healthy and had never been hospitalized. No other member of the family or any relative manifested the same condition.

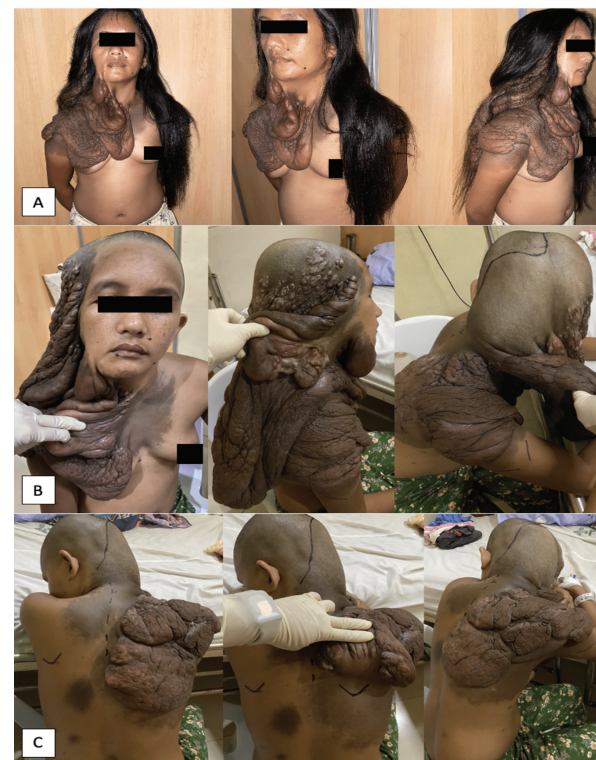

Figure 1. a) Initial patient consult. Multiple mass located at b) chest, post-auricular and scalp neurofibroma c) back and shoulder neurofibroma.

She fulfilled four out of the seven NIH criteria¹⁸ for the diagnosis of NF type 1 (Giant Plexiform Neurofibroma). The patient had 1) café-au-lait skin macules >15mm, 2) plexiform neurofibroma, 3) axillary and inguinal freckling, and 4) bone lesion with sphenoid dysplasia and thinning or absence of long bone (Figure 2).

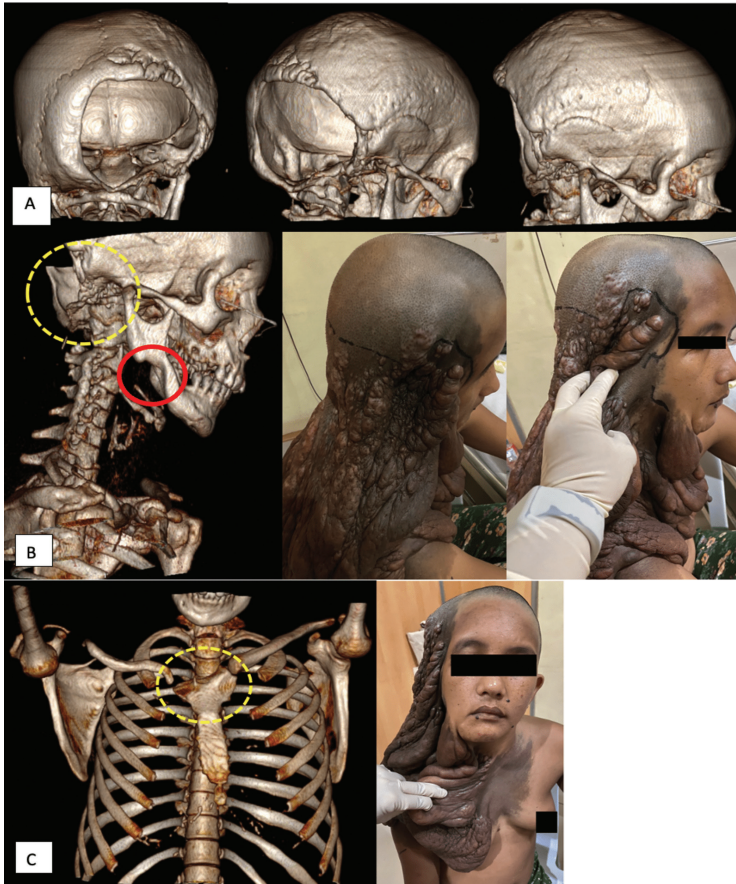


Figure 2. Bone abnormalities a) absent occipital bone, b) right mandible dysplasia, and c) right facet manubrium dysplasia.

Magnetic Resonance Imaging (MRI) studies showed a 7.8 cm x 9.0 cm (CC x W) occipital calvarial defect. The right cerebral hemisphere, occipital lobe, overlying dura, and sinuses herniated through this defect (Figure 3). On the right, a portion of dysplastic brain and CSF also herniated into the right carotid space of the suprahyoid neck. Aside from the absence of the occipital skull, right mandible and right medial portion of the manubrium are hypoplastic and deformed.

The large fungating multilobulated lesions were mainly located in the cutaneous-subcutaneous area at temporoparietooccipital region, right periauricular, lateral anterior and posterior neck regions, right shoulder, upper anterior and posterior right thorax (Figure 4). Most of the lesions were intimately related to underlying muscles. Extensive tortuous dilated collateral vessels were seen in the right lateral neck with extensions feeding the cutaneous lesion. The primary blood supply of the lesion arose from right external carotid artery.

Although the preoperative punch biopsy revealed dendritic blue nevus, the final histopathology of all resected lesions was consistent with neurofibroma.

Risks and benefits of a surgical resection were considered. There were concerns that the procedure could possibly lead to neurologic deficits affecting the patient's gait and balance. Possible risks of massive blood loss, violation of dura and recurrence were discussed. However, due to the extent and incapacitating nature of her condition, the patient decided to undergo the risky procedure. The patient was to undergo preoperative embolization and resection of the neurofibromas.

Right ascending cervical artery, suprascapular artery, lateral thoracic artery, posterior circumflex humeral artery, posterior auricular artery and posterior branch of right superficial temporal artery were superselectively embolized using combination of polyvinyl alcohol, silk and gelfoam particles (Figure 5). Two large feeding vessels from vertebral and left ascending cervical artery

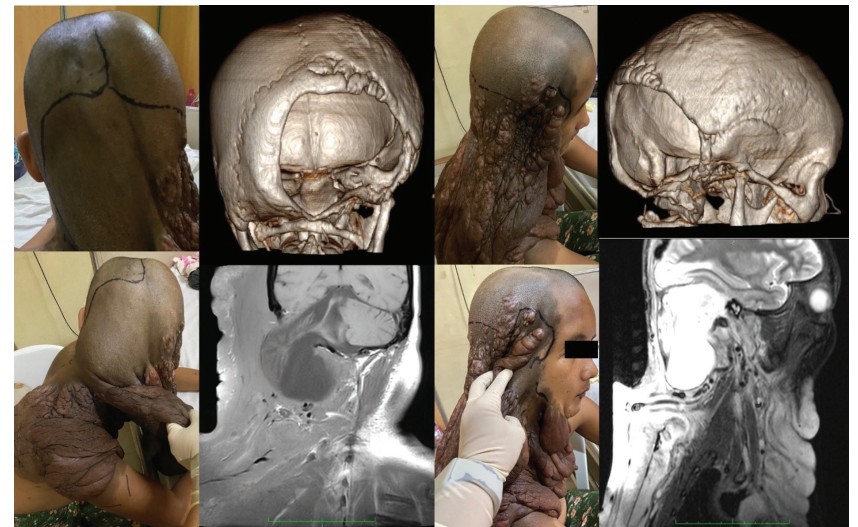

Figure 3. MRI cuts with corresponding defect observed with the patient. a) Absent occipital bone b) Traction at right cerebellar peduncles and vermis, c) postauricular partial temporal bone absent.

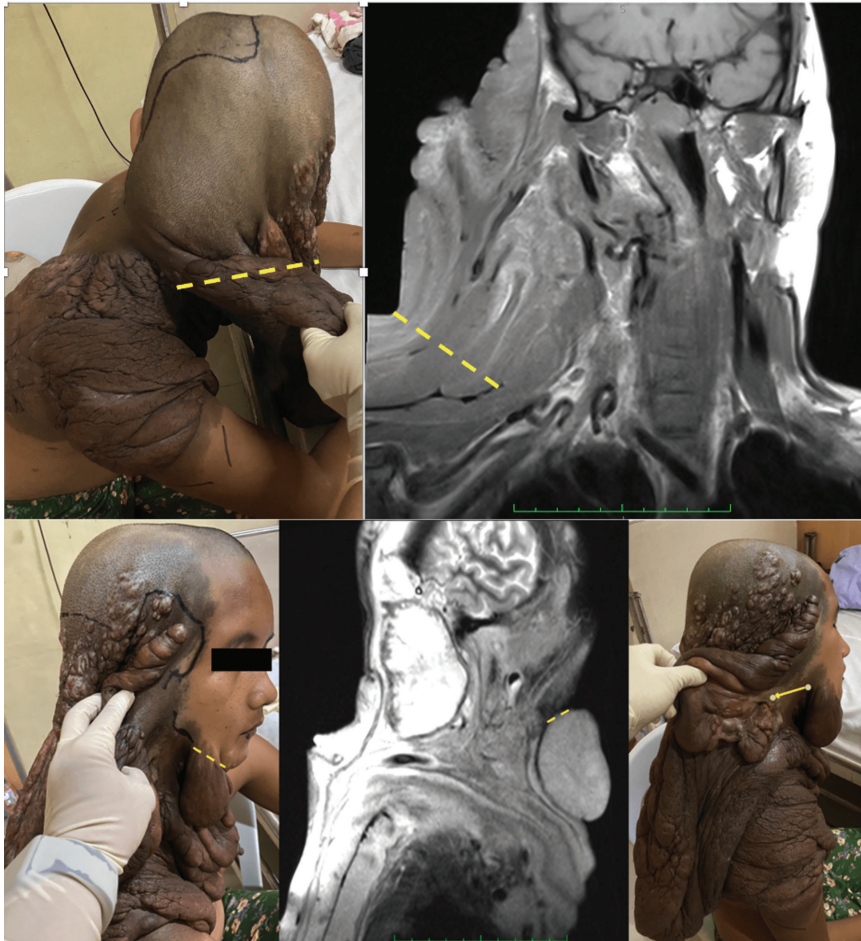

Figure 4. MRI cuts of the multilobulated lesions mainly located in the cutaneous-subcutaneous area at temporoparietooccipital region, right periauricular, lateral anterior and posterior neck regions, right shoulder, upper anterior and posterior right thorax. Abnormal extensive vascular network supplying the lesions are appreciated in these cuts. Interrupted yellow lines were planned surgical incision site.

were not embolized due to lack of safe access. The mass became lighter and more hyperpigmented 48 hours after embolization.

The resection of the neurofibroma was performed 60 hours post-embolization. We utilized chlorhexidine gluconate solution to sterilize the surgical field. The patient was placed in supine position with the scalp masses laid down above her head (Figure 6). All surgical incisions were carefully designed based on the underlying region and the ability to close the skin defect primarily with some form of advancement flap.

The surgical team started with the smallest mass at the neck area to become familiar with the nature of

neurofibroma. It was initially approached using scalpel and electrocautery. The incised skin bled heavily and the mass was friable and hypervascular. Most of the vessels were too friable for ligation as well. We shifted our approach to using an energy sealing device (Ligasure™ Small Jaw® with ForceTriad®; Covidien, Colorado, USA) entirely for both skin and mass in the neck region to provide better hemostasis.

The scalp neurofibroma was ten times thicker than the neck neurofibroma. It was composed of large vessels in between thick bundles of fibers. In this area the utility of energy sealing device became limited. The skin up to subcutaneous fascia was still handled by the Small

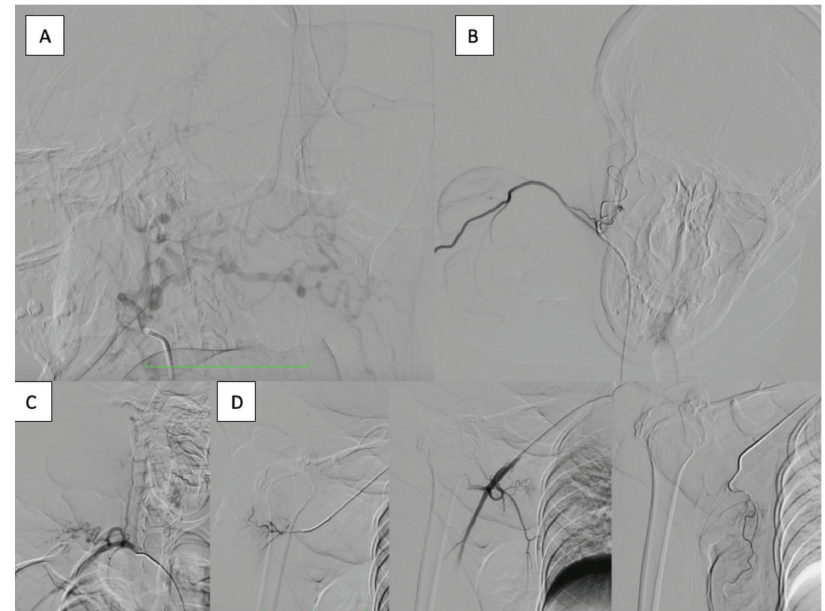


Figure 5. Angiography of the abnormal vascular network supplying a) scalp neurofibroma, b) postauricular neurofibroma - posterior auricular artery, c) back neurofibroma - right suprascapular artery, d) shoulder neurofibroma - right posterior circumflex humeral artery and neck and back neurofibroma. Superselective embolization of these vessels were done by the interventional radiology department.

Jaw[®]. The neurofibroma on the other hand was serially transected using a 75mm linear stapling device (NTLC75; Ethicon, USA) (Figure 7). The 3-row stapling device, was set at the thickest option (2.0 mm) and was applied at the base of each neurofibroma peduncle. This allowed

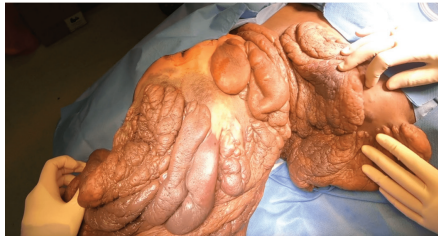

Figure 6. First operation supine position head turned towards the left with all neurofibroma laid over the table.

faster and minimal bleeding during the scalp surgery. The dura and herniating cerebral components were avoided by respecting the planes and dictated by the critical points identified in her MRI scans. The avoidance of dural violation was confirmed by the neurosurgeon on board.

Chest and right shoulder neurofibroma were also approached in the same way. During the primary closure of skin at the scalp and chest region, the anesthesiologist noted muddy brown urine (Figure 8) and the patient developed a temperature of 39-40 C. This suggested the possibility of an acute hemolytic transfusion reaction to her third unit of blood, an untoward reaction under Grade 2 Clavien-Dindo classification. Given the emergent nature of patient's condition, the team decided not to proceed with resection of the back and postauricular neurofibroma left untouched (Figure 9). The patient was adequately hydrated, and immunosuppressive and antipyretic medication were

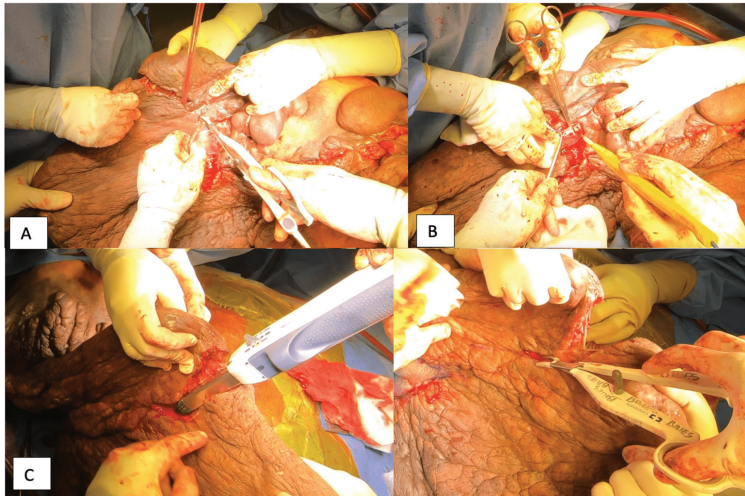


Figure 7. Scalp neurofibroma resection. A). Energy sealing device used at the level of skin and subcutaneous area. B) large caliber vessels located in the neurofibroma. C) cutting linear stapler able to transect and control bleeding.




Figure 8. Muddy brown urine observed intraoperatively giving the clinical impression of acute transfusion reaction. Middle photo shows the lightening of urine after hydration before transout. Rightmost photo shows the resolution of hematuria by 6th hour postoperation.

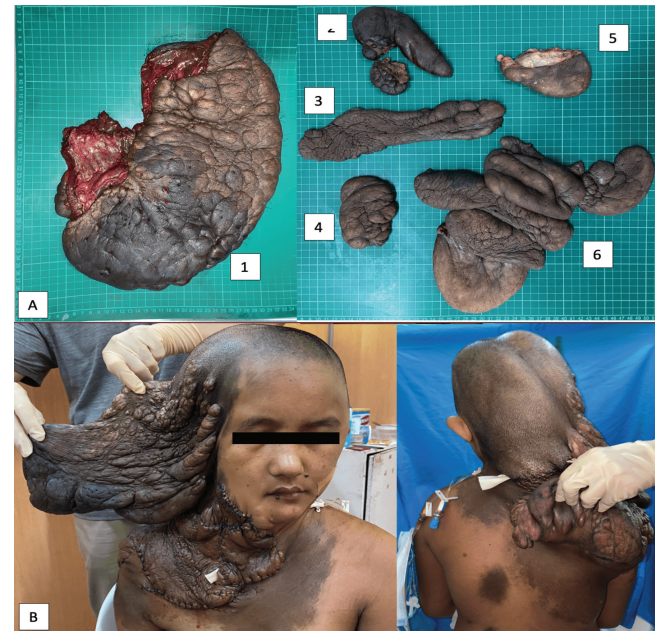

Figure 9. A) Resected Neurofibroma 1. Scalp (36 cm x 25 cm), 2. Ears (10 cm x 15 cm), 3. Neck (20cm x 7cm), 4. Shoulder (7cm x 7cm), 5. Submandibular (7cm x 7cm), and 6. Chest 5 neurofibroma (25cm x 15cm in aggregate). B) postauricular and back neurofibroma left unresected.

administered for the next 72 hours. The patient did not require ICU admission. Adequate urine output was obtained and the urine cleared up by 6th hour post-operation. Intraoperative blood products transfused were properly investigated for proper crossmatching and antigen antibody testing. All tests were negative for incompatibility and clerical error. Post-operative Hgb was 78 g/L and creatinine was normal all throughout postoperative period.

Surgical site during her 4 days post-operation was flat. The skin flaps remained viable. Penrose drain output was minimal. Maximum heart rate was 105 beats per minute. There were no episodes of hypotension and fever. No further transfusion reaction was noted. The neurofibroma that was not resected became necrotic (Figure 10), an expected sequela of embolization. This necessitated completion of resection of her back and the necrotic part of the postauricular neurofibroma.

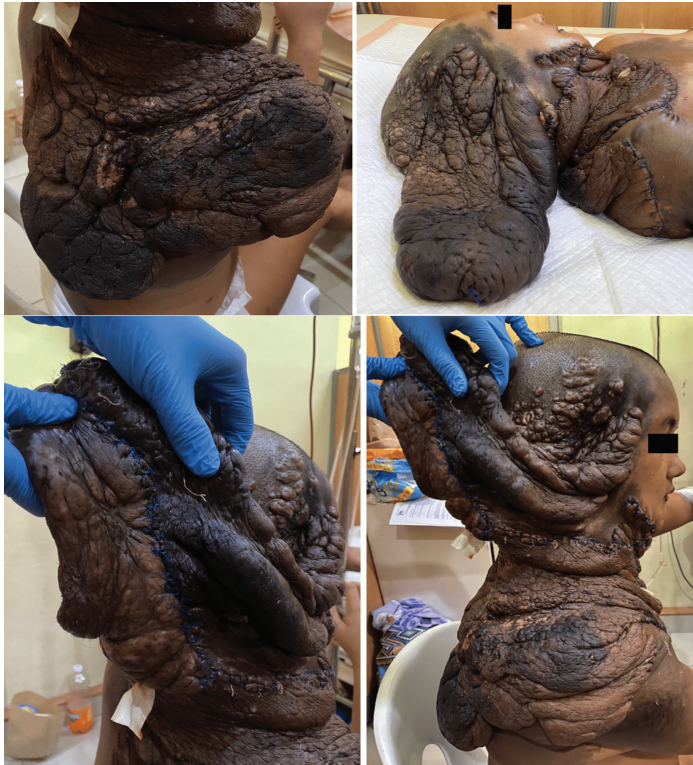

Figure 10. Necrotic back and postauricular neurofibroma fourth day after operation, 7th day post-arterial embolization.

On her 5th post-operative day, the back neurofibroma, nape and lateral right neck felt more tense and full. Scalp and chest postoperative sites were flat and the neck penrose drain had minimal output. Heart rate, however, was 120-130 beats per minute and complete blood count had dropped to 52 g/L. The team was considering a recanalization of the embolized vessels versus hematoma. CT scan of the neck revealed a saccular aneurysm from a branch of subclavian artery with surrounding hematoma and thrombus on their dilated draining veins (Figure 11). During the transport of the

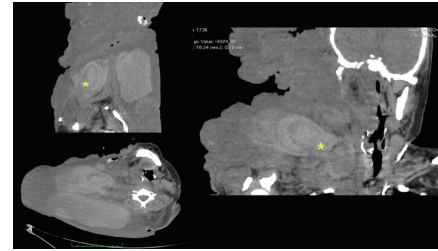


Figure 11. Neck Computed Tomography (CT) scan showing subclavian branch pseudoaneurysm (yellow star) with surrounding hematoma.

patient, copious blood clots extruded at the thinned-out portion of the back neurofibroma (Figure 12). This was controlled for 24 hours by compressive dressing. She was subsequently transfused with leukoreduced blood products in preparation for her second operation. The post-embolization ruptured aneurysm was classified as Grade 3B under the Clavien-Dindo classification.

Complete resection of the back and necrotic part of postauricular neurofibroma was scheduled on her 7th post-operative day (Figure 13). After transfusions, her Hgb rose to 100 g/L. Her blood pressure, heart rate, and

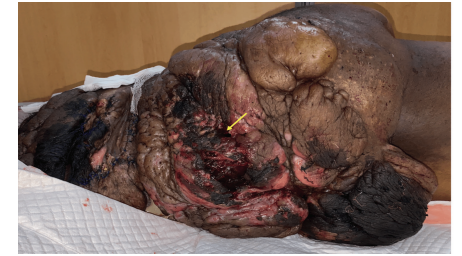


Figure 12. Back neurofibroma where copious blood clots were extruded at its thinned-out portion (yellow arrow) after transport from CT scan unit.

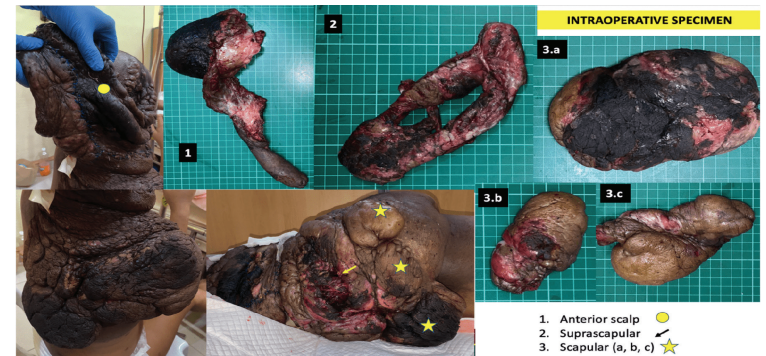


Figure 13. Back (suprascapular and scapular) and necrotic portion of postauricular neurofibroma resected at second operation. 1) anterior/postauricular necrotic portion (12cm x 10cm), 2) suprascapular (15cm x 7cm), 3) scapular neurofibroma (18cm x 13cm, 8cm x 5cm and 15cm x 10cm).

urine output were normal. The patient was positioned semi-prone on the operating table. The back mass was resected using the combination of clamping of the base of each neurofibroma, the small jaw energy sealing device and a hemostatic interlocking retention nylon suture to

control any bleed and close the skin primarily (Figure 14). The saccular aneurysm was located at the suprascapular artery and was suture ligated (Figure 15) by the vascular surgeons working with the team. Negative suction drains were inserted at the back and neck potential space.

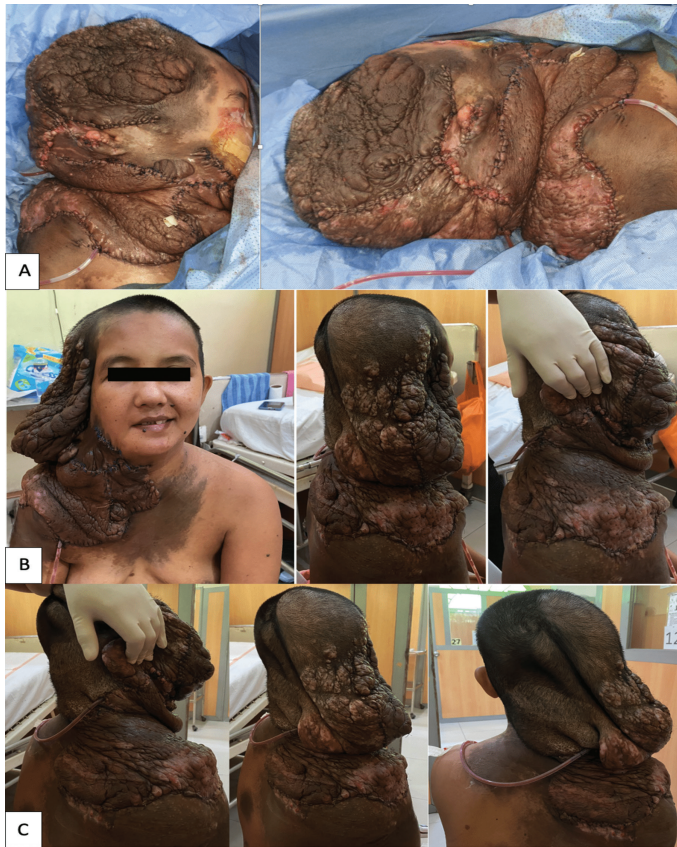

Figure 14. A) Skin and subcutaneous area closed using hemostatic interlocking suture. B) Front view, C) Dorsal view of patient after resection of neurofibroma.

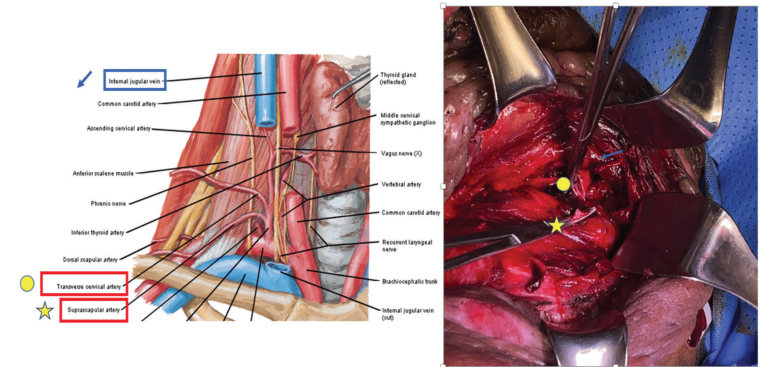


Figure 15. Ligated suprascapular artery pseudoaneurysm. Internal jugular vein (blue arrow), Transverse cervical artery (yellow circle), Suprascapular artery (yellow star). Picture diagram from Atlas of Human Anatomy by Frank Netter.⁴¹

Combined total blood loss for the two operation was 4 liters. Six units of leukoreduced packed red blood cell and frozen fresh plasma were transfused intraoperatively. The patient required neither delayed extubation nor intensive care unit monitoring post-operatively. The rest of the patient hospital course was unremarkable. Wounds were dressed with bacitracin ointment and chlorhexidine acetate medicated paraffin dressings (Bactigras; Smith+Nephew, Watford, UK). No surgical site infection developed. Drains were removed after three weeks.

Discussion

Dangerous bleeding during surgical removal of giant plexiform neurofibroma has been well documented in case reports and series.¹⁹ McDowell (1968) is one of the first to recognize the potential for hemorrhage of this condition, giving it the term "Quasimodo's tumor".²⁰ Mukherji (1974) observed the extreme friability of the blood vessels and attributed it to myxomatous degeneration.^{21,22,23} Grabb, et al. (1980) also documented this in their experience with facial neurofibroma.²⁴ McMaster (1972) reported an instance of massive

spontaneous bleeding of elephantiasis neurofibroma in lumbar region.²⁵

A study by Littlewood and Stillwell in 1983 was one of the first to demonstrate the likelihood of massive bleeding during giant plexiform neurofibroma resection due to the presence of abnormal feeding vessels.²⁶ They described a series of 5 patients, in which angiography had revealed an abnormal vascular pattern in 3. They reported having difficulty in achieving hemostasis in these cases. They recommended a routine angiographic examination of all patients presenting with plexiform neurofibroma to identify lesions with abnormal vascular pattern and utilization of preoperative arterial embolization prior surgery. Indeed, most reports that are able to successfully resect giant PNs utilized preoperative embolization.²⁷⁻²⁹ It is also important to be aware that though arterial embolization (AE) can control intraoperative hemorrhage, it has its own inherent risks. Possible complications of AE include severe headache, fever, hematoma, pulmonary embolism, stroke, pseudoaneurysm, AV fistula, uncontrolled necrosis and sepsis, and a higher risk of post-surgical site infection.³⁰⁻³²

Timing of surgery after arterial embolization has not been well established due to variability of the type of

tumors where this technique is employed. Tang, Ji, Guo et al, recommended that surgery be done at least 24 hours after embolization to observe for any post-embolization complication in order not to misdiagnose these as surgical complications.³³ Tumor size, target tumor shrinkage, completeness of embolization, extent of revascularization and collateralization, type of embolizing agent are factors to consider when determining the time delay from embolization to surgery. Some study supports short interval of 1-7 days between embolization and resection due to subsequent collateralization and revascularization of tumor should surgery be delayed.³⁴ Two studies reported that intraoperative blood loss tended to be greater when surgery was performed more than 3 days after embolization.³⁵ In some studies where it was important to balance the risk of cutaneous necrosis and risk of bleeding, a 5-day time delay was followed to optimize the effect of preoperative embolization, to better assess skin condition, and the best options for postoperative skin coverage.³⁶ The patient in the present case underwent her first operation before third day post-embolization and her second operation on tenth day post-embolization. Both operations had manageable and comparable blood loss. The silver lining in doing the second stage operation at a later date (5th to 7th day post-embolization) was that it allowed the cutaneous necrosis from embolization to demarcate viable resection margins.

Velez and Ochoa, et al. in 2013, utilized both preoperative double sequential embolization and intraoperative use of linear cutting stapler system to assist in hemostasis during surgical resection of lower back and buttock PNs of a 22-year-old female.³⁶ Besides the presence of abnormal vascular pattern seen in Littlewood and Stillwell studies, it is postulated that the hemorrhages are caused by rupture of friable vasculature secondary to arterial dysplasia or vascular invasion by the neurofibroma.³⁷ The linear stapler approach was based on Allison, Ahlmann et. al study in 2009, where they utilized cutting stapler to reduce surgical time and blood loss with muscle transection.³⁸ The authors realized that though these studies utilized the cutting stapler for musculoskeletal lesions, the intraoperative characteristic of the scalp neurofibroma of their patient fits similar profile. It was composed of large friable vessels in between thickened nerve fibers.

The authors utilized four techniques to minimize blood loss in their case—preoperative arterial embolization, an energy sealing device, a cutting linear stapler, and retention interlocking sutures. Diathermy played no hemostatic role during surgery.

Energy sealing device and retention interlocking suture allowed good hemostasis at the level of the skin, subcutaneous tissue and friable vessels that are difficult to control by electrocautery and ligation. The disadvantages are longer healing time due to burnt skin edge and difficulty in skin suture removal.

Cutting linear stapling allowed hemostasis in thicker tissues where friable vessels can retract in between neurofibroma fibers. Its use is limited by the cost of the device. The authors utilized ten 75mm linear loads for the scalp and chest neurofibroma.

Preoperative arterial embolization allowed a more manageable blood loss during the operation, the decrease in weight of the mass due to decrease in its vascularity allowed for better handling, manipulation and positioning of the patient. It was difficult to control the sequelae of embolization. The patient experienced headache, mild fever 24 hours after embolization, technical difficulties during embolization risked the possibility of aneurysm such as in our case, and lastly, the skin necrosis as an expected result of embolization also meant a committed step in resection of that area. The possibility of postoperative skin flap necrosis progression³⁹ and high infection rate⁴⁰ especially for those embolized with particulate embolic agent has been reported in other series.

Conclusion

Resection of giant plexiform neurofibroma requires serious consideration of indications and possible complications. The most notorious complication, life-threatening intraoperative bleeding, can be successfully managed by preoperative arterial embolization, energy sealing device, retention interlocking suture and/or linear cutting staplers.

Acknowledgements

The authors are grateful to their patient for trusting them to do the surgery and share her case with the medical

community. They would like to acknowledge the help of Dr Patrick See, Dr. Juan Silvestre Pascual and Dr. Aristeo Poncio from the department of Thoracocardiovascular Surgery, Neurosurgery and Plastic Surgery, respectively, during surgery and in taking care of the patient.

References

- Huson SM, Hughes RA. The Neurofibromatosis: A Pathogenetic and Clinical Overview. London: Chapman and Hall Medical. 1994.
- Ferner RE, Gutmann DH. International consensus statement on malignant peripheral nerve sheath tumors in neurofibromatosis. *Cancer Res* 2002 Mar 1; 62(5):1573-7.
- Patil K, Mahima VG, Shetty SK, Lahari K. Facial plexiform neurofibroma in a child with neurofibromatosis type I: a case report. *J Indian Soc Pedod Prev Dent* 2007 Mar; 25(1): 30-5.
- Bredella MA, Torriani M, Hornicek F, et al. Value of PET in the assessment of patients with neurofibromatosis type 1. *AJR* 2007; 189: 928–35.
- Tchernev G, Chokoeva AA, Patterson JW, Bakardzhiev I, Wollina U, Tana C. Plexiform neurofibroma: A case report. *Medicine (Baltimore)* 2016 Feb; 95(6):e2663.
- Dogra B, Rana K. Facial plexiform neurofibromatosis: A surgical challenge. *Indian Dermatol Online J* 2013 July-Sept; 4(3): 195-8.
- Kleinhues P, Cavenee WK. Lyon. Tumours of the nervous system. In World Health Classification of Tumours. IARC Press Lyon. 2000.
- Needle MN, Cnaan A, Dattilo J, et al. Prognostic signs in the surgical management of plexiform neurofibroma: the Children's Hospital of Philadelphia experience, 1974–1994. *J Pediatr* 1997; 131: 678–82.
- Sabatini C, Milani D, Menni F, et al. Treatment of neurofibromatosis type 1. *Curr Treat Options Neurol* 2015; 17: 355.
- Yuan SM, Cui L, Guo Y, et al. Surgical management of giant neurofibroma in soft tissue: a single-center retrospective analysis. *Int J Clin Exp Med* 2015; 8(4): 5245-53.
- Wise J, Cryer J, Belasco J. Management of Head and Neck Plexiform Neurofibroma in Pediatric Patients with Neurofibromatosis type 1. *Arch Otolaryngol Head Neck Surg* 2005; 131(8): 712-8.
- Friedrich RE, Schmelzle R, Hartmann M, et al. Resection of small plexiform neurofibromas in neurofibromatosis type 1 children. *World J Surg Oncol* 2005; 3(1):6.
- Ergun SS, Emel E, et al. Extracranial diffuse neurofibroma with intracranial extension. *Plast Reconstr Surg* 2000; 105(2): 801–3.
- Nguyen R, Ibrahim CM, Friedrich R, et al. Growth behavior of plexiform neurofibromas after surgery. *Gen Med* 2013 April; 15: 691-7.
- Prayson RA. *Neuropathology: A Volume in the Foundations in Diagnostic Pathology Series*. New York: Churchill Livingstone 2005; 159-61.

- Bredella MA, Torriani M, Hornicek F, et al. Value of PET in the assessment of patients with neurofibromatosis type 1. *AJR* 2007; 189: 928–35.
- Gutmann DH, Aylsworth A, Carey AJ et al. The diagnostic evaluation and multidisciplinary management of neurofibromatosis 1 and neurofibromatosis 2. *JAMA* 1997; 278(1): 51–7.
- Neurofibromatosis. NIH Consensus Statement 1987 Jul 13-15; 6(12): 1–19.
- Kashyap RR, Gogineni SB. Hypervascular neurofibromas in a case of neurofibromatosis type 1 - a case report. *J Clin Exp Dent* 2011; 3(1):e356–e359.
- McDowell F. Facial Hamartoma or Quasimodo's tumor. (Editorial). *Plast Reconstr Surg* 1968; 42: 369.
- Mukherji MM. Giant neurofibroma of the head and neck. *Plast Reconstr Surg* 1974 Feb; 53(2): 184-9.
- White N, Gwanmencia I, Akhtar N, Withey SJ. Severe haemorrhage in neurofibromatoma: a lesson. *Br J Plast Surg* 2004; 57(5): 456-7.
- Poston GJ, Grace PA, Venn G, Spencer J. Recurrent near-fatal haemorrhage in von Recklinghausen's disease. *Br J Clin Pract* 1990; 44(12): 755-6.
- Grabb WC, Dingman RO, Oneal RM, Dempsey PD. Facial hamartomas in children: neurofibroma, lymphangioma and hemangioma. *Plast Reconstr Surg* 1980; 66: 509.
- McMaster P. Massive haemorrhage in elephantiasis neurofibroma. *Br J Surg* 1972; 59: 984.
- Littlewood AHM, Stilwell JH. The vascular features of plexiform neurofibroma with some observations on the importance of preoperative angiography and the value of pre-operative intra-arterial embolization. *Br J Plast Surg* 1983; 36: 501–6.
- Kolker S, Wunder JS, Roche G. Hybrid resection of a giant thigh plexiform neurofibroma. *Int J Surg Case Rep* 2015; 8: 1-4.
- Jones RG, Kiatischev P, D. C. Morris DC, Munk PL, Clarkson PW, and Masri BA. Intravascular embolisation and surgical resection of a giant neurofibroma with intratumoural haemorrhage. *Br J Radiol* 2010; 83(995): e225–9.
- Tsutsumi M, Kazekawa K, Tanaka A, et al., Rapid expansion of benign scalp neurofibroma caused by massive intratumoral hemorrhage: case report. *Neurologia Medico-Chirurgica* 2002; 42(8): 338–40.
- Cavallaro G, Pedulla G, Crocetti D, D'ermo G, et al. Vacuum-assisted closure treatment of leg skin necrosis after angiographic embolization of a giant plexiform neurofibroma. *CIC Edizioni Intentional G Chir* 2012; 33: 239-42.
- Bilbao J, Martinez-Cuesta, et al. Complications of embolization. *Semin Intervent Radiol* 2006 Jun; 23(2): 126-42.
- Zhou J, Li M, Luo C, He Q, et al. Giant neurofibroma in the right lower limb of a 26-year-old woman: Report of case. *Int Surg* 2012; 97(1): 71-7.
- Tang B, Ji T, Guo W, et al. Which is the better timing between embolization and surgery for hypervascular spinal tumors, the same day or the next day. *Medicine* 2018; 97: 23(e10912).
- Rosen CL, Ammerman JM, Sekhar LN, Bank WO. Outcome analysis of preoperative embolization in cranial base surgery. *Acta Neurochir (Wien)* 2002; 144: 1157–64.

35. Pikiş S, Itshayek E, Barzilay Y, et al. Preoperative embolization of hypervascular spinal tumors: current practice and center experience. *Neurol Res* 2014 Jun; 36(6): 502-9.
36. Vélez R, Barrera-Ochoa S, Barastegui D, Pérez-Lafuente M, Romagosa C, Pérez M. Multidisciplinary management of a giant plexiform neurofibroma by double sequential preoperative embolization and surgical resection. *Case Reports in Neurological Medicine* 2013; 1-8.
37. Prada CE, Rangwala FA, Martin LJ, et al. Pediatric plexiform neurofibromas: impact on morbidity and mortality in neurofibromatosis type 1. *J Pediatr* 2012; 160: 461-7.
38. Allison DC, Ahlmann ER, Xiang AH, and Menendez LR. The linear cutting stapler may reduce surgical time and blood loss with muscle transection: a pilot study. *Clin Orthop Rel Res* 2009; 467(11): 2859- 64.
39. Ross AL, Panthaki Z, and Levi AD. Surgical management of a giant plexiform neurofibroma of the lower extremity. *World Neurosurg* 2011; 75(5-6): 754-7.
40. MacLaren JA. Skin changes in lymphoedema: pathophysiology and management options. *Int J Palliat Nurs* 2001; 7(8): 381-8.
41. Netter FH. *Atlas of Human Anatomy*. Saunders.7th edition. 2018.