

## CASE REPORT

# Inflammatory Myofibroblastic Tumor of the Urinary Bladder: A Prognostically Favorable Spindle Cell Neoplasm

John Carlo V. Laylo, MD and Neddy L. Lim, MD, FPUA

*Department of Urology, Jose R. Reyes Memorial Medical Center*

Inflammatory myofibroblastic tumors (IMT) are rare, benign spindle cell neoplasms of the urinary bladder with a presentation similar to that of a malignant disease. Oftentimes, these tumors pose a diagnostic dilemma because of a significant overlap with malignant spindle cell tumors in terms of clinical presentation, gross findings and immunohistopathologic profile. Due to its rarity, there are no guidelines regarding treatment and follow up. Reporting cases of IMT will bring awareness to the features of these rare tumors, and will help in overcoming limitations in diagnosis, and treatment protocols. Presented here is a case of a 28-year-old female who presented with gross hematuria. Upon work up, revealed the presence of a bladder mass. Patient underwent transurethral resection, then a partial cystectomy, and pathology demonstrated an IMT.

**Keywords:** Inflammatory myofibroblastic tumor, urinary bladder, spindle cell neoplasm

### Introduction

Spindle cell lesions of the urinary tract are all rare and encompass a variety of benign and malignant tumors which vary greatly in their behavior, ranging from indolent lesions to highly aggressive tumors.<sup>1</sup> They account for a small but frequently challenging subset of cases due to their rarity and limited data regarding long term follow-up. These lesions are categorized as: 1) non-neoplastic mesenchymal proliferations including inflammatory myofibroblastic tumor (IMT) and post-operative spindle cell nodule, 2) benign mesenchymal tumors such as leiomyoma, 3) malignant mesenchymal tumors such as leiomyosarcomas, rhabdomyosarcomas, and 4) sarcomatoid carcinoma - carcinomas with spindle cell component.<sup>1</sup> Spindle cell lesions of the urinary bladder may pose a diagnostic challenge

when encountered because there is considerable morphologic and immunohistopathologic overlap.<sup>2,3</sup>

Inflammatory myofibroblastic tumors are uncommon benign neoplasms of the bladder characterized by spindle cell proliferation with characteristic fibroinflammatory and pseudosarcomatous appearance. For this reason, many different names have been assigned to this pathology including inflammatory pseudotumor, pseudosarcoma, nodular fasciitis, plasma cell granuloma, and pseudomalignant spindle cell proliferation.<sup>2</sup> Since its first documentation in the 1980's, these tumors remain to have an unclear etiology, and an unknown malignant potential.<sup>2</sup> IMT's are often confused with other malignant spindle cell tumors based on their similar cell morphology.<sup>2,3</sup> Hence, it is of paramount importance that these lesions be differentiated from sarcomas of the urinary

bladder to avoid unnecessary chemotherapy or radical surgeries and their deleterious consequences. Reporting cases of IMT will bring awareness to the features of these rare tumors, and will help in overcoming limitations in diagnosis, and treatment protocols.

Herein, is a case of a 28 years old female diagnosed with Inflammatory myofibroblastic tumor arising from the urinary bladder.

## The Case

This is the case of a 28-year old female with 3-month history of episodes of gross hematuria with passage of blood clots and dysuria. She had a cesarean section 3 months prior to onset of hematuria. She is a non-smoker, with no history of genitourinary malignancy in the family. Blood and urine investigations were unremarkable. After consultation, patient had a ultrasound which revealed a solid urinary bladder mass located at the supero-anterior wall, measuring 3.2cm x 3.2cm x 3.1cm (Figure 1A). Computed Tomography (CT) scan was subsequently done which showed a well-defined, heterogeneously enhancing, intraluminal mass, arising from the right superior-anterior wall of the urinary bladder, measuring 4.3cm x 4.7cm x 4.6cm

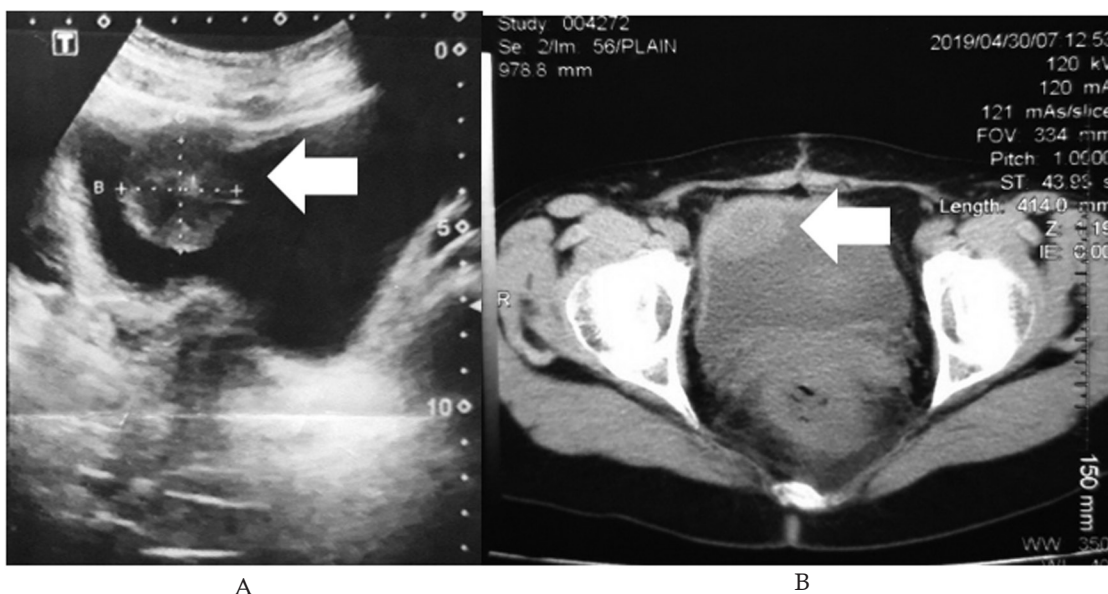
(Figure 1B). No extravesical component was seen in the CT scan.

Cystoscopy, transurethral resection of bladder tumor was then performed. Intraoperative findings revealed a mass involving the right superior bladder wall (Figure 2A). Histopathologic examination revealed edematous spindle cells with traces of thickened transitional epithelial lining, consistent with a spindle cell bladder tumor (Figure 3A).

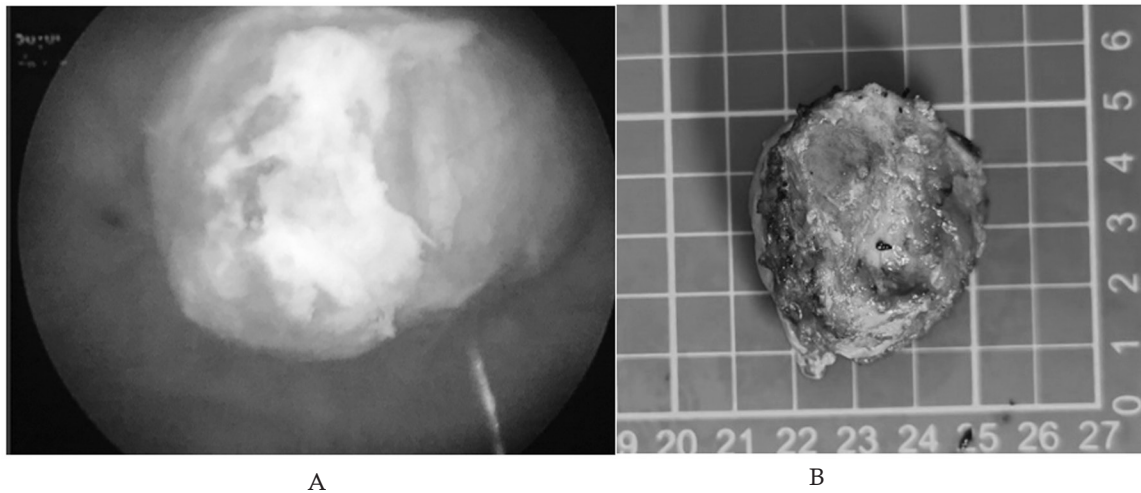
Patient subsequently underwent partial cystectomy 2 months after. The gross specimen revealed a 4cm x 4cm light to dark brown, fairly ovoid mass, encased by a pink fibromuscular membrane (Figure 3B). Microscopic findings revealed spindle cells with mixed inflammatory infiltrates involving the mucosa, submucosa and some portions of the muscle layer, without involvement of the adjacent bladder wall and the urachus. Immunohistochemical evaluation revealed positive staining for anaplastic lymphoma kinase (ALK) (Figure 3B), smooth muscle actin (SMA) and desmin. Negative staining was noted for myogenin. These results were consistent with the diagnosis of IMT.

## Discussion

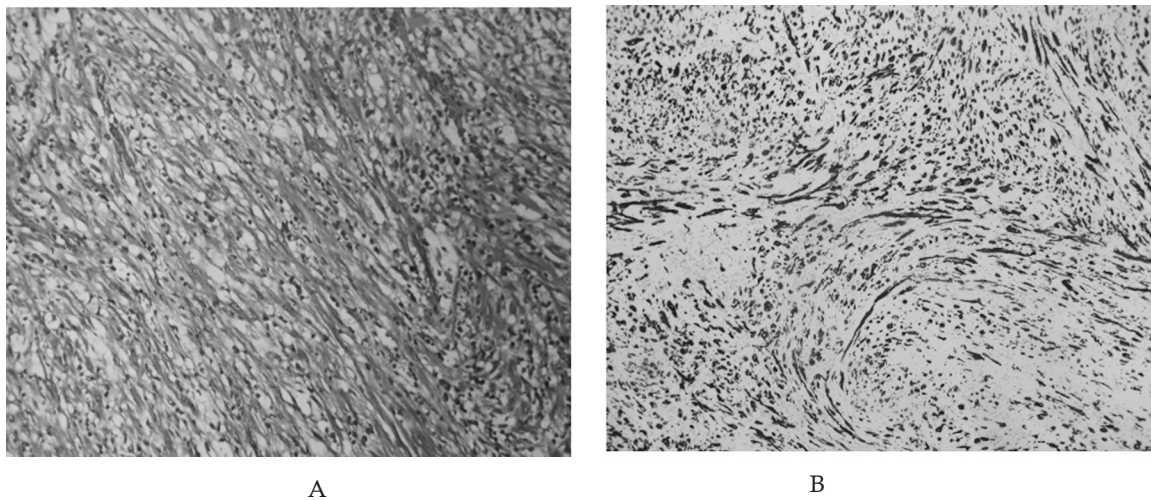
IMT's are uncommon benign spindle cell lesions of unclear etiology and malignant potential. Cases



**Figure 1.** Preoperative imaging studies of the bladder mass (indicated by arrow). A) Ultrasound, B) Computed tomography (CT) scan



**Figure 2.** Intraoperative images of the bladder mass. A) Cystoscopic appearance B) Gross specimen



**Figure 3.** Histopathologic findings A) Spindle cells in a background of transitional epithelial lining, B) Positive ALK staining

have been reported in multiple anatomic locations, with the most frequent site being the lungs. To this point, reports of IMT of the urinary tract have been very limited and most cases are only presented in case reports and small-scale studies.<sup>2</sup> These tumors are most commonly observed in adults who are in their 20's to 40's, with a slight female predominance. The most common presenting symptom is hematuria followed by irritative voiding symptoms, and lower abdominal pain. Currently, there are no known predisposing factors for the development of these lesions. However, previous literatures suggest

associations of IMT with infection, trauma, and previous surgery prior to development.<sup>2,3</sup> In the present case, the likely risk factor is the patient's history of a previous cesarean section three months prior to the onset of hematuria.

IMTs of the urinary bladder are characterized by atypical spindle cell proliferation, accompanied by inflammatory cell infiltrate comprised primarily of lymphocytes and plasma cell. These tumors exhibit morphologic and immunohistopathologic overlap with malignant spindle cell tumors such as leiomyosarcoma, rhabdomyosarcoma and

sarcomatoid carcinoma.<sup>1,3</sup> Hence, diagnostic distinction can be problematic at times because epithelial and myogenic markers can be both expressed in IMT. Final and definitive diagnosis can only be made by immunohistopathologic studies.<sup>1,3</sup> Grossly, IMT presents with lesions, either a polypoid mass or a submucosal nodule. These tumors may or may not cause surface ulcerations and the cut surface is often pale, firm and glistening. Histologically, there is a proliferation of spindle cells with elongated eosinophilic cytoplasmic processes in a loose edematous or myxoid background.<sup>1,3</sup> Immunohistochemical staining may demonstrate positive results for ALK, SMA, desmin, cytokeratin, p53 and vimentin.<sup>3</sup> The most defining feature of IMT is the positive immunostaining for ALK. ALK was originally identified as a protein over expressed in anaplastic large cell lymphomas, but was also found to be over expressed in a substantial proportion of IMT.<sup>4</sup> A positive finding of ALK by immunohistochemistry has been identified in 89% of IMT's in the urinary bladder which can be useful in differentiating it from other malignant spindle cell tumors.<sup>5</sup> A study by Cessna, et al. noted ALK to be negative in cases of sarcomatoid carcinoma, leiomyosarcoma, rhabdomyosarcoma and neurofibromas examined from the urinary bladder.<sup>6</sup> In addition, the vast majority of IMT's are negative for CD21, CD34, CD35 and myogenin. Based on a systematic review of 186 cases of IMT by Theo et al, immunohistochemical staining for IMT has positive results for ALK (65%), Vimentin (96.3%), p53 (77.8%), CK AE1/AE3 (75.3%), SMA (71.9%) and desmin (43.8%). In addition, all cases were negative for Myogenin, CD21, CD34 and CD35.<sup>5</sup> In the case presented here, immunohistochemical staining was positive for ALK, SMA and Desmin, but negative for myogenin. This is consistent with the findings of Theo, et al. These immunohistochemical studies, whenever feasible, should be carried out in all cases of spindle cell tumor of the urinary bladder to avoid overdiagnosis with the malignant spindle cell carcinoma which it closely resembles. Not doing so can lead to deleterious consequences of treatment with radical surgeries and chemotherapy.

IMT of the urinary tract has been associated with a more indolent course and a relatively good prognosis due to its low risk of distant metastasis. However, due to limited cases documented in the

literature, no current guideline regarding treatment strategy for managing IMT. Complete local resection with negative surgical margin at pathology is the preferred treatment. This can be achieved by transurethral resection, if the tumor is superficial, and by partial cystectomy if it is not.<sup>3,5</sup> Of the 182 patients in Teoh, et al.'s systematic review, 60.8% were treated with TURBT, 29.2% with partial cystectomy and 9.2% with radical cystectomy. Despite a typically benign course, 5 of these 182 patients developed local recurrences, representing an overall local recurrence rate of 2.7%. Two of these five recurrences occurred within a 6-month window after the primary excision and required treatment with a second TURBT. Only one single case of metastases related to IMT was reported.<sup>5</sup> As in the present case, transurethral resection was done to establish the diagnosis and subsequently a partial cystectomy was performed for complete surgical resection.

## Conclusion

IMT is a benign neoplasm that presents similarly to malignant spindle cell tumors of the urinary bladder. Differentiation from malignant spindle cell tumors through immunohistopathologic studies is of paramount importance to avoid overdiagnosis and the consequence of treatment with radical surgeries and chemotherapy. IMT can be locally aggressive and complete local resection through transurethral resection or partial cystectomy is the more advisable treatment. Due to their unknown malignant potential, these tumors warrant close follow-up with CT scans and surveillance cystoscopy.

## References

1. Bostwick D and Cheng L. Urologic surgical pathology. 2014; New York, NY: Elsevier Health Sciences
2. Montgomery E, Shuster D, Burkart A, Esteban J, Sgrignoli A, et al. Inflammatory myofibroblastic tumors of the urinary tract: A clinicopathologic study of 46 cases including a malignant example inflammatory fibrosarcoma and as subset associated with high-grade urothelial carcinoma. *Am J Surg Pathol* 2006; 30(1): 1502-12.
3. Gleason B and Hornick J. Inflammatory myofibroblastic tumors: Where are we now? *J Clin Pathol* 2008; 61(1): 428-37.

4. Rao R, Ranjan P, Singla P, Pandey R. Inflammatory myofibroblastic tumor of the urinary bladder diagnosed by anaplastic lymphoma kinase immunostaining. *Urol Ann* 2012; 42(1): 115-8.
5. Teoh J, Chan N, Cheung H, Ming Hou S, Ng C, et al. Inflammatory myofibroblastic tumors of the urinary bladder: A systematic review. *Urology* 2014; 84(1): 503-8.
6. Cessna M, Zhou H, Sanger W, Perkins S, Tripp S, Pickering D, et al. Expression of ALK 1 and p80 in inflammatory myofibroblastic tumor and its mesenchymal mimics: a study of 135 cases. *Mod Pathol* 2002; 15(9): 931-8.