



Claudette Gloria T. Plumo, MD  
Emmanuel Tadeus S. Cruz, MD

Department of Otorhinolaryngology  
Head and Neck Surgery  
Quezon City General Hospital

## Fatal Otitic Hydrocephalus Due to Sinus Thrombosis: A Case Report

### ABSTRACT

**Objective:** To report a case of chronic suppurative otitis media with complications of lateral sinus thrombosis and otitic hydrocephalus and to discuss its clinical manifestations, clinical course, ancillary procedures and management.

### Methods:

**Design:** Case Report  
**Setting:** Tertiary Government Training Hospital  
**Patient:** One

**Result:** A 35-year-old man was admitted due to intermittent right otorrhea for 20 years and headache for a month. The Glasgow Coma Scale (GCS) score was 12, and mastoidectomy performed on the second hospital day showed cholesteatoma with erosion of the bony covering of the sigmoid sinus with scanty purulent discharge. The GCS improved to 15 few hours post-operatively, however, 24 hours post-operatively, GCS decreased from 15 to 10 and a CT scan showed dilatation of cerebral ventricles and lateral sinus thrombosis which persisted on subsequent imaging studies. His condition deteriorated irreversibly despite a ventriculostomy, and he eventually expired after 3 weeks in the ward.

**Conclusion:** Otitic hydrocephalus due to lateral sinus thrombosis is a serious complication of chronic suppurative otitis media seldom encountered nowadays. In this case, otitic hydrocephalus developed and progressed despite broad spectrum antibiotics, mastoidectomy and a ventricular shunt. This case report underscores the importance of early recognition of warning signs of intracranial complications to institute prompt management.

**Keywords:** *chronic suppurative otitis media; lateral sinus thrombosis; otitic hydrocephalus; mastoidectomy; ventriculostomy*

**Chronic suppurative otitis media (CSOM)** has a prevalence of around 2.5-29.4% in the Philippines, 2-6% in African countries, and below 1% in USA and Europe.<sup>1</sup> Intracranial complications of CSOM include extradural and subdural abscess, meningitis, otogenic brain abscess and lateral or sigmoid sinus thrombophlebitis. Among these, lateral sinus thrombophlebitis may lead to otitic hydrocephalus, a life-threatening complication rarely encountered in past decades with a prevalence of 1 to 8%.<sup>2-5</sup> We present our experience of otitic hydrocephalus due to lateral sinus thrombosis that led to the demise of our patient despite surgery and antibiotic coverage.

Correspondence: Dr. Emmanuel Tadeus S. Cruz  
Department of Otorhinolaryngology  
Head and Neck Surgery  
Quezon City General Hospital  
Seminary Road, EDSA, Quezon City 1106  
Philippines  
Phone: +63 908 872 8655  
Email: emancrz@yahoo.com

The authors declared that this represents original material that is not being considered for publication or has not been published or accepted for publication elsewhere in full or in part, in print or electronic media; that the requirements for authorship have been met by all the authors, and that each author believes that the manuscript represents honest work. Disclosures: The authors signed a disclosure that there are no financial or other (including personal) relationships, intellectual passion, political or religious beliefs, and institutional affiliations that might lead to a conflict of interest.

Presented at the Philippine Society of Otolaryngology - Head and Neck Surgery 2nd Virtual Interesting Case Contest (1st Place), June 23, 2021.



Creative Commons (CC BY-NC-ND 4.0)  
Attribution - NonCommercial - NoDerivatives 4.0 International

### CASE REPORT

A 35-year-old man was admitted with a chief complaint of bloody right ear discharge and headache. A month prior, the patient manipulated his right ear resulting in bloody discharge and otalgia. Nine days prior to admission, he consulted at the outpatient clinic where otoscopy showed a perforated tympanic membrane with yellowish discharge and granulation tissue in the right ear canal. The patient was diagnosed with CSOM, and antibiotic otic drops were prescribed while a temporal bone computed tomography (CT) scan and audiometry were requested. He returned to the emergency room that night because of otalgia and a throbbing, right frontotemporal headache. Analgesics, otic drops, and Cefuroxime were prescribed. Two days later, the patient came back to the outpatient department because of right temporal headache (4/10), vomiting, fever, and nape pain, prompting admission.

The patient had stable vital signs but was in pain and drowsy, responding to questions occasionally. He was coherent and oriented to person and place. Otoscopy revealed an 80-90% tympanic membrane perforation, with granulation tissue over the right anterior malleolar fold, pars flaccida, and lateral process of the malleus and purulent yellowish discharge from the right ear. (Figure 1) Neurologic examination showed Glasgow Coma Scale (GCS) score of 12, with pupils briskly reactive to light, full extra-ocular muscle (EOM) motion, and no facial asymmetry. He had right upper extremity weakness (4/5) and weak lower extremities (3/5). There were no sensory deficits but positive Kernig's and Brudzinski's signs.

The admitting impression was bacterial meningitis secondary to CSOM, right ear, to consider brain abscess. The temporal bone CT scan revealed soft tissue densities in the right external auditory canal, middle ear, antrum and mastoid air cells. There was lysis of the right ossicular chain and erosive changes in the right pyramidal eminence, mastoid air cells, and sigmoid plate (Figure 2) for a radiologic impression of chronic otomastoiditis with cholesteatoma. The internal medicine and neurology services considered a diagnosis of cavernous sinus thrombosis (advising a lumbar tap, Ceftriaxone, Vancomycin,

and Tramadol); while the neurosurgery service considered meningitis versus brain abscess secondary to CSOM.

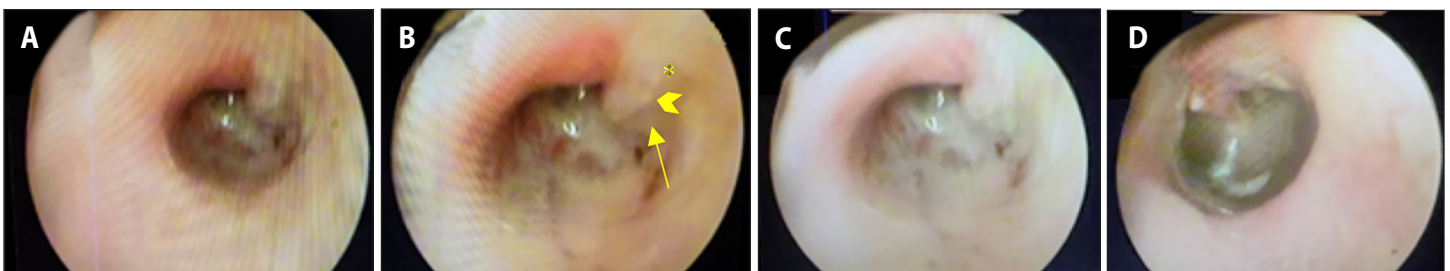
On the first hospital day, GCS improved from 12 to 15, and he was oriented to 3 spheres with headache 7/10. Cranial CT with contrast showed deep venous thrombosis and right chronic otomastoiditis with cholesteatoma. (Figure 3) Lumbar tap showed elevated cerebro spinal fluid (CSF) opening pressure of 270 mm H<sub>2</sub>O, decreased glucose, and increased protein content.

He underwent emergency canal wall down mastoidectomy under general anesthesia the next day. Intraoperative findings showed exposure of 2.5 cm of the sigmoid sinus with the bony covering eroded. (Figure 4) Slight purulent discharge drained around the sinus but no attempt was made to violate, incise, or manipulate the vessel. Brain abscess cultures revealed no growth after 3 days while culture of the right ear discharge showed moderate growth of *Proteus mirabilis*.

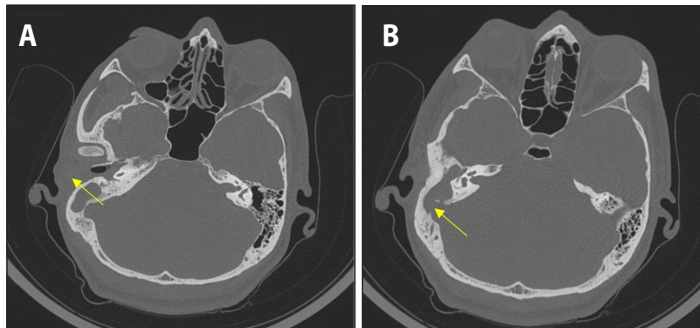
Twenty four hours postoperatively, the patient was confused and could not follow commands. His GCS decreased to 10 with sluggish pupillary light reflex, with both eyes fixed on right lateral gaze. Repeat CT scan on the second post-op day showed marked dilatation of the third and lateral ventricles due to compression of the fourth ventricle, swelling of the right cerebellum with diffuse cerebral edema, and transependymal seepage. (Figure 5) The neurosurgery service considered meningitis versus abscess and Acetazolamide was given. He underwent ventriculostomy and evacuation of abscess on the fourth post-operative day. Post-operatively, there was transient improvement in GCS from 10 to 14 before reverting back to drowsiness. Although CSF fluid was drained via the ventriculostomy tube for several days, no apparent improvement was observed until the tube was removed. Subsequently, his condition deteriorated until the patient expired after 3 weeks of hospital stay.

### DISCUSSION

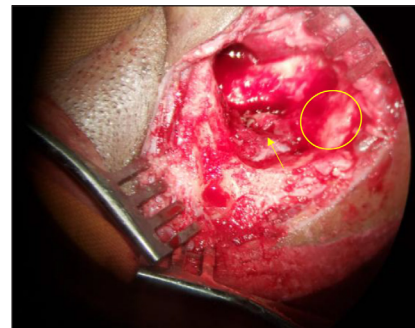
Chronic middle ear infection left untreated may progress posteriorly towards the sigmoid sinus or posterior cranial fossa, which may lead to lateral sinus thrombophlebitis.<sup>6</sup> Erosion of the mastoid bone may be



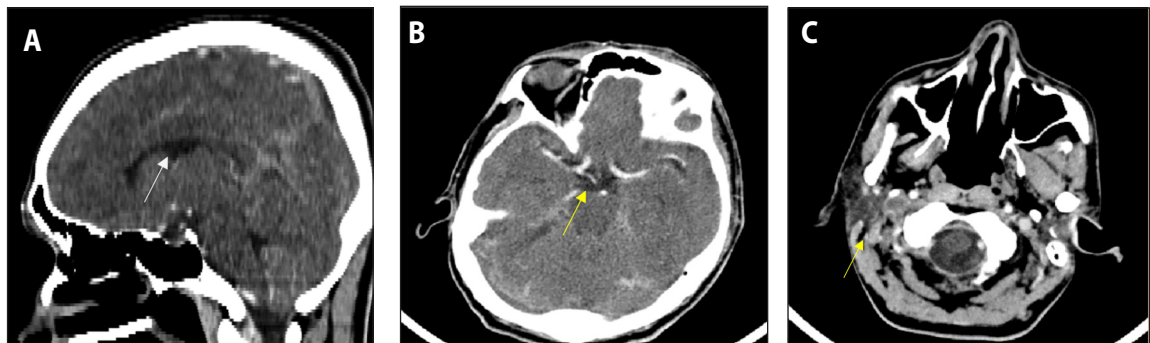
**Figure 1.** Otoscopy showing: **A.** 80-90% tympanic membrane perforation with **B.** granulation tissue in the right anterior malleolar fold (arrow), pars flaccida (asterisk), and lateral process of the malleus (arrowhead) and **C.** thick, purulent yellowish discharge in the right ear. **D.** the intact left tympanic membrane is shown for comparison.



**Figure 2.** Temporal bone CT scans (bone window, axial view) obtained 6 days prior to admission revealing: **A.** expansile soft tissue mass occupying the right external auditory canal, middle ear, antrum, and mastoid air cells (arrow). The ipsilateral tympanic membrane is not appreciated and there is: **B.** lysis of the right ossicular chain and erosive changes in the right pyramidal eminence, mastoid air cells, and sigmoid plate (arrow).



**Figure 4.** Intraoperative findings on mastoidectomy showing 2.5 cm of the sigmoid sinus exposed with eroded bony covering (arrow), slight purulent discharge draining around the sinus, and the remaining incus filled with granulation tissue and cholesteatoma (circle).



**Figure 3.** Cranial CT scans with contrast on admission; **A.** sagittal view; and **B.** axial view; showing dilatation of the ventricles (arrows); and **C.** axial view, showing deep venous thrombosis (arrow) and right chronic otomastoiditis with cholesteatoma formation.

due to osteolytic enzymes such as catalase<sup>7</sup> and collagenase, allowing digestion by other proteases.<sup>8</sup> This can explain the erosion of the bony covering of the sigmoid sinus seen intraoperatively.

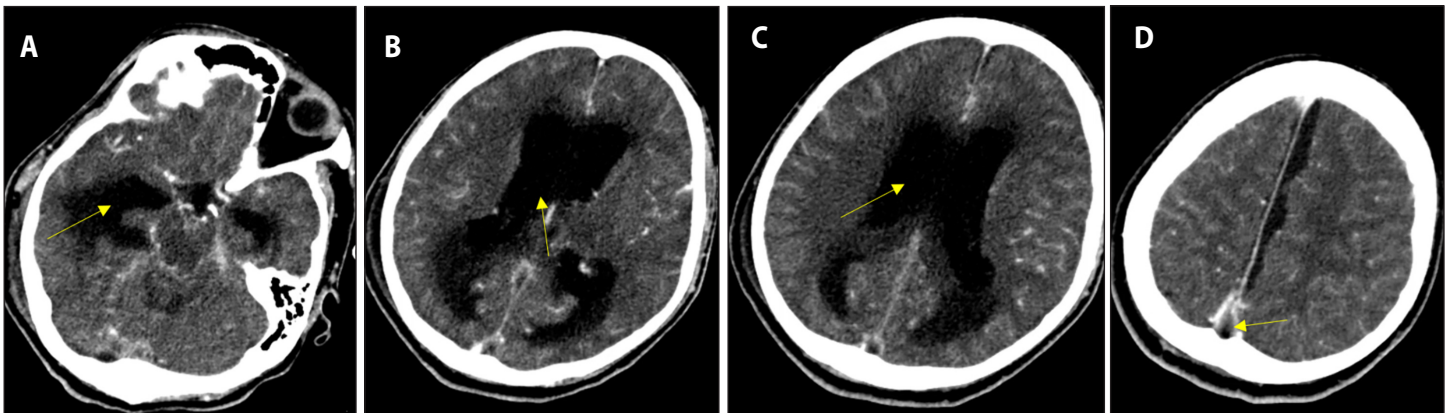
Factors that influence the development of intracranial complications include age (first decade or elderly), immunosuppression, and presence of cholesteatoma.<sup>9</sup> In this case, presence of cholesteatoma due to neglected chronic ear disease and non-recognition of the warning signs of intracranial extension contributed to the vicious cycle of infection.

Lateral sinus thrombophlebitis is caused by spread of infection to the inner wall of the sigmoid sinus resulting in thrombus formation.<sup>10,11</sup> Complete occlusion may occur, and organisms may promote formation of intrasinus abscess with possible distal and proximal extensions. The most common presentation of lateral sinus thrombosis is sustained or spiking fever, associated with otorrhea, postauricular edema and otalgia. However, the triad of fever, headache and focal neurological symptoms were only present in 20% of patients.<sup>9</sup> Sometimes, patients may be asymptomatic and analysis of CSF shows no abnormality.<sup>4,11</sup> Our patient presented with fever, headache, vomiting, altered level of consciousness, abducens nerve palsy, sluggish pupillary light reflex, papilledema, and weak extremities which worsened in the course of the disease. The fixed lateral gaze to the right was due to compression

of the sixth cranial nerve which improved after ventriculostomy.

In retrospect, his frequent visits to the hospital should have raised a high index of suspicion to decipher the “red flags” of intracranial complication. The abducens nerve palsy was caused by changes in intracranial pressure which may result in downward displacement of the brainstem causing stretching of the sixth nerve tethered as it exits the pons and inside Dorello’s canal.<sup>12</sup> This is in contrast to the abducens nerve palsy of Gradenigo syndrome<sup>6,13</sup> which is due to spread of infection to the petrous apex, affecting cranial nerves V and VI in Dorello’s canal associated with facial pain due to involvement of the trigeminal ganglion.<sup>12,14</sup>

To confirm the diagnosis of lateral sigmoid sinus thrombosis, CT scans may demonstrate the “delta sign,” an empty triangle representing a central non-enhancing clot surrounded by enhancing dural sinus wall which was documented in the series of imaging studies of the patient including ventricular dilatation and hydrocephalus. (Figure 5) Magnetic resonance imaging (MRI) may show a thrombus and enhancement in the left lateral sinus.<sup>11</sup> Eradicating the source of infection is the primary priority in the treatment of sinus thrombophlebitis hence, mastoidectomy was done which revealed erosion of the bony sinus plate and perisinus abscess. The patient’s condition deteriorated and



**Figure 5.** Repeat cranial CT scan with contrast (axial view) on second post-op day after mastoidectomy showing marked dilatation of the third and lateral ventricles as a result of compression of the fourth ventricle secondary to swelling of the right cerebellum, diffuse cerebral edema and transependymal seepage (A to C, arrows). The "empty delta sign," a triangle representing a central non-enhancing clot surrounded by enhancing dural sinus wall, is characteristic of a lateral sigmoid sinus thrombosis (D, arrow).

otitic hydrocephalus developed postoperatively the following day.

Otitic hydrocephalus (OH) usually originates from chronic or acute ear infection<sup>11</sup> or mastoiditis<sup>6</sup> occurring in pediatric and adult population. It is characterized by increased intracranial pressure with clear CSF, transient sixth nerve palsy, headache, vomiting, papilledema with no other detectable CNS signs and no actual dilation of ventricles.<sup>11,15</sup> Otitic hydrocephalus is a misnomer according to some because it may occur in the absence of otitis and because patients do not show the ventricular dilatation seen in true hydrocephalus.<sup>11</sup> It is more commonly due to diseases in the right ear as seen in this case, since the right lateral sinus is more commonly continuous with superior longitudinal sinus.<sup>15</sup>

The diagnosis of OH is made by exclusion and a brain abscess should be ruled out by CT scan. Lumbar puncture is considered diagnostic and therapeutic with CSF pressure of as high as 300 mm of water.<sup>15</sup> In this case, brain abscess and cavernous sinus thrombosis were initially considered however, lateral sinus thrombosis which progressed to OH subsequently became apparent.

Otitic hydrocephalus may occur a week,<sup>15</sup> months, or a year after mastoid surgery.<sup>11</sup> The pathophysiology of OH may be secondary to disruption of venous circulation due to changes in CSF pressure directly related to intracranial venous pressure or vasomotor reflex phenomenon that originated in the thrombosed sinus. Viswanatha stated that "otitic hydrocephalus is commonly associated with lateral sinus thrombosis, but not all patients with lateral sinus thrombosis develop otitic hydrocephalus."<sup>11</sup>

Otitic hydrocephalus arising from lateral sigmoid sinus thrombosis (LST) may show dilatation of cerebral ventricles, CSF abnormalities, and neurologic deficits<sup>11,15</sup> which may be fatal and irreversible. In the later stage of the disease, dilatation of the ventricles may develop in contrast to the early stage where it is absent. Intraoperative findings

on mastoidectomy of patients who developed OH, have intact bony plate covering the sigmoid sinus<sup>15</sup> while others show bony erosion of the sinus plate.<sup>11</sup>

Otitic hydrocephalus is a rare complication of otitis media which may occur in 8% of otogenic intracranial complications.<sup>11</sup> Infection of the superior sagittal sinus prevents CSF absorption through the arachnoid villi, resulting in increased intracranial pressure. This was documented by lumbar tap on 2 separate occasions. The patient's CT scan showed marked dilatation of the third and lateral ventricles as a result of compression of the fourth ventricle. Persistent filling defects in the posterior aspect of superior sagittal sinus, right transverse sinus, sigmoid, and jugular vein ascribed to deep venous thrombosis were observed. This led to obstructive hydrocephalus due to disruption of the venous circulation secondary to changes in CSF pressure directly affecting the intracranial venous pressure. This resulted from sudden inadequate venous drainage from the cranial cavity caused by obstruction of the sigmoid sinus, or failure of CSF absorption.<sup>10</sup> Symptoms include vomiting, headache, diplopia, or blurred vision. Increased intracranial pressure with clinical symptoms of papilledema without ventricular dilation or meningitis is enough to make the diagnosis of OH.<sup>11</sup>

The treatment of lateral sinus thrombosis consists of intravenous antibiotics,<sup>16</sup> mastoidectomy, aggressive treatment of the increased intracranial pressure to prevent blindness, repeated lumbar puncture, steroids, shunting procedures,<sup>10</sup> and exposure of the sigmoid sinus and dura mater. Enoxaparin for anticoagulation as empiric treatment for 6 weeks has been reported.<sup>17</sup> However, other studies consider anticoagulants not part of standard care since they increase the risk of venous infarction despite arresting the spread of thrombosis.<sup>11,18</sup> There is little benefit from anticoagulants unless the clots are extensive.<sup>9</sup>

If there is no peri sinus abscess and in the absence of symptoms

of sepsis, coagulation of the sigmoid sinus should not be removed. However, if there is a peri sinus abscess and clinical signs of septicemia, the sinus should be opened, the clot removed, and the internal jugular vein ligated.<sup>6,11</sup> In another approach, aspiration through the sinus wall may be attempted. If there is no blood, the upper and lower parts of the sigmoid sinus are packed tightly before the wall of the sinus is incised. Packs are removed in 4-5 days.<sup>18</sup> Other options include mastoidectomy followed by removal of thrombus via trans mastoid approach and ventriculo-peritoneal (VP) shunting for OH.<sup>4</sup> In this particular case, mastoidectomy and ventricular shunt were done while the sigmoid sinus was not opened, and thrombolytic agents were not utilized. In retrospect, opening the sigmoid sinus may have helped, although this should be done by a skilled and experienced otologist or neurosurgeon, since the thrombus may be dislodged into the circulation and aggravate the patient's precarious condition.

In the absence of a surgical indication such as a cholesteatoma or tumor, treatment for intracranial complications is mainly medical which include Acetazolamide, Mannitol, diuretics, and corticosteroids to decrease intracranial pressure and cerebral edema.<sup>11</sup> If aggressive medical treatment does not relieve the intracranial pressure, lumbar drainage of CSF can be performed by placement of lumbar drain.<sup>11</sup> If prolonged drainage is required, a shunt may be placed, however, it has to be emphasized that resolution of intracranial pressure may take weeks to months.<sup>10</sup> Repeated drainage of CSF may lead to full recovery.<sup>11</sup> Regarding prognosis of OH, most cases resolved spontaneously<sup>15</sup> and patients usually recover after antibiotic therapy with or without mastoidectomy and ventriculostomy.<sup>2,3,4,9,11</sup> Three cases of otitic hydrocephalus were reported in which two patients had CSF otorrhoea temporarily relieved by repeated epidural catheterization which later required a VP shunt. Another patient had 5 lumbar punctures with withdrawal of 5-10 ml of CSF per session, as therapeutic measure to lower CSF pressure. The patient was discharged 5 days after last LP with improvement of visual acuity and papilloedema.<sup>11,15</sup> Good outcomes may be expected when OH is treated in the early stage. However, in this particular case, the patient's ventriculostomy and CSF drainage did not relieve the pressure. This may be due to severe infection, presence of a thrombus and advanced stage of the disease.

When dealing with chronic otitis media, early diagnosis and surgical intervention are important. Appropriate diagnosis and treatment planning are necessary in order to avoid progression of complications both intracranial and extracranial. A multidisciplinary approach including neurosurgery, neurology, and microbiology disciplines is required.<sup>17,19</sup>

Finally, OH due to LST is a serious complication seldom encountered nowadays. Increased intracranial pressure may be appreciated in the

early stage and may worsen towards ventricular dilatation later. The clinical manifestations may be transient but may become irreversible if the root cause is not addressed promptly and properly. This case report underscores the importance of early recognition of warning signs of intracranial complications to institute prompt management. Otolaryngologists should be vigilant and exercise close monitoring and consistent follow up since OH may develop even a year after ear surgery. In this case, OH developed and progressed after mastoidectomy and CSF drainage did not provide relief, which eventually led to the patient's demise.

REFERENCES

1. Ayson P, Lopez JE, Llanes EG. Chronic Suppurative Otitis Media: Bacteriology and Drug Sensitivity Patterns at the Quirino Memorial Medical Center (2004-2005): A Preliminary Study. *Philipp J Otolaryngol Head Neck Surg.* 2006 Dec; 21(1-2): 20-23. DOI: <https://doi.org/10.32412/pjohns.v21i1-2.823>.
2. Gower D, McGuirt WF. Intracranial complications of acute and chronic infectious ear disease: a problem still with us. *Laryngoscope.* 1983 Aug;93(8):1028-33. DOI: 10.1288/00005537-198308000-00010; PubMed PMID: 6877010.
3. Kangsanarak J, Navacharoen N, Foonant S, Ruckphaopunt K. Intracranial complications of suppurative otitis media: 13 years' experience. *Am J Otol.* 1995 Jan;16(1):104-9. PubMed PMID: 8579165.
4. Modak VB, Chavan VR, Borade VR, Kotnis DP, Jaiswal SJ. Intracranial complications of otitis media: in retrospect. *Indian J Otolaryngol Head Neck Surg.* 2005 Apr;57(2):130-5. DOI: 10.1007/BF02907667; PubMed PMID: 23120149; PubMed Central PMCID: PMC3450981.
5. Penido NDO, Borin A, Iha LCN, Suguri VM, Onishi E, Fukuda Y, et al. Intracranial complications of otitis media: 15 years of experience in 33 patients. *Otolaryngol Head Neck Surg.* 2005 Jan;132(1):37-42. DOI: 10.1016/j.otohns.2004.08.007; PubMed PMID: 15632907.
6. Govea-Camacho LH, Pérez-Ramírez R, Cornejo-Suárez A, Fierro-Rizo R, Jiménez-Sala CJ, Rosales-Orozco CS. Diagnosis and treatment of the complications of otitis media in adults. Case series and literature review. *Cir Cir.* Sep-Oct 2016;84(5):398-404. DOI: 10.1016/j.circir.2015.05.052; PubMed PMID: 26738650.
7. Bartell SM, Kim HN, Ambrogini E, Han L, Iyer S, Ucer SS, et al. FoxO proteins restrain osteoclastogenesis and bone resorption by attenuating H2O2 accumulation. *Nat Commun.* 2014 Apr 30;5:3773. DOI: 10.1038/ncomms4773; PubMed PMID: 24781012; PubMed Central PMCID: PMC4015330.
8. Hamed MA, Nakata S, Sayed RH, Ueda H, Badawy BS, Nishimura Y, et al. Pathogenesis and Bone Resorption in Acquired Cholesteatoma: Current Knowledge and Future Prospectives. *Clin Exp Otorhinolaryngol.* 2016 Dec;9(4):298-308. DOI: 10.21053/ceo.2015.01662; PubMed PMID: 27440129; PubMed Central PMCID: PMC5115149.
9. Gendeh HS, Abdullah AB, Goh BS, Hashim ND. Intracranial complications of chronic otitis media: why does it still occur?. *Ear, Nose Throat J.* 2019 Aug; 98(7): 416-419. DOI: 10.1177/0145561319840166; PubMed PMID: 31018687.
10. Nissen AJ, Bui H. Complications of chronic otitis media. *Ear Nose Throat J.* 1996 May 1; 75(5):284-292. DOI: <https://doi.org/10.1177/014556139607500507>.
11. Viswanatha B. Otitic hydrocephalus: a report of 2 cases. *Ear Nose Throat J.* 2010 Jul; 89(7): E34-37. DOI: 10.1177/014556131008900708; PubMed PMID: 20628978.
12. Azarmina M, Azarmina H. The six syndromes of the sixth cranial nerve. *J Ophthalmic Vis Res.* 2013 Apr;8(2):160-71. PubMed PMID: 23943691; PubMed Central PMCID: PMC3740468.
13. Gore MR. Gradenigo's Syndrome: A Review. *Ann Med Health Sci Res.* 2018;8:220-224. Available from: <https://www.amhsr.org/articles/gradenigos-syndrome-a-review-4675.html>.
14. Milanes-Rodríguez G, Ibañez-Valdés L, Foyaca-Sibat H, Perez-Fernandez M. The Abducens Nerve in Neurology. *Int J Neuro.* 2008; 10(2).
15. Lee GT. Otitic hydrocephalus. *Singapore Med J.* 1986 Feb; 27(1):77-79. PubMed PMID: 3715496.
16. Yeoh XY, Lim PS, Pua KC. Case of chronic otitis media with intracranial complication and contralateral extracranial presentation. *Case Rep Otolaryngol.* 2016;2016:7810857. DOI: 10.1155/2016/7810857; PubMed PMID: 27668115; PubMed Central PMCID: PMC5030454.
17. Macin S, Inkaya AC, Dogan O, Bozkurt G, Gocmen R, Sardan YC, et al. Mastoiditis, brain abscess and sinus thrombosis as complications of chronic otitis media: A case report. *Jundishapur J Microbiol.* 2017; 10(2):1-4. DOI: 10.5812/jjm.41352.
18. Sharma N, Jaiswal AA, Banerjee PK, Garg AK. Complications of chronic suppurative otitis media and their management: a single institution 12 years experience. *Indian J Otolaryngol Head Neck Surg.* 2015 Dec;67(4):353-60. DOI: 10.1007/s12070-015-0836-5; PubMed PMID: 26693451; PubMed Central PMCID: PMC4678280.
19. Penido NO, Chandrasekhar SS, Borin A, Maranhão ASA, Testa JRG. Complications of otitis media --- a potentially lethal problem still present. *Braz J Otorhinolaryngol.* May-Jun 2016;82(3):253-62. DOI: 10.1016/j.bjorl.2015.04.007 PubMed PMID: 26420564.