

Double Whammy: A Case Report of a 71-Year-Old Filipino Female Leprosy Patient Diagnosed With Crusted Scabies



John Benjamin B. Gochoco, MD

ABSTRACT

This is the case of a 71-year-old Filipino female from Caloocan with a history of Hansen's disease, treated (1980) who presented with generalized crusted plaques. Clinical and histopathological examination revealed crusted (Norwegian) scabies. Crusted scabies is a rare condition and diagnosis is often delayed; this condition is treated with systemic broad spectrum antiparasitic agents. Despite the common prevalence of scabies, its atypical forms are often overlooked and neglected which oftentimes does affect the patients' well-being.

Keywords: infection; skin diseases; leprosy; parasitic; crusted scabies; case report

INTRODUCTION

Scabies is a common parasitic infection and easily diagnosed and treated, but little knowledge in its atypical forms is known. Crusted (Norwegian) scabies is a rare form of the disease that was first reported in Norway by Danielsen and Boeck in 1848 as a kind of scabies infection caused by

millions of mites in a patient affected with leprosy. More than 200 years later we come full circle to the same circumstances. This report aims to present a rare case of crusted scabies with the hope that infectious and parasitic infections would not be overlooked.

Patient Information

A Filipino female from Caloocan City with a history of Hansen's disease, treated (1980) with grade 2 disabilities presented with a one-year history of multiple erythematous pruritic plaques on the arms and legs. The patient was being managed by another physician and treated as a case of xerotic eczema with topical corticosteroids and oral antihistamines which only afforded temporary relief. The lesions, later on evolved into multiple ill-defined skin-colored plaques on the face, extremities, and trunk, topped with yellowish crusts and fissures but the patient did not seek any treatment at that time.

Clinical Finding

On cutaneous examination, the patient presents with multiple ill-defined skin colored plaques topped with yellowish crusts and fissures noted as well as digital deformities and protruding osseous structures of the 1st to 3rd digits of the left hand and (Figure 1) multiple ill-defined skin colored plaques topped with hyperpigmented crusts and fissures with resorption of the toes (Figure 2).

✉ John Benjamin B. Gochoco, MD
benjo_g12@yahoo.com

Department of Dermatology, Dr. Jose N. Rodriguez Memorial Hospital and Sanitarium, St. Joseph Avenue, Tala, Caloocan City 1427

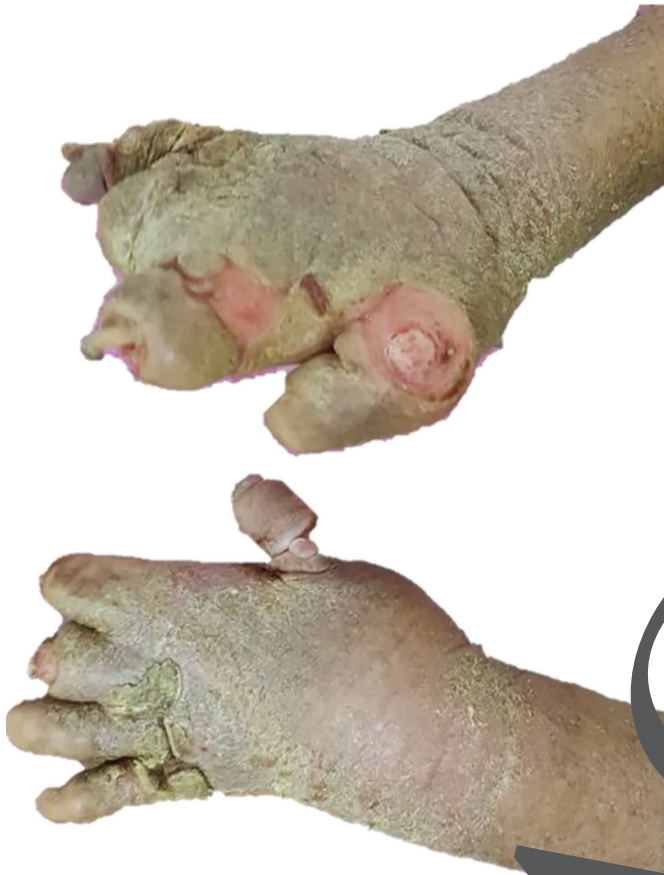

Figure 1: Patient's hands and arms presenting with multiple ill-defined skin-colored plaques topped with yellowish crusts and fissures noted as well as the digital deformities and protruding osseous structures.

Timeline

The patient's timeline prior to admission can be seen in Table 1.

Diagnostic Assessment

The author did a 4 mm skin punch biopsy on the lesion on the right dorsal aspect of the hand. On scanner view, we can appreciate parakeratosis and orthokeratosis of the epidermis with multiple burrows (Figure 3). It was also noted is the psoriasiform hyperplasia of the epidermis (Figure 4). On closer magnification, we can see in the stratum corneum that there are multiple burrows containing abundant mitotic "pig tail" structures which are the remnants of empty eggs and fecal pellets (scybala) (Figure 5). In the dermis, there are plenty of eosinophils that are indicative of a parasitic infection. The histopathological diagnosis was signed out as scabies

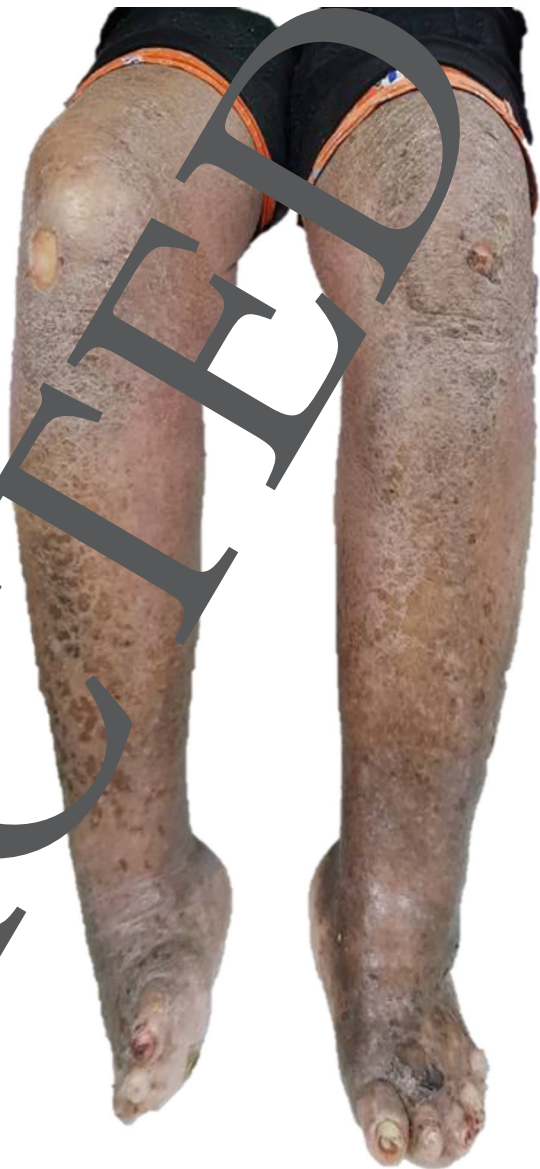

Figure 2: The patient's legs with multiple ill-defined skin colored plaques topped with hyperpigmented crusts and fissures. Noted as well are the digital resorption of the toes.

infection. Unfortunately, the patient expired due to acute respiratory failure type 1 secondary to high risk community-acquired pneumonia, pleural effusion, secondary anemia without being started on treatment for crusted scabies.

Therapeutic Intervention

The patient expired due to another medical complication prior to initiation of therapy.

Follow-up and Outcomes

Not applicable

Table 1: Timeline of Patient Prior to Admission.

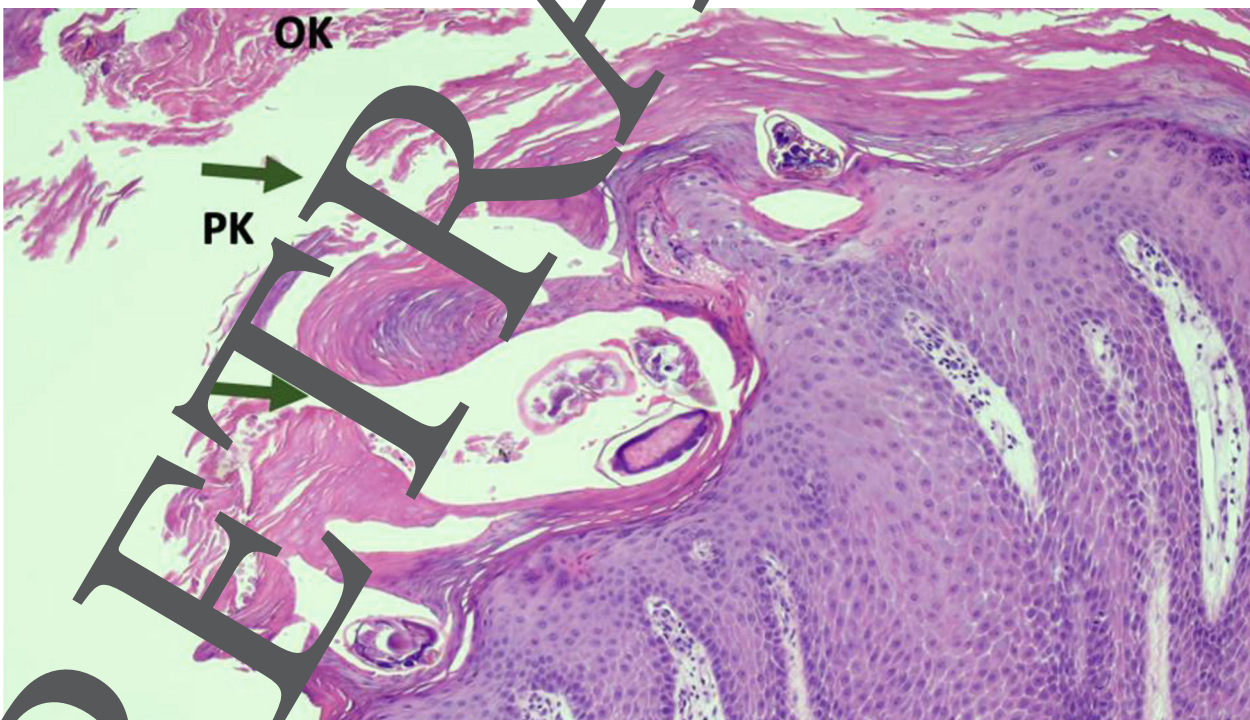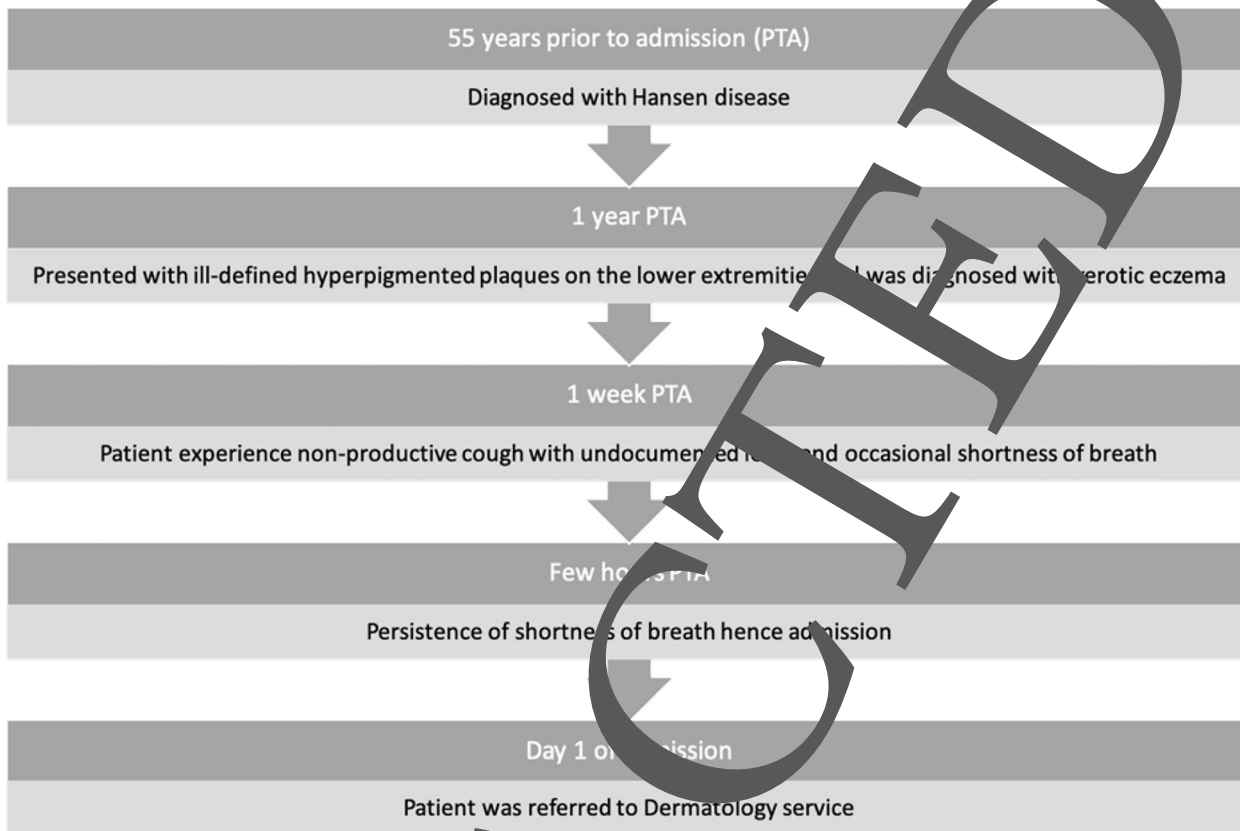


Figure 3: Skin biopsy stained with H&E under scanning view (4x) shows orthokeratosis (OK) and parakeratosis (PK) with mite burrow (green arrows)

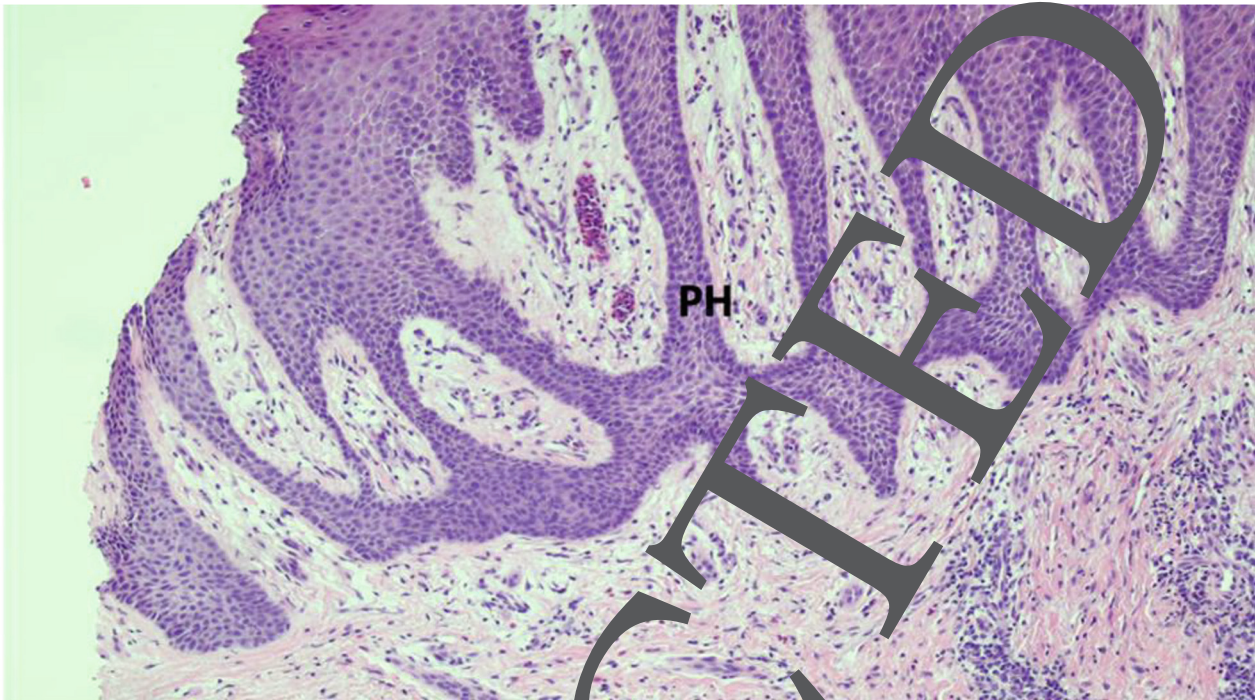


Figure 4: Skin biopsy stained with H&E under scanning view (4x). The epidermis shows psoriasiform hyperplasia (PH).

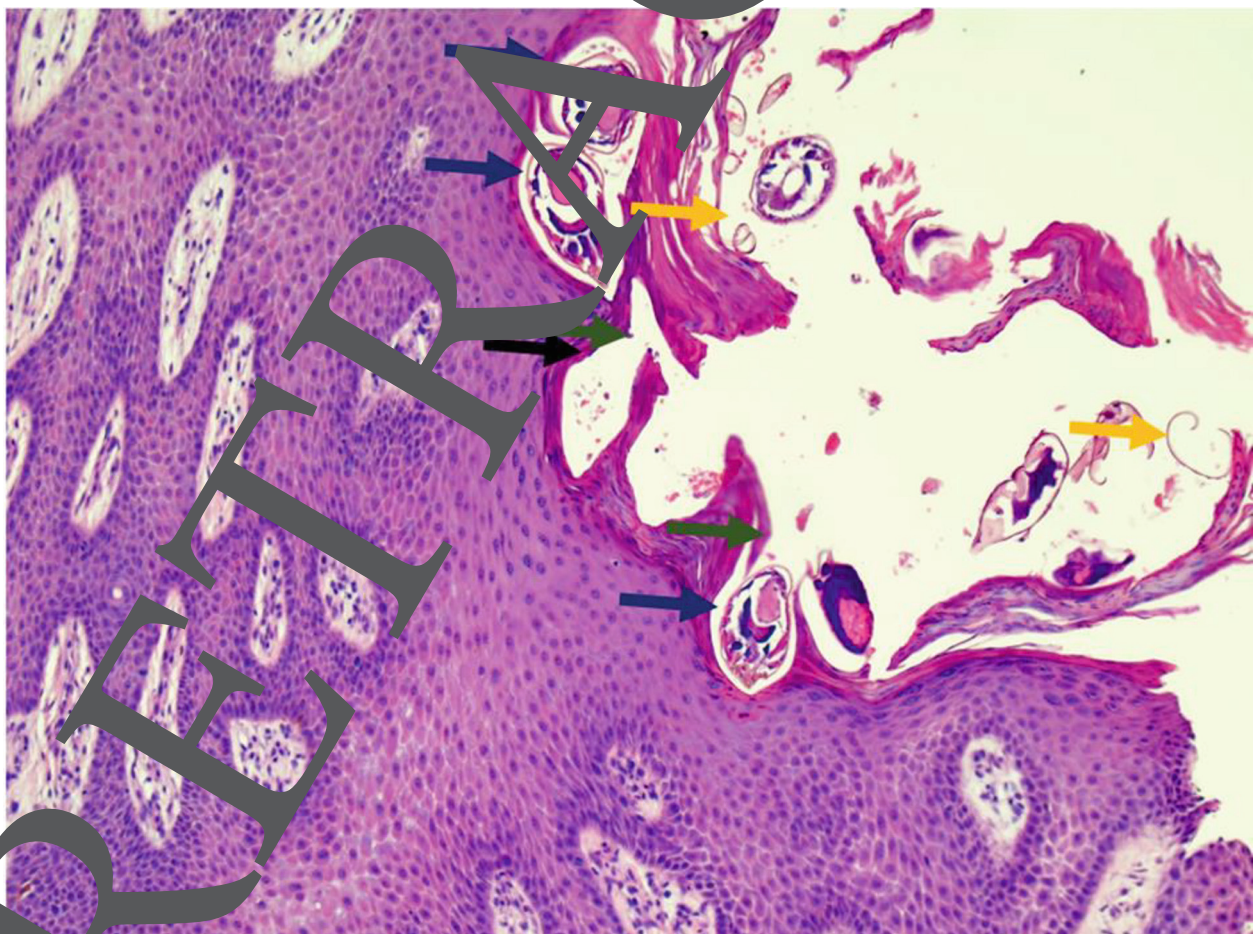


Figure 5: Skin biopsy stained with H&E under low power magnification (10x). The figure shows intact mites (blue arrows), "pig-tail" structures (yellow arrows), and scybala (black arrow) located in multiple burrows (green arrows)

DISCUSSION

Scabies is a global problem that affects people of various ages, colors and socioeconomic backgrounds. The incidence varies greatly, with some developing nations having a greater rate than industrialized countries. Worldwide, scabies affects 200 to 300 million individuals annually[1], with no local data due to unreported cases. The prevalence rate of atypical scabies presentation, like crusted scabies, is unknown[2]. There are only a few reported cases showing the association between crusted scabies and leprosy in non-HIV infected individuals[3].

Patients have typical findings of excoriations and eczematous dermatitis on the interdigital webs, sides of fingers, volar aspects of the wrists, and lateral palms, elbows, axillae, scrotum, penis, labia and areolae in women. Crusted scabies in contrast to typical scabies presents with numerous thick crusts and contains large numbers of the scabies mite (*Sarcoptes scabiei* var. *hominis*) commonly harboring anywhere up to 50 oviparous female mites making this disease highly contagious. In a defective immunologic or sensory response such as leprosy[4], patients allow the mite to spread and sometimes the host could harbor millions of mites on their skin surface, with very minimal pruritus.[5]

Close personal contact is a prime route of transmission, occasionally through sexual contact and fomites. Scabies is suspected when nocturnal pruritus is present, along with a specific pattern of lesions and known epidemiologic background; however, as mentioned in crusted scabies, this may not be as evident. Onset is typically insidious, with the patient complaining of pruritus. A definitive diagnosis is made by microscopic identification of the scabies mite, eggs, or fecal pellets (scybala) by skin scraping or demonstration in skin biopsy, even though the fact that numerous techniques of testing may be used to establish the presence of mites, the diagnosis is usually based on clinical impression, and solidified by the response to treatment.

Although the histologic characteristics of scabies are similar to that of arthropod bite reactions, they are unique enough to establish the diagnosis. If a burrow is biopsied, there could be mites, larvae, ova and feces identified within the stratum corneum. Psoriasiform hyperplasia in the epidermis is seen as well[6]. Burrows are surrounded by inflammatory

cell infiltrates comprising mainly lymphocytes and histiocytes[7] and pigtail-like structures which are egg fragments/shells/casings that appear to be firmly attached to the stratum corneum and are left behind after the mite hatches[8]. Emerging diagnostics include multiphoton microscopy (MPM), a type of laser scanning microscopy that uses label-free contrast based on optical signals generated through nonlinear light-matter interaction; reflectance confocal microscopy and optical coherence tomography in vivo imaging of scabies mites and their eggs in human skin has shown to be successful.[9]

Treatment of crusted scabies is by multiple cycles of topical and/or oral scabicide. The only topical medications approved for the treatment of crusted scabies is permethrin 5% for 8 hours, and then repeated after 7 days. In systemic treatment, only ivermectin 20 µg/kg on days 1 and 8 was found to be substantially efficacious.[10] In the study of Dressler et al., it was found that permethrin was not more effective or more effective than crotamiton 10% for 8 hours on days 1, 2, 3 and 8 or benzyl benzoate 10% for 24 hours and in a comparison of topical versus systemic treatment. For patients who are unsuccessfully treated with permethrin, therapy with acitretin (30 mg/day) for 2 weeks has yielded positive results in one case.[11] The treatment of all close contacts with environmental decontamination should be integrated with individual medication. Management of crusted scabies includes environmental modification as well. In patients with limited access to electricity, hot water and household appliances, isolating scabies-contaminated fomites in tightly sealed plastic bags for up to 8 days, until all parasites are dead is a valid and prolonged option.[12] The majority of people who are treated for scabies get relief from their symptoms within three days, although patients who first presented with pruritus may endure chronic pruritus even after therapy. Treatment failures can be due to a variety of reasons and must be managed properly.[13]

CONCLUSION

Scabies has been present in our population for hundreds of years. Treatment has not changed for some time with only a few new drugs being tested and developed for the disease, such as acitretin. [11] Diagnosis has been mainly clinical but in the

atypical forms, different modalities could be utilized for accurate diagnosis. There are new modalities that could pave a new way of diagnosing patients with scabies that would spare patients with invasive procedures. A high index of clinical suspicion, especially in a patient with impaired immunity and sensory perception would lead to the proper

diagnosis and management in patients with crusted scabies.

Declaration of Competing Interests

The author declares that there are no conflicts of interest and no source of funding for this case report.

RETRACTED

REFERENCES

1. Leung A, Lam J, Leong K. Scabies: A Neglected Global Disease. *Current Pediatric Reviews*. 2020;16(1):33–42.
2. Guldbakke KK, Khachemoune A. Crusted scabies: a clinical review. *J Drugs Dermatol*. 2006;5(3):221–7.
3. Pedra E Cal APP, Ferreira CP, da Costa Nery JA. Crusted scabies in a patient with lepromatous leprosy. *Braz J Infect Dis*. 2016;20(4):399–400. Available from: <http://dx.doi.org/10.1016/j.bjid.2016.04.001>
4. Kutlu NS, Turan E, Erdemir A, Gürel MS, Bozkurt E. Eleven years of itching: a case report of crusted scabies. *Cutis*. 2014;94(2):86–8, 95.
5. Kang S, Kang S. *Fitzpatrick's Dermatology*. New York: McGraw-Hill Education; 2019.
6. Ebrahim KC, Alves JB, Tomé L de A, Moraes CF de, Gaspar AD, Franck KF, et al. Norwegian scabies - rare case of atypical manifestation. *An Bras Dermatol*. 2016;91(6):826–8. Available from: <http://dx.doi.org/10.1590/abd1806-4841.20164811>
7. Walton SF, Currie BJ. Problems in diagnosing scabies, a global disease in human and animal populations. *Clin Microbiol Rev*. 2007;20(2):268–79. Available from: <http://dx.doi.org/10.1128/CMR.00042-06>
8. Kristjansson AK, Smith MK, Gould JW, Gilliam AC. Pigtail pigtailed are a clue for the diagnosis of scabies. *J Am Acad Dermatol*. 2007;57(1):174–5. Available from: <http://dx.doi.org/10.1016/j.jaad.2007.03.018>
9. Lentsch G, Balu M, Koenig K, Tromberg BJ, Zachary CB, Smith J. In vivo multiphoton microscopy of scabies. *JAAD Case Rep*. 2018;4(10):985–7. Available from: dx.doi.org/10.1016/j.jidcr.2018.07.017
10. Dressler C, Rosumeck S, Sunderkötter C, Werner K, Noh A. The Treatment of Scabies. *Deutsches Ärzteblatt international*. 2016.
11. Veraldi S, Nazzaro G, Serbelloni L. Treatment of crusted scabies with acitretin. *Br J Dermatol*. 2007;157(3):862–3. Available from: <http://dx.doi.org/10.1111/bjd.13780>
12. Bernigaud C, Fernandez DD, Lu H, Taylor S, Martel G, Chosidow O, et al. How to eliminate scabies parasites from fomites: A high-throughput in vivo experimental study. *J Am Acad Dermatol*. 2020;83(1):241–5. Available from: <http://dx.doi.org/10.1016/j.jaad.2019.11.069>
13. Karthikeyan K. Treatment of scabies: newer perspectives. *Postgrad Med J*. 2007;81(951):7–11. Available from: <http://dx.doi.org/10.1136/pgmj.2003.018390>



Open Access This article is licensed under a Creative Commons Attribution-NonCommercial-ShareAlike 4.0 International License, which permits use, share — copy and redistribute the material in any medium or format, adapt — remix, transform, and build upon the material, as long as you give appropriate credit, provide a link to the license, and indicate if changes were made. You may do so in any reasonable manner, but not in any way that suggests the licensor endorses you or your use. You may not use the material for commercial purposes. If you remix, transform, or build upon the material, you must distribute your contributions under the same license as the original. You may not apply legal terms or technological measures that legally restrict others from doing anything the license permits. The images or other third party material in this article are included in the article's Creative Commons license, unless indicated otherwise in a credit line to the material. If material is not included in the article's Creative Commons license and your intended use is not permitted by statutory regulation or exceeds the permitted use, you will need to obtain permission directly from the copyright holder. To view a copy of this license, visit <https://creativecommons.org/licenses/by-nc-sa/4.0/>.

RETRACTED