

CASE REPORT

A Young Patient with Metastatic Prostate Adenocarcinoma: A Case Report and Review of Literature

Raphael Benjamin B. Arada, MD

Division of Urology, Department of Surgery, Philippine General Hospital, University of the Philippines Manila

Prostate cancer is extremely rare in men under 40 years old, and current guidelines recommend against screening in this patient population. However, recent data show poorer prognosis in younger men with prostate cancer, especially in those with advanced stage disease. Presented and discussed is the case of a 38-year-old Filipino male diagnosed with prostate adenocarcinoma Gleason 9 (4+5) with bone metastasis presenting with urinary retention, suspicious rectal exam findings, and a markedly elevated PSA. The patient underwent transurethral resection of the prostate and concurrent bilateral orchiectomy. With reports of cases such as this one, biopsy might still be indicated to confirm or rule out cancer in a younger patient with a very high suspicion of prostate cancer based on clinical and laboratory findings. Further studies are needed to identify risk factors for development of prostate cancer in this population to achieve early diagnosis and treatment.

Keywords: prostate, prostate cancer, early detection

Introduction

Prostate cancer is the most common non-cutaneous malignancy in men and is the second leading cause of cancer death worldwide.¹ It is, however, considered a disease of elderly men and is very rarely diagnosed in those less than 40 years of age.² Moreover, since men under the age of 40 are considered not at risk for the disease, current clinical practice guidelines do not recommend screening for prostate cancer in this population.^{3,4} Presented here is the case of a 38-year-old male diagnosed with advanced prostate adenocarcinoma presenting with bone metastasis.

The Case

A 38-year-old Filipino male presented with a 4-month history of progressive lower urinary

tract symptoms and eventual acute urinary retention. The patient has good functional status with no comorbid conditions or previous surgeries. He has no known family history of cancer. A transrectal ultrasound (TRUS)-guided prostate biopsy was performed for a hard, enlarged prostate on rectal exam, measuring 67cc by TRUS volume measurement (Figure 1), and an elevated PSA of >100 ng/dL, revealing prostate adenocarcinoma Gleason 9 (4+5) on all cores (Figure 2). Skeletal scintigraphy showed widespread bone metastasis. The patient underwent a transurethral resection of the prostate to relieve his urinary retention, and after considering the options and costs for androgen-deprivation therapy, the patient consented to undergo concurrent bilateral orchiectomy. He was then discharged voiding freely without difficulty or incontinence. PSA is being monitored on follow-up and he is

maintained on monthly injections of Zoledronic acid.

Discussion

Prostate cancer is generally regarded as a disease of the older population, with a median age of diagnosis at 68 years.¹ A recent population-based study of men up to age 74 diagnosed with prostate cancer showed that only 0.5 percent were less than 45 years old, and of these, only a tenth had stage 4 disease.⁵ To the author's knowledge,

less than 20 individual cases of metastatic prostate cancer have been reported in literature in men less than 40 years old.^{6,7,8,9,10,11,12} Histopathological findings reported were either adenocarcinoma or undifferentiated cancer, and the most common sites of metastasis were the bones and lymph nodes, as shown in Table 1.

Recent data suggest that early-onset prostate cancer biologically differs from late-onset disease, and a genetic component is strongly associated with the former.¹³ A replication-based association study for single nucleotide polymorphisms associated with prostate cancer showed that

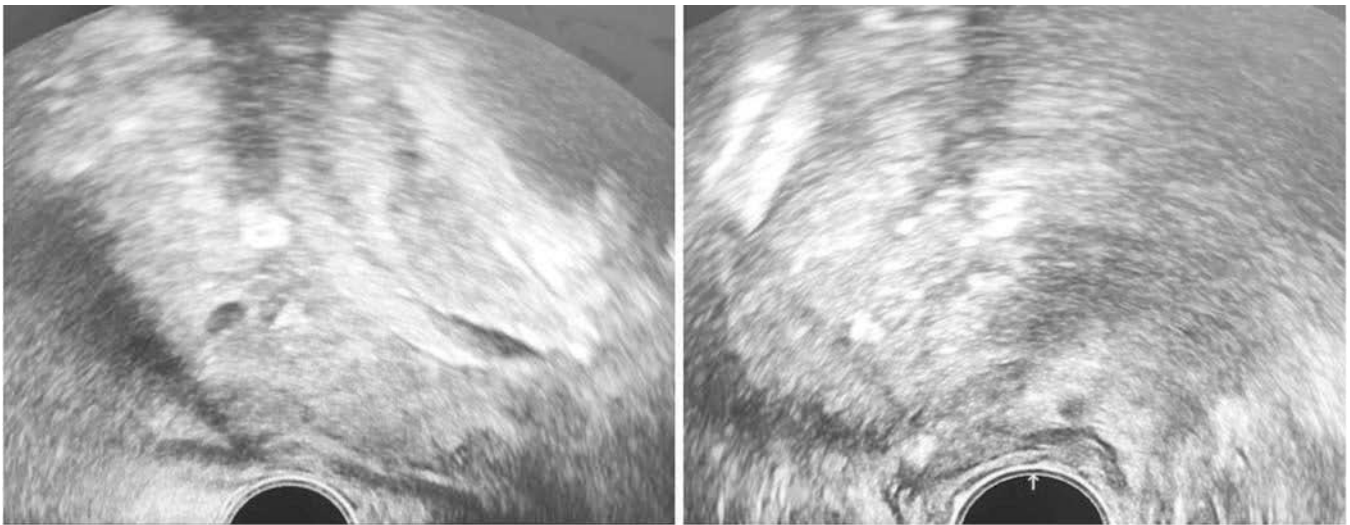


Figure 1. Transrectal ultrasound images of the prostate.

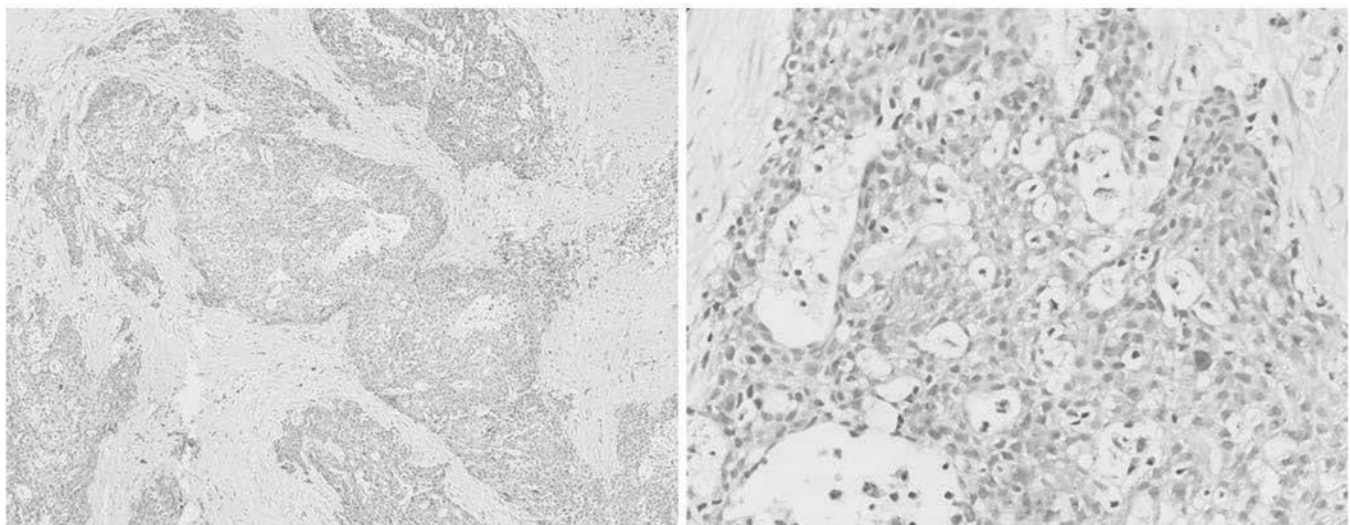


Figure 2. Histopathological images (10x, 40x) showing prostate adenocarcinoma Gleason 9 (4+5)

Table 1. Reported cases of metastatic prostate cancer in the young (<40 years of age).

Case	Age	Histopathology	Site of Metastasis	Treatment
Shimada, et al. 1980 ⁶	11	Undifferentiated	Bone, liver, lungs, lymph nodes	None
Weitzner, et al. 1980 ⁷	27	Adenocarcinoma	Bone	Radiation therapy
Madan, et al. 2015 ⁸	28	Adenocarcinoma	Bone	Bilateral orchiectomy, anti-androgen therapy, palliative radiation
Gupta S, et al. 2017 ⁹	28	Adenocarcinoma	Lymph nodes	Bilateral orchiectomy and adjuvant anti-androgen therapy
Yamamoto, et al. 1990 ¹⁰	30	Undifferentiated	Lymph nodes	Surgery (cystoprostatectomy) with adjuvant chemotherapy
D'Aprile, et al. 2000 ¹¹	36	Undifferentiated	Bone, lymph nodes	Chemotherapy and hormone therapy
Sasaki, et al., 2004 ¹²	37	Adenocarcinoma	Bladder wall	Hormone and radiation therapy

common genetic variants play an increased role in early-onset prostate cancer, relative to that with a late onset.¹⁴

Prostate cancer presenting in a younger population has a poor prognosis. For individuals diagnosed with metastatic prostate cancer, younger age is an independent prognostic factor in patients treated with primary androgen deprivation therapy.¹⁵ Younger men with prostate cancer are also more likely to die of their disease compared to older men with similar clinical features.¹⁶ This is true especially for those diagnosed with higher grade or locally advanced disease.

A population-based study showed that the relationship between young age at diagnosis and survival is significantly influenced by stage and histological grade.¹⁷ Even if relative survival is constant with patient age, the absolute impact of prostate cancer at different ages varied substantially as indicated by loss of life expectancy.¹⁸ These findings might indicate that younger prostate cancer patients should be given more aggressive treatment than older patients.

Current guidelines recommend against screening for prostate cancer in men less than 40 years of age. However, with reports of cases such as this one, a needle biopsy might still be indicated

to confirm or rule out cancer in a younger patient with a very high suspicion of prostate cancer based on clinical and laboratory findings. Detection of the disease is important in this select group of patients considering the poorer prognosis of advanced prostate cancer in younger men. In addition, further studies are needed to identify risk factors for the development of prostate cancer in the young to achieve early diagnosis and necessary treatment.

References

1. Ferlay J, Shin H, Bray F, Forman D, Mathers C, Parkin D. GLOBOCAN 2008: Cancer Incidence and Mortality Worldwide: IARC CancerBase No 10. International Agency for Research on Cancer. 2010.
2. Jani AB, Johnstone PA, Liauw SL, Master VA, Brawley OW. Age and grade trends in prostate cancer (1974-2003): A surveillance, epidemiology, and end results registry analysis. *Am J Clin Oncol* 2008; 31(4): 375-8.
3. Carter HB, et al. Early detection of prostate cancer: American Urological Association (AUA) guidelines. 2013
4. Mottet N, et al. European Association of Urology (EAU) Guidelines on Prostate Cancer. 2015

5. Lin DW, Porter M, Montgomery B. Treatment and survival outcomes in young men diagnosed with prostate cancer: a population-based cohort study. *Cancer* 2009; 115: 2863.
6. Shimada H, Misugi K, Sasaki Y, Iizuka A, Nishihira H. Carcinoma of the prostate in childhood and adolescence: report of a case and review of the literature. *Cancer* 1980; 46(11): 2534-42.
7. Weitzner S, Sarikaya H, Furness TD. Adenocarcinoma of prostate in a twenty-seven-year-old man. *Urology* 1980; 16(3): 286-8.
8. Madan R, Singh L, Haresh KP, Rath GK. Metastatic adenocarcinoma of prostate in a 28-year-old male: The outcome is poor in young patients? *Indian J Palliat Care* 2015; 21(2): 242-4.
9. Gupta S, Gupta A, Saini AK, Majumder K, Sinha K, Chahal A. Prostate cancer: How young is too young? *Curr Urol* 2017; 9(4): 212-5.
10. Yamamoto S, Senzaki A, Yamagiwa K, Tanaka T, Oda T. Prostatic carcinoma in a young adult: a case report. *Hinyokika Kyo* 1990; 36: 617-22.
11. D'Aprile M, Santini D, Di Cosimo S, Gravante G, Vincenzi B, Spoto S, Costantino S, Rabitti C, Tonini G. Atypical case of metastatic undifferentiated prostate carcinoma in a 36 year old man: clinical report and literature review. *Clin Ter* 2000; 151: 371-4.
12. Sasaki H, Miki J, Hasegawa T, Hasegawa N, Ikemoto I, Ohishi Y. Prostatic cancer in a young adult: a report of 2 cases. *Hinyokika Kyo* 2004; 50(1): 57-9.
13. Salinas CA, Tsodikov A, Ishak-Howard M, Kathleen A. Prostate cancer in young men: an important clinical entity. *Nature Rev Urol* 2014; 11 (6): 317.
14. Lange EM, Salinas CA, Zuhlke KA, et al. Early onset prostate cancer has a significant genetic component. *Prostate* 2012; 72: 147-56.
15. Kimura T1, Onozawa M, Miyazaki J, et al. Prognostic impact of young age on stage IV prostate cancer treated with primary androgen deprivation therapy. *Int J Urol* 2014 ;21(6): 578-83.
16. Bratt O. Hereditary prostate cancer: clinical aspects. *J Urol* 2002; 168(3): 906-13.
17. Merrill RM, Bird JS. Effect of young age on prostate cancer survival: a population based assessment (United States). *Cancer Causes Control* 2002; 13: 435-43.
18. Gronberg H, Damber JE, Jonsson H, Lenner P. Patient age as a prognostic factor in prostate cancer. *J Urol* 1994; 152: 892-95.