

CASE REPORT

A Rare Case of Mucinous Adenocarcinoma of the Bladder: A Case Report

Ryan Josef Tuazon, MD; Romeo Lloyd T. Romero, MD, FPUA and Meliton Alpas, MD, FPUA

Section of Urology, Department of Surgery, Veterans Memorial Medical Center

Adenocarcinoma represents 0.5 to 2% of all malignant tumors of the bladder, and the mucinous subtype is extremely rare as a primary vesical lesion. This is the case of a 50-year-old male who presented with dysuria with occasional hematuria, underwent cystoscopy, transurethral resection of the bladder tumor, with the subsequent diagnosis of Mucinous adenocarcinoma of the bladder. He then completed neoadjuvant chemotherapy but eventually underwent cystoprostatectomy, urethrotomy with extended bilateral pelvic lymph node dissection due to tumor progression.

Key words: Mucinous adenocarcinoma, dysuria, hematuria, transurethral resection

Introduction

Bladder cancer is a global disease, with 540,000 incident cases and 188,000 deaths in 2015 worldwide. Among cancers affecting both sexes, bladder cancer ranks as the fourth most prevalent cancer globally.¹ Although incidence rates are highest in Europe and North America, more than 60% of all bladder cancer incidence, and nearly half of bladder cancer deaths occur in the developing world. The histological and pathological type of bladder cancer is mainly urothelial carcinoma, also called transitional cell carcinoma, accounting for approximately 90%. Other types including squamous cell carcinoma and adenocarcinoma, account for 3 respectively.² Adenocarcinoma represents 0.5 to 2% of all malignant tumors of the bladder, and the mucinous subtype is extremely rare as a primary vesical lesion.³ It is more common in patients over 50 years old. It is believed that there is a progression pattern from mucinous metaplasia to mucinous adenoma and then mucinous adenocarcinoma; however, no study has confirmed this hypothesis. Adult vesical exstrophy and

persistent urachal remnants also figure among the risk factors associated with vesical adenocarcinoma. As for clinical presentation, the most common symptoms are hematuria, suprapubic pain, and voiding difficulties, similar to other bladder tumors. Primary mucinous adenocarcinoma of the bladder is classified to have an aggressive behavior, poorly responsive to radiation or chemotherapy, as first-line treatment.⁴ Bladder adenocarcinoma, with or without mucinous differentiation, most often arises at the base or dome, eventually with urachal remnants. The classification itself, between primary vesical and urachal, is debated.

The Case

The patient is a case of a 50-year-old male who initially presented with dysuria with occasional hematuria. A CT scan was done and showed bladder new growth. Cystoscopy, transurethral resection of the bladder tumor with findings of bladder mass occupying the right bladder neck encroaching the right prostate lobe 6cm in widest diameter with the

subsequent diagnosis of Mucinous adenocarcinoma of the bladder. (Figures 1 - 5) He then completed neoadjuvant chemotherapy with Pacitaxel 175mg/m² and Cisplatin 100mg/m² for every 21 days for four cycles, however upon repeat CT with contrast post chemotherapy showed progression of the Adenocarcinoma. Due to the possibility of a primary lesion in the gastrointestinal tract, a colonoscopy was performed revealing sessile serrated adenoma, as were tumor markers (CA 19-9: 15U/ml, CA 125: 30 U/ml, alpha-fetoprotein:

15ng/ml, and CEA: 4.0ng/ml), all of which without any abnormal results. He eventually underwent cystoprostatectomy, urethrotomy with extended bilateral pelvic lymph node dissection. The margins and lymph nodes were negative for tumor invasion. (Figure 6)

Discussion

Adenocarcinoma of the bladder is an uncommon malignant neoplasm and accounts for fewer than 2% of all malignant urinary bladder tumors.⁵ The normal bladder mucosa is lined by transitional cell epithelium with absence of glandular epithelium. The formation of adenocarcinoma in an organ which normally does not contain glandular tissue is fairly rare.² The majority of primary adenocarcinomas of the urinary bladder (50-60%) arise at the bladder base and almost all of the remaining is associated with urachal remnants. In the present case, the location of the mass was the bladder trigone. Most patients are middle approximately 62 years. Hematuria is the most common presenting sign, manifested in about 90% of patients.² Almost half of the patients complain about dysuria, nocturia, frequency and pain. The patient also presented with hematuria and dysuria.

According to Pan X, et al., there are three hypotheses regarding the histological origin: The first is urachal remnants in the bladder; the second is a vestigial embryonal gland in the transitional epithelium of the bladder; and the third is the transitional epithelium of the bladder undergoing glandular metaplasia. Glandular cystitis is

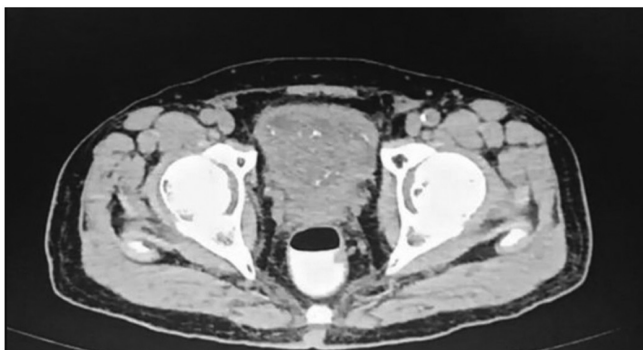


Figure 1: CT scan abdomen axial view showing diffusely thickened bladder wall and a fungating mass 6cm in widest AP diameter.

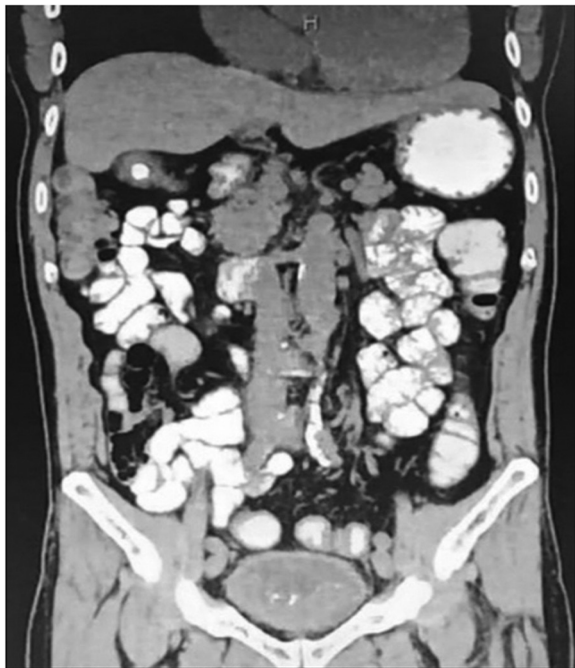

Figure 2: CT scan abdomen coronal view showing diffusely thickened urinary bladder wall and a fungating mass with calcifications in the bladder base 4.6cm in widest AP diameter.

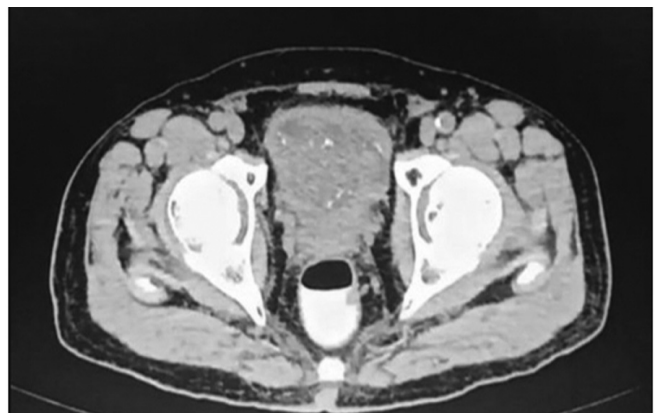

Figure 3: CT scan abdomen axial view.

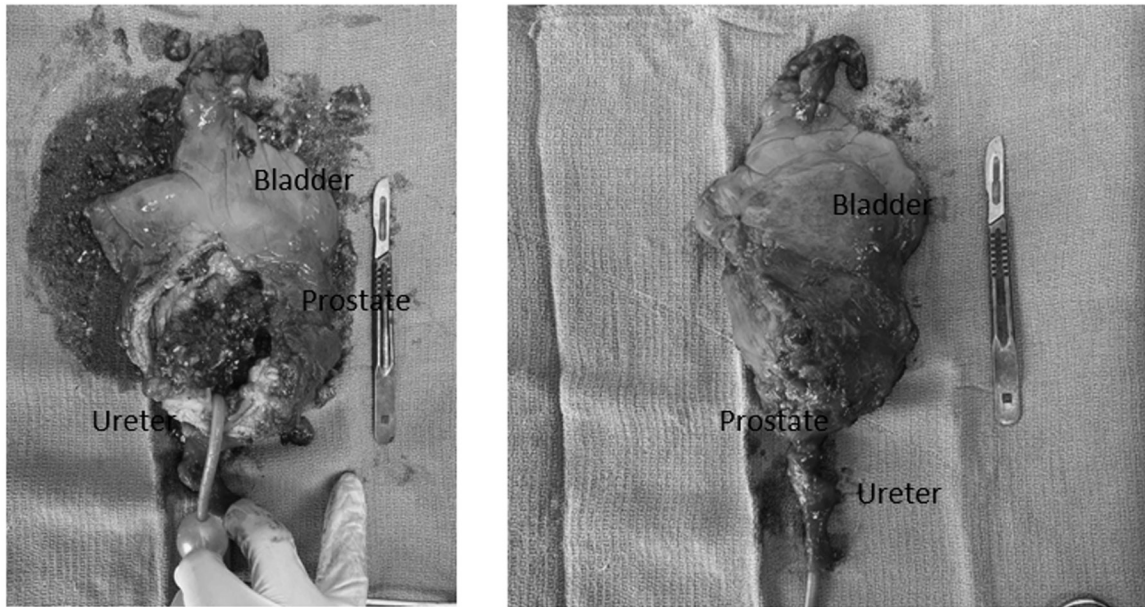


Figure 4: Gross specimen bladder, prostate and urethra.

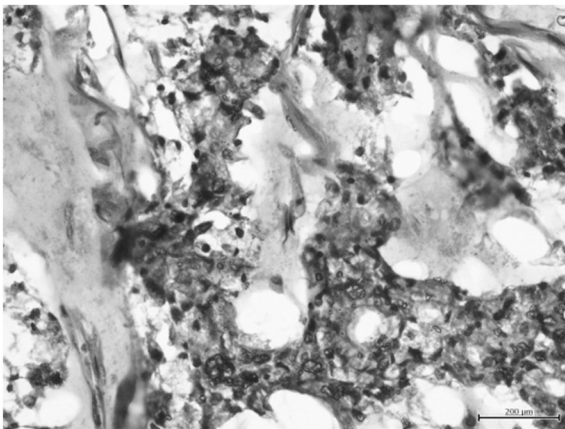


Figure 5: Note of mucinous adenocarcinoma using H&E stain.




Figure 6: Negative for lymph nodes.

widely considered as a precancerous condition for bladder adenocarcinoma.⁶ The mucosa in bladder adenocarcinoma is not smooth, resembling edematous surface villi, or even papilloma-like changes on cystoscopy. The accumulation of secretions and associated infection may promote the development of adenocarcinoma. As the adenocarcinoma cells secrete copious amounts of mucus, mucous floccules may be discharged from the bladder during micturition or cystoscopy. Shivangi L, et al., noted that chronic irritation

(infection, calculi, indwelling catheters) and exposure to carcinogens may induce epithelial proliferation forming epithelial nests (Brunner nests), such tumors are located most commonly in the trigone. A proportion of the patients may only present with signs of bladder irritation and difficulty urinating.²

Wright JL, et al. discussed that distinguishing between mucinous bladder adenocarcinoma and urachal carcinoma is crucial, but may be challenging, as their presentations may be

similar.⁷ The primary clinical signs of bladder adenocarcinoma are hematuria and dysuria, whereas mucosuria is observed in 90% of urachal carcinomas. Furthermore, the treatment of urachal carcinoma is partial cystectomy with en bloc resection of the urachus, rather than radical cystectomy. In addition, urachal carcinoma has a better prognosis and high survival rate compared with mucinous adenocarcinoma of the bladder.

Pan, et al. added that the growth pattern of adenocarcinoma cells mainly involves infiltration into the deep muscular layer; thus, cystoscopy and B-mode ultrasound may be unable to assess the extent of infiltration.⁶ Therefore, the majority of bladder mucinous adenocarcinoma patients are stage T2 or T3 at diagnosis. When a tumor is identified at the bladder dome, trigone or lateral wall, or in patients presenting with mucous floccules discharged from the bladder during micturition or cystoscopy, the presence of bladder adenocarcinoma should be taken into consideration. Tumor tissue biopsy and CT are required. Several random biopsy samples and regular follow-up visits are also required for patients with glandular cystitis. Bladder adenocarcinoma is resistant to chemotherapy and radiation; thus, for patients with confirmed or highly suspicious mucinous adenocarcinoma of the bladder, timely radical resection is warranted.

Zaghoul, et al., did a retrospective study of long-term results of primary adenocarcinoma of the urinary bladder wherein 192 patients had adenocarcinoma. Mucinous adenocarcinoma was reported in 28 patients (14.6%).⁸ The 5-year disease-free survival rate of all 192 patients with adenocarcinoma was 46±4%. There was no difference in survival rates between males and females (46±5% vs. 49±7%, respectively). The

5-year disease-free survival rate decreased with the advancement of the level of tumor infiltration.

Conclusion

The prognosis of mucinous bladder adenocarcinoma depends mainly on its stage when diagnosed and treated. Adenocarcinoma is diagnosed mainly on histopathology and with the help of Immunohistochemistry (IHC). Once the diagnosis is confirmed, the radical surgery should be advised which could improve survival and disease progression.

References

1. Campbell MF, Wein AJ, Kavoussi LR. (Eds.) Campbell-Walsh Urology Philadelphia : W.B. Saunders,
2. Shivangi P, Gunvanti R, Purva S. Adenocarcinoma of urinary bladder in 55 years old male patient - A rare case report. IAIM 2015; 2(1): 116-20.
3. Santos BM, de Souza JD, Lima RS, de Lima EM. Mucinous bladder adenocarcinoma: Case report and literature review. Case Rep Urol 2015:783109.
4. Baffigo G, Delicato G, Bianchi D, et al. Mucinous adenocarcinoma of the urinary bladder. Am J Case Rep 2012; 13: 99-101.
5. Payal K, Yair L, Ellen K, Wareef K, Anirban P, Ahmed M, et al. Primary adenocarcinoma of the urinary bladder: Value of cell cycle biomarkers. Am J Clin Pathol 2011; 135(6): 822-30.
6. Pan X, Jin L, He T, et al. Mucinous adenocarcinoma of the bladder: A case report and review of the literature. Mol Clin Oncol 2016; 5(4): 447-8.
7. Wright JL, Porter MP, Li CI, Lange PH, Lin DW. Differences in survival among patients with urachal and nonurachal adenocarcinomas of the bladder. Cancer J 2006; 107(4): 721-8.
8. Zaghoul MS, Nouh A, Nazmy M. et al. Long-term results of primary adenocarcinoma of the urinary bladder: a report on 192 patients. Urol Oncol 2006; 24(1): 13-20.