



REVIEW ARTICLE

Central nervous system infections caused by pathogenic free-living amoebae: An Indian perspective

Raju, R.¹, Khurana, S.², Mahadevan, A.³, John, D.V.^{4*}

¹KIDWAI Memorial Institute of Oncology Research & Training Centre, Bangalore, India

²Department of Medical Parasitology, Post Graduate Institute of Medical Education and Research, Chandigarh, India

³Department of Neuropathology, National Institute of Mental Health and Neurosciences, Bangalore, India

⁴Department of Neuromicrobiology, National Institute of Mental Health and Neurosciences, Bangalore, India

*Corresponding author: daisyvanitha@gmail.com

ARTICLE HISTORY

Received: 20 December 2021

Revised: 16 May 2022

Accepted: 17 May 2022

Published: 30 June 2022

ABSTRACT

Pathogenic free-living amoebae (FLA), namely *Acanthamoeba* sp., *Naegleria fowleri* and *Balamuthia mandrillaris* are distributed worldwide. These neurotropic amoebae can cause fatal central nervous system (CNS) infections in humans. This review deals with the demographic characteristics, symptoms, diagnosis, and treatment outcomes of patients with CNS infections caused by FLA documented in India. There have been 42, 25, and 4 case reports of *Acanthamoeba* granulomatous amoebic encephalitis (GAE), *N. fowleri* primary amoebic meningoencephalitis (PAM), and *B. mandrillaris* meningoencephalitis (BAE), respectively. Overall, 17% of *Acanthamoeba* GAE patients and one of the four BAE patients had some form of immunosuppression, and more than half of the *N. fowleri* PAM cases had history of exposure to freshwater. *Acanthamoeba* GAE, PAM, and BAE were most commonly seen in males. Fever, headache, vomiting, seizures, and altered sensorium appear to be common symptoms in these patients. Some patients showed multiple lesions with edema, exudates or hydrocephalus in their brain CT/MRI. The cerebrospinal fluid (CSF) of these patients showed elevated protein and WBC levels. Direct microscopy of CSF was positive for amoebic trophozoites in 69% of *Acanthamoeba* GAE and 96% of PAM patients. One-fourth of the *Acanthamoeba* GAE and all the BAE patients were diagnosed only by histopathology following autopsy/biopsy samples. Twenty-one *Acanthamoeba* GAE survivors were treated with cotrimoxazole, rifampicin, and ketoconazole/amphotericin B, and all eleven PAM survivors were treated with amphotericin B alongside other drugs. A thorough search for these organisms in CNS samples is necessary to develop optimum treatment strategies.

Keywords: CNS infections; pathogenic free-living amoebae; *Acanthamoeba*; *Balamuthia mandrillaris*; *Naegleria fowleri*.

INTRODUCTION

Pathogenic free-living amoebae (FLA), namely *Acanthamoeba* sp., *Naegleria fowleri*, *Balamuthia mandrillaris*, *Sappinia* sp., and *Paravahlkampfia francina*, are distributed worldwide. Studies conducted in north Indian states show the presence of FLA in natural and artificial water bodies (Panda *et al.*, 2015; Krishnamoorthi *et al.*, 2022). These neurotropic amoebae can cause central nervous system (CNS) infections in humans, such as primary amoebic meningoencephalitis (PAM), chronic granulomatous amoebic encephalitis (GAE), and nonlethal encephalitis (Lorenzo-Morales *et al.*, 2011; Król-Turmińska & Olender, 2017). There is no effective treatment for the CNS infections caused by these organisms, resulting in high mortality among patients with these infections (da Rocha-Azevedo *et al.*, 2009). The present review deals with the demographic characteristics, symptoms, cerebrospinal fluid (CSF) and brain tissue characteristics, diagnosis, and treatment outcomes of patients with CNS infections caused by three pathogenic FLA

reported in India. Infections due to *Sappinia* spp. and *P. francina* have not been reported to date.

***Acanthamoeba* granulomatous amoebic encephalitis**

Acanthamoeba are widespread FLA capable of causing GAE, keratitis, pneumonitis, and cutaneous infection in humans. GAE, also known as *Acanthamoeba* granulomatous encephalitis, is an opportunistic and slowly progressive fatal disease produced by several species of *Acanthamoeba* (namely, *A. castellanii*, *A. culbertsoni*, *A. hatchetti*, *A. healyi*, *A. polyphaga*, *A. rhyodes*, *A. astronyxis*, and *A. divionensis*) (Visvesvara *et al.*, 2007). These species can be isolated from the natural environment and from swimming pools, sewages, domestic tap water, contact lenses/cases, and so on (Bose *et al.*, 1990; Devi & Mahanta, 2019). In hospital settings, these species have been isolated from dental treatment units, dialysis units, humidifiers, ventilators, eyewash stations, and water sources used for drinking, bathing, and handwashing by high-risk patients in ICUs (Khurana *et al.*, 2015a; Visvesvara *et al.*, 2007). The life cycle of *Acanthamoeba* includes trophozoite and cyst stages, and the trophozoites have

distinct, spiny surface projections called acanthopodia (Figure 1) (Marciano-Cabral & Cabral, 2003). Metagenomic analysis has shown that *A. castellani* has a mitochondrial genome of 41,591 bases, comprising 70.6% AT (Greninger et al., 2015). There are 21 different genotypes of *Acanthamoeba* based on nucleotide sequence variations in the 18S rRNA gene (Kalra et al., 2020). Genotypes T4, T10, and T11 have been shown to cause GAE, and genotype T4 has been predominantly associated with CNS infections in India (Behera et al., 2016; Megha et al., 2018). *Acanthamoeba* isolated from environmental or clinical specimens has been found to harbor pathogenic bacteria, such as *Rickettsia* and *Legionella pneumophila*, indicating that *Acanthamoeba* could serve as reservoirs for bacterial pathogens and may therefore be a source of bacterial infections (Kalra et al., 2020). *Acanthamoeba* GAE are usually identified in biopsies of brain lesions during the late stage of the disease process or in autopsy (da Rocha-Azevedo et al., 2009).

Acanthamoeba GAE was first reported in 1972 (Jager & Stamm, 1972). *Acanthamoeba* meningitis was first reported in 1984 in India; since then, 42 case reports (Table 1) and one retrospective study of *Acanthamoeba* GAE have been documented (Behera et al., 2016). The reported cases of *Acanthamoeba* GAE may be low due to the inherent difficulty in diagnosis and unfamiliarity with the illness. Of the 42 case reports of *Acanthamoeba* GAE, 17 were reported in New Delhi and the others were reported in different regions of India (Tables 1 & 4). Twenty-seven (64%) of these patients were males, and 27 (64%) were children and teenagers. Two of these patients had history of water-related activities and one had a history of sewage cleaning, during which amoebae might have reached the CNS directly through the olfactory neuroepithelium (Lalitha et al., 1985; Das et al., 2020; Singh et al., 2020). One of the patients had geophagia, and another had suffered a head injury (Singhal et al., 2001; Das et al., 2016). The route of this infection might occur by inhalation of cysts or trophozoites through the respiratory tract or breaks in skin and invasion of the CNS by hematogenous spread from the lungs or skin. *Acanthamoeba* GAE is often seen in immunocompromised

individuals, in whom metabolic, physiological, or immunological integrity is compromised (Khan, 2008). This condition can occur in immunocompetent individuals as well. Table 1 shows that 83% of *Acanthamoeba* GAE cases were found to be immunocompetent, while only 17% (7/42) had some form of immunosuppression, such as leukemia, systemic lupus erythematosus (SLE; two patients each), AIDS, malignancy, or malnourishment (one patient each). One patient had an *Acanthamoeba* secondary infection in an underlying brain cyst (Ranjan et al., 2009).

Symptoms: The incubation period for *Acanthamoeba* GAE may vary from several weeks to months. This condition has a gradual onset with a subacute to chronic course of focal neurologic symptoms that can mimic other disorders - neurocysticercosis, toxoplasmosis, tuberculoma, brain tumors, viral encephalitis, and bacterial or tubercular meningitis (Visvesvara et al., 2007). Patients with *Acanthamoeba* GAE in this review presented with fever (64%), headache (64%), vomiting (54%), seizures (30%), and altered sensorium (21%), and a few have presented with loss of consciousness, stiff neck, photophobia, vertigo, ataxia, and lower limb weakness (Tables 1 & 4).

Diagnosis: Neuroradiologic findings of *Acanthamoeba* GAE are usually nonspecific. In this review, neuroimaging showed multiple lesions with edema or hydrocephalus in 17 patients and hydrocephalus in four patients. CT/MRI results were normal in ten patients. CSF showed elevated protein and white blood cell levels in half of the patients, with mostly lymphocytes in 15 cases and polymorphonuclear leucocytes in seven cases. Definitive diagnosis of *Acanthamoeba* GAE is accomplished by direct microscopic demonstration of trophozoites in the CSF or brain tissue and growth on 2% non-nutrient agar overlaid with *Escherichia coli* (da Rocha-Azevedo et al., 2009). *Acanthamoeba* can be cultured axenically in a liquid medium with supplements and antibiotics (Megha et al., 2017). In this review, 29 CSF samples showed motile amoeba on a wet mount, five of which were confirmed by Giemsa staining. *Acanthamoeba* cultures were positive in 25 samples, and no growth

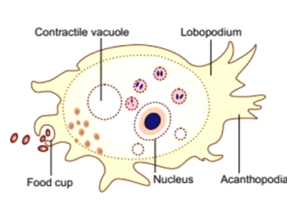
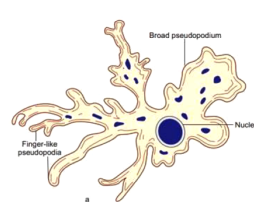
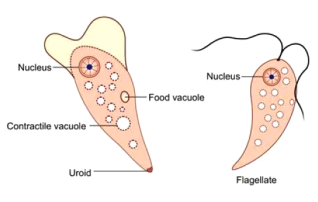
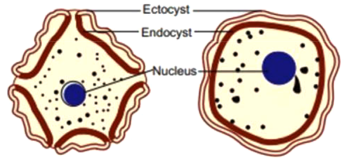
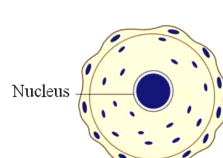
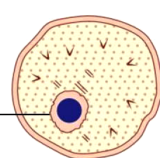
	<i>Acanthamoeba</i>	<i>Balamuthia mandrillaris</i>	<i>Naegleria fowleri</i>
	Granulomatous amoebic encephalitis, subacute to chronic presentation		Primary amoebic meningoencephalitis, acute presentation
Trophozoite/Flagellate	 <p>25-40µm Nucleus with large karyosome Thorn/spine like pseudopodia called acanthopodia</p>	 <p>15-60µm Broad/finger-like pseudopodia</p>	 <p>10-30µm (9-15µm when inactive) Elongated with a blunt lobopodia</p>
Cysts	 <p>10-25µm Double-walled with a wrinkled ectocyst on the outside and an endocyst on the inside</p>	 <p>10-25µm Triple-layered cyst walls</p>	 <p>7-15µm Spherical in shape Thin cyst wall with mucoid plugs or ostioles</p>

Figure 1. Schematic diagrams of Free-living amoebae (Khurana & Mewara, 2021). (Adapted with permission)

Table 1. *Acanthamoeba* granulomatous encephalitis in India

Place of study	Age in Yrs /Sex	Symptoms & *Risk factors	CSF biochemistry (mg/dl) & Cell count/cubic mm.	Neuroimaging CT/MRI		Diagnosis		Histopathology	Treatment Empirical/ Specific	Outcome
				Trophozoites/ Cysts-WM/S	Culture	Trophozoites/ Cysts-WM/S	Culture			
Lokamanya Tilak Municipal General Hospital, Sion, Bombay (Gogate et al., 1984)	15/F	Fever Nausea Vomiting	Protein: 320 mg Glucose: 150 mg Cell count: 60 cells Polymorphs: 35% Lymphocytes: 60%	NA	NA	Positive	Positive	Autopsy: Necrotising haemorrhagic lesions with amoebae	Ampicillin Neomycin	Died
	19/M	Fever, Drowsy Headache Vomiting	Protein: 170 mg Glucose: 90 mg Cell count: 1700 cells	NA	NA	Positive	Positive	Autopsy: Necrotising haemorrhagic lesions with amoebae	Chloramphenicol	Died
Christian Medical College and Hospital, Vellore. (Lalitha et al., 1985)	40/M	Fever, Head-ache, Neck pain, lethargy *Bathed in a pond	Protein: 110 mg Glucose: 88 mg Cell count: 2960 cells Neutrophils: 94% Lymphocytes: 6%	Normal	Normal	Positive	Positive	Not done	Penicillin Chloramphenicol	Cured
Seth G.S. Medical College, Parel, Bombay (Karande et al., 1991)	0.15 /M	Seizure Poor feeding Tonic spasms Loss of consciousness	Protein: 660 mg Sugar: 16 mg Cell count: 280 cells Polymorphs: 220 Lymphocytes: 60	Lesion in right frontal lobe with hydrocephalus	Lesion in right frontal lobe with hydrocephalus	Positive	Positive	Not done	Cotrimoxazole 5-fluorocytosine Sulphadiazine	Cured
Univ. College of Medical Sciences, Shahdara, Delhi (Sharma et al., 1993)	12/F	Fever Headache Vomiting Stiff neck	Protein: 65 mg Sugar: 45 mg Cell count: 300 cells Polymorphs: 100%	Normal	Normal	Positive	Positive	Not done	Cotrimoxazole	Cured
Dr. Rajendra Prasad Centre for Ophthalmic Sciences, All India Institute of Medical Sciences (AIIMS), New Delhi (Singhal et al., 2001)	8/M	Headache Vomiting Neck stiffness	Protein: > 1 g Glucose: 18 mg Cell count: 250 cells Lymphocytes: 100%	Hydrocephalus with basal exudates	Hydrocephalus with basal exudates	Positive	Positive	Not done	Cotrimoxazole	Died
	8/F	Fever Headache Vomiting Seizures	Protein: 200 mg Glucose: 21 mg Cell count: 150 cells Lymphocytes: 100%	Multiple lesions	Multiple lesions	Positive	Positive	Not done	Cotrimoxazole Ketoconazole Rifampin	Cured
	3/M	Fever Headache Vomiting Seizures	Protein: 17 mg Glucose: 87 mg Cell count: 200 cells Lymphocytes: 180	Normal	Normal	Positive	Positive	Not done	Cotrimoxazole Ketoconazole Rifampin	Cured
Jawaharlal Inst. of Postgraduate Med.	45/F	*Head injury Fever Malaise	Protein: 90 mg Sugar: 46 mg	Normal	Normal	Positive	No growth	Not done	Cotrimoxazole Fluconazole	Cured

Education & Research, Pondicherry (Hamide et al., 2002)	26/M	Neck stiffness	Cell count: 1000 cells Neutrophils: 77% Lymphocytes: 23%	Lesion in R-temporoparietal L-cerebellar region, edema	NA	NA	Excised tissue biopsy: Trophozoites	Rifampicin Ceftriaxone Albendazole ATT Steroid	Died
Grant Medical College Byculla, Mumbai (Velho et al., 2003)	24/F	Headache Weakness in lower limbs	NA	Multiple lesions in left cerebellar hemisphere	NA	NA	Autopsy: Necrotic haemorrhagic lesions with cysts, & trophozoites PCR, brain tissue: Acanthamoeba	Ceftriaxone Phenytoin Pulse steroids	Died
Hinduja National Hospital and Research Centre, Mumbai (Shirwadkar et al., 2006)	14/F	Fever Seizures Neck stiffness Loss of consciousness. *SLE	Protein: 174 mg Glucose: 42 mg Leukocytes: 1 cell	Multiple lesions in L-parietal lobe with edema	NA	NA	Autopsy: Necrotic haemorrhagic lesion, amoebic trophozoites	NA	Died
Postgraduate Institute of Medical Education and Research (PGIMER), Chandigarh (Singh et al., 2006)	10/M	Seizure, Loss of consciousness, Neck rigidity, R-hemiparesis	Protein: 52 mg Glucose: 63 mg	Lesion in L-frontal lobe	NA	Positive	Not done	Ketoconazole Rifampicin ATT	Cured
	19/F	Headache, Vomiting Unsteady gait	Protein: 60 mg Glucose: 91 mg	Multiple lesions with edema, cystic lesion in L-parietal lobe	NA	NA	Autopsy: Necrotic, haemorrhagic lesions, amoebic trophozoites	NA	Died
	38/M	Headache, vomiting, Altered sensorium	NA	Lesions in left parietal lobe with edema	NA	NA	Autopsy: GAE	NA	Died
AIIMS, New Delhi (Kumar et al., 2007)	24/M	*AIDS	NA	NA	Positive	Positive	NA	NA	NA
AIIMS, New Delhi (Gupta et al., 2008)	17/M	Seizure Hemiparesis	NA	Normal	NA	Positive	NA	Cotrimoxazole Ketoconazole Rifampicin	Died
Dayanand Med. College & Hosp. Ludhiana Punjab (Kaushal et al., 2008a)	63/F	Headache Vomiting Altered sensorium	Protein: 26 mg Glucose: 96 mg Cell count: 10 cells Mostly lymphocytes	Normal	Positive	Positive	Not done	Cotrimoxazole Fluconazole Rifampicin Amphotericin B	Died
AIIMS, New Delhi (Radhakrishnan et al., 2009)	14/M	Mood swings *ALL	Protein and sugar - Normal	Normal	Positive	Positive	Not done	Cotrimoxazole Ketoconazole	Died
St Stephen's Hospital, New Delhi (Ranjan et al., 2009)	25/M	Seizure	Protein: 150 mg Glucose: 20 mg Cell count: 8 cells Lymphocytes: 90%	Cystic lesion	Positive	NA	Excised cyst: Glial ependymal cyst	Rifampicin Cotrimoxazole Fluconazole	Cured
Sita Ram Bharti Institute, New	15/F	Headache, Fe-ver, vomiting	Protein: 199 mg Cell count: 50 cells	Normal	Positive	Positive	Not done	Cotrimoxazole Ketoconazole	Cured

Author(s)	Age	Sex	Location	Photophobia	Lymphocytes: 96%	Lesion in R-parietal lobe	Positive	No growth	Autopsy: Necrotic haemorrhagic lesions, amoebic cysts, trophozoites	Rifampicin	Died
Delhi. (Saxena et al., 2009) Nizam's Institute of Medical Sciences, Hyderabad (Reddy et al., 2011)	38/M			Photophobia Headache Fever, Seizure Weakness of left limbs	NA	Lesion in R-parietal lobe	Positive	No growth	Autopsy: Necrotic haemorrhagic lesions, amoebic cysts, trophozoites	Rifampicin ATT Steroids	Died
PGIMER, Chandigarh. (Khurana et al., 2012)	3/M			Fever, seizures Vomiting, Alt-ered sensorium *Malnutrition	Protein: 265 mg Sugar: 37 mg Cell count: 240 cells Polymorphs: 100%	Hydrocephalus	NA	Positive	Not done	Cotrimoxazole Ketoconazole Rifampicin	Cured
PGIMER, Chandigarh (Vyas et al., 2013)	18/M			Headache Vomiting Altered sensorium	Protein: 132 mg Glucose: 71 mg Cell count: 20 cells Lymphocytes: 100%	Lesion in L-frontoparietal lobe with edema	NA	NA	Autopsy: Haemorrhagic, necrotic lesions, Trophozoites	Vancomycin Ceftriaxone Steroids	Died
National Institute of Mental Health & Neurosciences (NIMHANS), Bangalore, Kar-nataka. (Chandra et al., 2014)	16/M			Headache Fever, Right hemiparesis, altered sensorium	NA	Multiple lesions in thalamus, brain stem, corticomedulla-ry junctions and L-basal ganglia	NA	NA	Autopsy: Necrotis-ing haemorrhagic lesions, cysts & trophozoites PCR, brain tissue: Acanthamoeba	ATT Steroids	Died
Kasturba Medical College, Manipal, Karnataka (Khanna et al., 2014)	30/M			Headache Fever Weight loss	Protein: 134 mg Glucose: 34 mg Cell count: 207 cells Mostly lymphocytes	Normal	Positive	Positive	Not done	Cotrimoxazole Rifampicin Fluconazole	Cured
University College of Med. Sciences & Guru Teg Bahadur Hospital, Delhi University, New Delhi (Das et al., 2016)	4/M			Headache, Fever, seizures Vomiting, *Geophagia	Protein: 16 mg% Glucose: 40 mg% Cell count: 20 cells Mostly lymphocytes	Hydrocephalus	Positive	Positive cysts	Not done	Cotrimoxazole Rifampicin Amphotericin B	Died
	10/F			Fever, head-ache, Vomiting Neck rigidity *Malignancy	Protein: 9 mg% Glucose: 84 mg% Cell count:	NA	Positive	Positive	Not done	Cotrimoxazole Rifampicin Amphotericin B	Died
	0.75 /F			Fever Vomiting	Lymphocytes: 4 Protein: 20 mg% Glucose: 65 mg% Cell count: No cells	NA	Positive	Positive	Not done	Cotrimoxazole Rifampicin Amphotericin B	Cured
	12/M			Headache Fever, Altered sensorium	Protein: 10 mg% Glucose: 81 mg% Cell count: No cells	NA	Positive	Positive	Not done	Cotrimoxazole Rifampicin Amphotericin B	Cured
	11/F			Fever, Neck rigidity, Head-ache, vomiting	Protein: 119 mg% Glucose: 23 mg% Cell count: No cells	NA	Positive	No growth	Not done	Cotrimoxazole Rifampicin Amphotericin B	Cured
	9/F			Fever, Seizure Vomiting Neck rigidity *TBM	Protein: 320 mg% Glucose: 16 mg% Cell count: 185 Mostly lymphocytes	NA	Positive	Positive	Not done	Cotrimoxazole Rifampicin Amphotericin B	Died

Age	Sex	Presenting symptoms	Investigations	Imaging	Diagnosis	Treatment	Outcome		
12/F		Fever Vomiting	Protein: 234 mg% Glucose: 27 mg% Cell count: 50 cells Mostly lymphocytes	NA	Positive	Positive	Not done	Cotrimoxazole Rifampicin Amphotericin B	Cured
2/M		Fever, Inability to stand and walk	Cell count: 30,000 Polymorphs: 95% Lymphocytes: 5%	Mild Hydrocephalus	Positive	NA	Not done	Vancomycin Ceftriaxone	Cured
19/M		Headache Fever *AML	Protein: 45 mg Glucose: 46 mg Cell count: No cells	Hypodense lesion in right parietal lobe	Positive	Positive PCR	Excision: amoebic cysts	Cotrimoxazole Rifampicin Ketoconazole Azithromycin	Cured
11/M		Headache Vomiting Unsteady gait	Protein: 4.5 mmol Cell count: 12 cells Polymorphs: 2 Lymphocytes: 10 NA	Lesion in vermis, para-vermian region hydrocephalus	NA	NA	Trophozoites	Cotrimoxazole Ketoconazole	Died
30/M		Headache Fever, Altered sensorium Vomiting	NA	Lesion in basi-frontal, R- frontal lobe, edema	NA	NA	Biopsy: Trophozoites and cysts	NA	Died
28/M		Headache Fever, Neck stiffness *SLE	Protein: 125 mg Glucose: 37 mg Lymphocytic pleocytosis	Multiple lesions in frontal, parietal lobe with edema	NA	NA	Autopsy: Haemorrhagic necrosis, Trophozoites & cysts	Methyl-prednisolone	Died
51/F		Fever, R-sided weakness *Fell into well	Protein: 86 mg/dl Cell count: 340 cells Lymphocytes: 80%	Cerebral arterial territory infarcts	Positive	Positive	Not done	Cotrimoxazole Rifampicin Fluconazole	Cured
22/M		Headache	Protein: Normal Glucose: Normal Cell count: Lymphocytes: 2	Normal	Positive	Positive	Not done	Cotrimoxazole Fluconazole Rifampicin Miltefosine	Cured
15/M		Headache Fever Neck rigidity *Sewage cleaning	Protein: 97 mg/dl Glucose: 30 mg/dl Cell count: 600 Polymorphs 90% Lymphocytes 10%	Hydrocephalus, periventricular ooze, Papilledema	Positive	NA	Not done	Metronidazole Cotrimoxazole Rifampicin Ketoconazole Amphotericin B	Cured
32/M		Headache Vomiting R- side weakness L- hemiparesis Sensorial decline	Protein: normal Sugar: normal Lymphocytes: 4/mL	Lesions in bilateral hemispheres	Positive	NA	Biopsy: Necrotic tissue, Inflammation, amoebic trophozoites	Cotrimoxazole Rifampicin Fluconazole Albendazole Azithromycin Flucytosine Miltefosine	Cured

ALL: Acute lymphoblastic leukaemia; ATT: Anti-tuberculous chemotherapy; CT: Computed tomography; AIDS: Acquired immunodeficiency syndrome; L: Left; MRI: Magnetic resonance imaging; ND: Not done; NA: Not available; PCR: Polymerase chain reaction; R: Right; S: Staining; SLE: Systemic lupus erythematosus; TBM: Tuberculous meningitis; WM: Wet mount; Yrs: Years

was observed in three samples. In ten patients, GAE was diagnosed postmortem in biopsy/autopsy samples, in which histopathology showed hemorrhagic necrotic lesions with amoebic trophozoites and cysts (Table 1). *Acanthamoeba* and *Balamuthia* trophozoites appear morphologically similar in tissue sections under a light microscope; therefore, electron microscopy, indirect immunostaining (IIF), or molecular analysis are required for confirmation (Feingold et al., 1998). Three culture-negative cases showed motile amoebae in wet mounts, which is a common occurrence in CNS infections caused by FLA (Parija et al., 2015). In recent years, PCR has been used to identify *Acanthamoeba* DNA in CSF and brain tissue samples and has been considered as an alternative to conventional methods (Qvarnstrom et al., 2006). In this review, PCR was used effectively to confirm *Acanthamoeba* in the culture or brain tissue/scalp aspirate in four cases (Table 1). A prospective study showed that PCR is as effective as culture methods for the diagnosis of *Acanthamoeba* GAE (Behera et al., 2016).

Treatment: There is no effective drug regimen recommended for *Acanthamoeba* GAE. *In vitro* sensitivity studies with virulent *Acanthamoeba* have shown variable efficacy to ketoconazole, pentamidine, 5-fluorocytosine, polymyxin, sulfadiazine, cotrimoxazole, azithromycin, flucytosine, and amphotericin B (da Rocha-Azevedo et al., 2019). Twenty-one (50%) *Acanthamoeba* GAE patients in this review survived after antimicrobial treatment. One patient was successfully treated with penicillin and chloramphenicol. Others have reported favorable outcomes using combination therapy with cotrimoxazole, rifampicin, and ketoconazole/amphotericin B (Table 1). Miltefosine and albendazole were used in two cases and reported to be effective against *Acanthamoeba* (Aichelburg et al., 2008). Forty-eight percent of patients (n=20) with *Acanthamoeba* GAE died, and nine of these patients were treated with either empirical or anti-tubercular therapy. Eight other patients had unfavorable outcomes despite having been administered with cotrimoxazole, rifampicin, ketoconazole, and amphotericin B. Seven of these patients were below 20 years old, and one was above 60 years of age. No specific reason could be identified for the treatment failure in these patients. The duration of therapy ranged from two to nine months depending on the patient's clinical response and parasitological clearance. It has been suggested that corticosteroid therapy may exacerbate *Acanthamoeba* GAE and should therefore be avoided. Antibodies to *Acanthamoeba* have been demonstrated in serum samples from both healthy individuals and those with GAE. The role of these antibodies in protection against infection remains unknown. However, acquired protective immunity mediated by the T-cell response has been suggested as the reason for the low incidence of *Acanthamoeba* GAE in humans (Marciano-Cabral & Cabral, 2003).

***Naegleria fowleri*: Primary amoebic meningoencephalitis**

Naegleria fowleri is the only pathogenic species of *Naegleria* that causes PAM and is commonly found in fresh water sources, such as rivers, lakes, ponds, hot springs, domestic water supplies, sewage, heating and ventilation units, and swimming pools (Gogate & Deodhar, 1985; Panda et al., 2015). This species is thermophilic and tolerates temperatures up to 45°C. Most cases of *N. fowleri* infections have been associated with bathing in streams, ponds, lakes, and indoor swimming pools during the summer months when the water is warm. Rare cases have occurred following inhalation of airborne cysts, nasal irrigation, and total immersion in bathwater (Stubhaug et al., 2016). Infection occurs when *N. fowleri* trophozoites enter the nasal passages, attach to the olfactory mucosa, migrate along the olfactory nerves, and cross the cribriform plate to the brain (Król-Turmińska & Olender, 2017). *N. fowleri* has three morphological forms: a trophozoite, a flagellate, and a cyst (Figure 1) with a genome size of 29.5 megabases comprising 36.9% GC (Liechti et al., 2019). Bioinformatic analysis revealed 208 predicted secretory proteins in the *N. fowleri* genome and some of them have hydrolyzing function

that may contribute to pathogenicity of PAM and 245 predicted miRNAs with target genes involved in mitochondrial biological processes, including oxidation-reduction, dehydrogenase activity, and the electron transport chain (Padmashree & Swamy, 2015; Liechti et al., 2019).

N. fowleri infection is distributed worldwide, and PAM caused by *N. fowleri* was first reported in 1965 by Fowler and Carter in Australia (Fowler & Carter, 1965). PAM was first reported in India in 1971; since then, 25 cases have been documented, mostly in the northern states (Tables 2 & 4). A few cases of PAM have been reported in newspapers; however, these cases were not included in this review. PAM has most commonly been seen in males (80%), half of whom were children below 15 years. More than fifty percent (n=13) of PAM patients had a history of water-related activities. As predisposing factors, one patient had acute lymphoblastic leukemia (ALL) and another had type 2 diabetes mellitus. It is believed that infections by *N. fowleri* are frequently misdiagnosed and underreported, probably due to inadequate information regarding their pathologies and the fact that patients often die before a definitive diagnosis can be established.

Symptoms: PAM produced by *N. fowleri* has a short incubation period that varies from three to eight days with a sudden onset of neurological symptoms that progress rapidly, leading to coma and death if not treated early. This disease mimics acute bacterial, tuberculous, or viral meningitis/meningoencephalitis (da Rocha-Azevedo et al., 2009). In this review, PAM patients presented with fever (96%), headache (60%), vomiting (52%), altered sensorium (40%), and seizures (33%). A few had unconsciousness, photophobia, poor feeding, delirium, and slurred speech (Tables 2 & 4).

Diagnosis: Imaging studies of PAM have shown purulent exudate with hemorrhagic necrosis throughout the cerebral hemispheres, brain stem, cerebellum, and upper spinal cord (Visvesvara et al., 2007). Neuroimaging data was available in 14 patients, 11 of which showed lesions with hydrocephalus, edema and exudates, and cerebral/cortical atrophy in older patients. The CSF of PAM patients showed elevated protein levels (n=16) and increased numbers of white blood cells (n=18), comprising predominantly polymorphs in 11 and lymphocytes in six patients (Tables 2 & 4). PAM is suspected in patients with symptoms of encephalitis/meningitis and history of contact with freshwater with CSF showing increased levels of polymorphs, protein, and negative bacterial, fungal, tubercular, and viral infections. Diagnoses of PAM are made mostly by direct microscopic examination of CSF wet mounts that show actively motile trophozoites in a linear forward direction (da Rocha-Azevedo et al., 2009). Of the 25 cases reviewed in the present series, amoebic trophozoites were observed in the wet mounts of 24 cases (96%), and only one patient was identified through histopathology tissue section following the patient's autopsy. The wet mount preparation was confirmed by Giemsa staining in four patients and Romanowsky staining in one patient. Ten (42%) patient cultures were positive for *N. fowleri* on non-nutrient agar, and no growth was observed in five patient samples. In another ten patients, cultures were not carried out. Two patient CSF samples were confirmed by species-specific PCR (Tables 2 & 4). A triplex real-time TaqMan PCR assay for simultaneous identification of *Acanthamoeba* spp., *B. mandriallaris*, and *N. fowleri* can allow for rapid detection and identification of pathogenic FLA (Qvarnstrom et al., 2006). *Naegleria* genotypes can be identified by sequencing the 5.8S rRNA gene and the internal transcribed spacer 1 and 2 (ITS1 and ITS2) regions of *N. fowleri* (Visvesvara et al., 2007).

Treatment: The survival of PAM patients depends on prompt diagnosis and initiation of anti-*Naegleria* therapy coupled with intensive supportive care. Amphotericin B is the only agent with established clinical efficacy for PAM and can be used alone or in combination with drugs such as rifampicin, fluconazole, sulfadiazine, miconazole, cotrimoxazole, ketoconazole, ornidazole, and chloramphenicol (da Rocha-Azevedo et al., 2009). Table 2 shows that all the surviving cases of PAM (n=11, 44%) were treated

Table 2. *Naegleria fowleri*, Primary amoebic meningoencephalitis in India

Place of study	Age in Years/Sex	Symptoms & *Risk factors	CSF biochemistry (mg/dl) & Cell count/cubic mm	Diagnosis		Treatment Empirical/ Specific	Outcome
				Neuroimaging CT/MRI	Trophozoites /cysts in WM/S		
B. C. Roy Memorial Hospital for Children, Calcutta, West Bengal (Pan et al., 1971)	3/M	Fever, Unconsciousness *Played in puddle	NA	NA	Positive	Amphotericin B Sulphadiazine Dexamethasone	Cured
	0.5/M	Fever, Seizure Unconsciousness Neck rigidity	NA	NA	Positive	Amphotericin B Sulphadiazine Streptomycin	Cured
Udaipur, Rajasthan (Bedi et al., 1972)	45/F	Fever, Headache, Vomiting, Cough *Bathed in well water	NA	NA	Positive	Penicillin Sulphadiazine	Died
AIIMS, New Delhi (Malhotra et al., 1978)	F	Fever, Headache, Photophobia	NA	NA	Positive	NA	Died
Lady Harding Medical College New Delhi (Singh et al., 1998)	8/M	Fever Headache Vomiting	Protein: 97 mg Glucose: 28 mg Cell count: 1600 cells Mostly neutrophils	Basal meningitis Hydrocephalus	Positive	Amphotericin B Rifampicin	Cured
PGIMER, Chandigarh (Jain et al., 2002)	26/F	Fever, Headache, vomiting Altered sensorium	Protein: 410 mg Glucose: 52 mg Cell count: 950 cells	Multiple lesions in brainstem, cerebellum, temporal, parietal lobes	Positive	Amphotericin B Rifampicin Ornidazole	Cured
Kasturba Medical College, Mangalore, Karnataka (Shenoy et al., 2002)	0.4/M	Fever, Vomiting, Seizure, Unconsciousness, Coma *Bathed in well water	Protein: 361 mg Glucose: 10 mg Cell count: 130 cells Neutrophils: 80% Lymphocytes: 20%	Hypodense collection in bilateral frontal convexity	Positive (Giemsa)	Amphotericin B Ceftriaxone	Died
Kasturba Medical College, Manipal Karnataka (Hebbal et al., 2005)	0.5/M	Fever, Lethargy Poor feeding Altered sensorium *Bathed in well water	Protein: 4 gm Glucose: 2.4 mmol Cell count: 1540 cells Neutrophils: 16% Lymphocytes: 83%	NA	Positive (Giemsa)	Amphotericin B Chloramphenicol Metronidazole	Died
PGIMER, Chandigarh (Singh et al., 2006)	40/M	Fever, Headache Vomiting Altered sensorium	Protein: 95 mg Glucose: 27 mg	R-basal ganglia infarction, exudates in perimesencephalic cistern	Autopsy: Multiple infarcts, meningeal thickening, exudates and trophozoites	ATT Ceftriaxone	Died

Govt. Medical College, Nanded, Maharashtra (Tungikar et al., 2006)	30/M	Fever, Headache, Vomiting Generalized weakness	Protein: 226 mg Glucose: 26 mg Cell count: Pus cells, Occasional lymphocytes	Cerebral oedema	Positive	NA	Amikacin, Cefotaxime, Penicillin	Died
Dayanand Medical College & Hosp., Ludhiana, Punjab (Kaushal et al., 2008b)	36/M	Fever, Headache, Nausea, Vomiting, Seizure *Bathed in a pond	Protein: 110 mg Glucose: 36mg Cell count: 90 cells Mostly polymorphs	Ill-defined hypodensity in brain stem and hypothalamus	Positive (Giemsa)	<i>N. fowleri</i>	Metronidazole Azithromycin Cloxacillin Amphotericin B Rifampicin Ceftazidime	Died
MLN Medical College, University of Allahabad, Allahabad, UP (Rai et al., 2008)	0.6/M	Fever, Seizure Altered sensorium *Bathed in pond water	Protein: 63.9 mg Glucose: 109.8 mg Cell count: 50 cells Polymorphs: 10% Lymphocytes: 90%	Lesion in left frontal lobe and cerebellar hemisphere	Positive	NA	Amphotericin B Rifampicin Chloramphenicol	Cured
Institute of Medical Sciences, Banaras Hindu University, Varanasi, UP (Tilak et al., 2008)	35/M	Fever, Headache, Vomiting, Altered sensorium, Coma. *Bathed in stagnant water, HIV, Pul. TB	Protein: 258 mg Glucose: 17 mg Cell count: 280 cells Neutrophils: 40% Lymphocytes: 60%	NA	Positive	<i>N. fowleri</i>	ATT Steroid Mannitol Amphotericin B	Died
National Institute of Communicable Diseases, New Delhi (Gupta et al., 2009)	20/M	Fever, Headache, Loss of vision & hearing, Slurred speech, Difficulty swallowing *ALL.	Protein: 56 mg Glucose: 185 mg Cell count: 1500 cells Neutrophils: >90% Few lymphocytes	Normal	Positive	<i>N. fowleri</i>	Amphotericin B Rifampicin	Died
Dr. Rajendra Prasad Govt. Med. College, Himachal Pradesh (Angrup et al., 2010)	85/M	Fever, Headache, Delirium, Altered sensorium, *Bathed in a pond	Protein: 125mg Glucose: 80mg Cell count: 15 cells Mostly polymorphs	Cortical atrophy	Positive	<i>N. fowleri</i>	Amphotericin B Rifampicin	NA
Military Hospital, Bhopal, Madhya Pradesh (Ramanan et al., 2010)	46/F	Fever, Headache, Vomiting Photophobia	Protein: 2.2 gm Glucose: 20 mg Cell count: 1200 cells Mostly neutrophils	NA	Positive (Romanowsky)	No growth	Amphotericin B Rifampicin Cotrimoxazole	Died
Kasturba Medical College, Manipal, Karnataka (Khanna et al., 2011)	0.4/M	Fever, Vomiting Decreased feeding Abnormal body movements	Protein: 731 mg Glucose: 5 mg Cell count: 990 cells Mostly lymphocytes	NA	Positive	NA	Amphotericin Ceftazidime	Died
Dayanand Medical College and Hospital, Ludhiana, Punjab (Gautam et al., 2012)	73/M	Fever, Neck pain, Seizures, Altered sensorium *Head injury, DM T2	Protein: 120 mg Glucose: 165 mg Cell count: 70 cells Polymorphs: 92% Lymphocytes: 8%	Cerebral atrophy	Positive	<i>N. fowleri</i>	Amphotericin B Rifampicin	Cured
Lady Harding Medical College New Delhi (Yadav et al., 2013)	0.1/M	Fever, Seizures *Bathed in well water	Protein: 293 mg Glucose: 21 mg Cell count: 300 cells Polymorphs: 100%	Dilated lateral ventricles and hydrocephalus	Positive	<i>N. fowleri</i>	Amphotericin B Rifampicin Fluconazole	Cured

Narinder Mohan Hospital, Ghaziabad, UP (Meenakshi et al., 2014)	5 days /M	Seizure Respiratory distress	NA	NA	Positive	NA	Amphotericin B	Cured										
Dr. Rajendra Prasad Govt. Med. College, Himachal Pradesh (Sood et al., 2014)	6/M	Fever, Headache Altered sensorium *Played with water in a cement tank	Cell count: 415 cells Mostly neutrophils	NA	Positive (Giemsa)	No growth	Amphotericin B Rifampicin Fluconazole	Cured										
Netaji Subhash Chandra Bose Medical College, Jabalpur, Madhya Pradesh (Gupta et al., 2015)	40/M	Fever, Headache. Vomiting Slurred speech *Swimming pool	Protein: 76 mg Glucose: 44 mg Cell count: 82 cells Polymorphs: 3%	Normal	Positive	<i>N. fowleri</i>	ART, ATT Amphotericin B Fluconazole Metronidazole	Cured										
Kothari Medical Centre Kolkata, West Bengal (Ganguly et al., 2017)	15/M	Fever, Headache, Altered sensorium, Seizure *Bathed in river water	Lymphocytes: 95% Protein: 200 mg Glucose: 64 mg Cell count: 210 cells Polymorphs: 12% Lymphocytes: 88%	Normal	Positive CSF: Nested PCR <i>N. fowleri</i>	No growth	NA	Died										
QRG Central Hosp. and Research Centre, Faridabad, Haryana (Mittal et al., 2019)	0.6/F	Fever, vomiting, Seizures, Abnormal body movements, Poor feeding	Protein: 363 mg Glucose: 54 mg Cell count: 1020 cells Polymorphs 90% Lymphocytes 10%	Meningitis, Hydrocephalus	Positive CSF: PCR <i>N. fowleri</i>	NA	Amphotericin B Ceftriaxone Vancomycin Acyclovir	NA										
Velammal Medical College Hospital & Research Institute, Madurai, Tamil Nadu (Perumal-samy et al., 2020)	47/M	Headache Vomiting Altered sensorium *Bathing in a river	Protein 166 mg/dl Glucose: 45 mg/dl Cell count: 30 Polymorphs 70% Lymphocytes 30%	Cribiform base plate defect	Positive	Negative	Amphotericin B Azithromycin	Cured										

ALL: Acute lymphoblastic leukaemia; ATT: Anti-tuberculous chemotherapy; CT: Computed tomography; DM T2: Diabetes mellitus Type 2; HIV: Human immunodeficiency virus; MRI: Magnetic resonance imaging; ND: Not done; NA: Not available; PCR: Polymerase chain reaction; Pul.TB: Pulmonary tuberculosis; WM/S: Wet mount/staining

Table 3. *Balamuthia mandrillaris* encephalitis in India

Place of study	Age in Years /Sex	Symptoms & *Risk factors	CSF biochemistry (mg/dl) & cell count/cubic mm	Diagnosis			Treatment Empirical/ Specific	Out-come
				Neuro-imaging CT/MRI	Histopathology Autopsy/Biopsy	Molecular identification PCR		
AIIMS, New Delhi (Prasad et al., 2008)	22 /M	Numbness in fingers and legs, vertigo, difficulty swallowing, right sided weakness, Seizure. *CSOM	Protein and glucose: Normal Lymphocytes: 5	Lesion in medulla Micro-haemorrhage	Acute haemorrhagic necrotising encephalitis	<i>B. mandrillaris</i> in paraffin block	ATT Methyl-prednisolone Amphotericin B Acyclovir	Died
PGIMER, Chandigarh. (Khurana et al., 2015b)	18/M	Fever, headache, vomiting, slurred speech, right upper & lower limb weakness, altered sensorium	Protein:132 mg Glucose:71 mg Lymphocytes: 20	Multiple lesions in bilateral frontoparietal, left cerebellum, temporal & occipital lobes	Haemorrhagic necrotic lesions, granulomas with trophozoites	<i>B. mandrillaris</i> in fixed tissue section	ATT Ceftriaxone Vancomycin	Died
	18/M	Fever, headache, vomiting	Not done	Lesions in left parafalcine, frontoparietal, parietooccipital, right parietal lobe	Necrotic granulomatous inflammation with trophozoites & cysts	<i>B. mandrillaris</i> in brain biopsy	ATT Albendazole Amphotericin B Clarithromycin	Died
Max Super Speciality Hospital, New Delhi (Tarai et al., 2018)	57/M	Seizures, altered sensorium, unresponsive state *Sarcoidosis	Protein:247 mg Glucose:105 mg Lymphocytes: 5	Multiple lesions, in bilateral cere-bral hemispheres, with internal haemorrhages and edema	Necrotizing haemorrhagic inflammation, with amoebic trophozoites	<i>B. mandrillaris</i> in brain biopsy	Fluconazole Cotrimoxazole Voriconazole	Died

ATT: Anti-tubercular chemotherapy; CSOM: Chronic suppurative otitis media; CT: Computed tomography; MRI: Magnetic resonance imaging; PCR: Polymerase chain reaction

Table 4. CNS infections caused by free-living amoebae in India

	<i>Acanthamoeba</i> GAE (n=42)	<i>Naegleria fowleri</i> PAM (n=25)	BAE (n=4)
Place of study & No. of cases	New Delhi (n=17); Chandigarh (n=7); Maharashtra (n=6); Karnataka (n=4); Vellore (n=3); Hyderabad (n=2); Pondicherry, Punjab and Uttar Pradesh (n=1 each)	New Delhi (n=4); Karnataka, Uttar Pradesh, West Bengal (n=3 each); Chandigarh, Himachal Pradesh, Madhya Pradesh, Punjab (n=2 each); Haryana, Maharashtra, Rajasthan, Tamil Nadu (n=1 each)	Chandigarh (n=2) New Delhi (n=2)
Gender	Males (n=27, 64%); Females (n=15, 36%)	Males (n=20, 80%); Females (n=5, 20%)	Males (n=4)
Age in years	< 20 (n=27, 64%); >20 (n=15, 36%)	<20 (n=12, 48%); > 20 (n=12, 48%); NA (n=1)	<20 (n=2); >20 (n=2)
Risk factors	Leukaemia, SLE, History of water activity (n=2 each);, AIDS, Geophagia, Head injury, Sewage cleaning, Malignancy, Malnourished (n=1 each)	History of water activities (n= 13, 52%); Leukaemia (n=1); Diabetes mellitus Type 2 (n=1)	Sarcoidosis (n=1)
Symptoms	Fever (n=26, 64%);, Headache (n=27, 64%); Vomiting (n=22, 52%); Seizure (n=12, 30%); Altered sensorium (n=9, 21%); Neck stiffness (n=10, 23%)	Fever (n=23, 96%); Headache (n=15, 60%); Vomiting (n=13, 52%); Altered sensorium (n=10, 40%); Seizure (n=8, 33%)	Fever, Headache, Seizure, Vomiting, Altered sensorium (n=2 each)
CSF profile	Protein: Elevated (n=24, 52 mg to >1g) Glucose: Decreased (n=9, 16 to 37 mg) Elevated (n=6, 87 to 150 mg) Cell count: Elevated (n=22, 8 to 1700 cells) Mostly lymphocytes (n=15); polymorphs (n=7)	Protein: Elevated (n=16, 95 mg to 4.0 g) Glucose: Elevated (n=4, 80-185 mg) Decreased (n=2, 5-10 mg) Cell count: Elevated (n=18, 15-1600 cells) Mostly polymorphs (n=11); lymphocytes (n=6)	Elevated Protein (n=2) Range (132-247 mg/dl) Elevated cell count (n=1)
Diagnosis Neuroimaging	Multiple lesions in frontal, parietal, cerebellar, thalamus, vermis regions with edema or hydrocephalus (n=17); hydrocephalus (n=4); cystic lesion (n=1); Arterial infarcts (n=1); Normal (n=10); NA (n=9) Trophozoites & cysts (n=29, 69%); ND (n=13)	Hydrocephalus (n=3); Multiple lesions in brain stem, cerebellum, frontal lobe, cerebral hemisphere, hypothalamus, frontal convexity (n=4); Cortical /cerebral atrophy (n=2), Cerebral edema / exudates (n=2); Cribriform base plate defect (n=1); Normal (n=3); NA (n=10) Trophozoites (n=24, 96%); ND (n=1)	Lesions in medulla, cerebellum, temporal, occipital, parietal region, with edema / haemorrhage (n=4)
Wet mount			Not done
Culture	Positive (n=25, 60%); NG (n=3); ND (n=14)	Positive (n=10, 42%); NG (n=5); NA (n=10)	Not done
Histopathology	Haemorrhagic necrotic lesions with trophozoites and cysts (n=11, 26%); Trophozoites & cysts (n=4, 10%), Cyst (n=1); NA/ND: (n=25)	Multiple infarcts, meningeal thickening gross exudates, and amoebic trophozoites (n=1)	Haemorrhagic necrotic lesions with trophozoites (n=4)
PCR	<i>Acanthamoeba</i> (culture n=1; brain tissue n=2, scalp aspirate n=1)	<i>N. fowleri</i> in CSF (n=2)	<i>B. mandrillaris</i> (n=4)
Tx. outcome	Cured (n=21, 50%); Died (n=20, 48%);NA(n=1)	Cured (n=11, 44%); Died (n=12, 48%); NA (n=2)	Died (n=4)

ND: Not done NA: Not available. NG: No growth; Tx: Treatment

with amphotericin B along with rifampicin and fluconazole or sulphadiazine. Of the 12 (48%) patients who had fatal outcomes, three were treated with empirical therapy and seven received amphotericin B in combination with other drugs. Amphotericin B treatment failure in these patients could have occurred due to extremely young age (Shenoy et al., 2002; Hebbar et al., 2005; Khanna et al., 2011), immunosuppression (Tilak et al., 2008; Gupta et al., 2009), or incomplete treatment (Kaushal et al., 2008b). The duration of treatment for PAM varied from nine days to six weeks (da Rocha-Azevedo et al., 2009). Individuals with history of swimming in freshwater have been found to have IgM and IgG antibodies to *N. fowleri* that persist for several years following recovery from PAM. However, the role of these antibodies in protective responses is unknown. *N. fowleri* cause an acute inflammatory cytokine response that contributes to neuronal damage and irreversible brain damage (Visvesvara et al., 2007). Increased awareness is required for the prevention of PAM, as chlorination of water at 2 ppm is effective against *N. fowleri* trophozoites and warning signs can be placed in recreational waters during the hot summer months.

Balamuthia amoebic encephalitis (BAE)

B. mandrillaris causes GAE, also known as *Balamuthia* amoebic encephalitis (BAE), occurs in healthy and immunosuppressed individuals as well as in animals. This species was first identified as a pathogen in 1986 when it was isolated from the brain of a mandrill baboon at the San Diego Zoo. The life cycle of *Balamuthia* includes a trophozoite and a cyst stage (Figure 1) (Matin et al., 2008). The mitochondrial genome of *B. mandrillaris* strain 2046 has 41,656 bases with 64.8% AT (Greninger et al., 2015). Similar to *Acanthamoeba*, *L. pneumophila* has been found to infect *B. mandrillaris* in vitro (Shadrach et al., 2005). Contact with contaminated soil is a major risk factor for BAE and invasion of the CNS by hematogenous spread from primary sites, such as the skin and the respiratory tract, which are considered the routes of infection (Matin et al., 2008; Schuster et al., 2009). Several human cases of BAE have been reported worldwide, mostly in Latin America, the southwestern United States, and Australia (Jung et al., 2004; Schuster et al., 2009). Four fatal cases of BAE—two each from New Delhi and Chandigarh—have been reported in India (Table 3). All four cases were males, three were immunocompetent, and one had sarcoidosis. Given that 14 (33%) of the cases in the present review with *Acanthamoeba* GAE were not culture-confirmed, some of them could have been due to *B. mandrillaris*, as *Acanthamoeba* and *B. mandrillaris* have similar morphology in tissue sections (Booton et al., 2003). In fact, some cases reported as *Acanthamoeba* have subsequently turned out to be *B. mandrillaris* (Deetz et al., 2003).

Symptoms: BAE has a subacute to chronic course, which may vary from weeks to months or years. Similar to *Acanthamoeba* GAE, the symptoms of BAE may mimic neurotuberculosis, toxoplasmosis, or neurocysticercosis (Matin et al., 2008). Patients with BAE in this review have presented with fever, headache, vomiting, seizures, altered sensorium, right-side weakness, slurred speech, and vertigo (Table 3). However, the signs and symptoms of BAE are generally not initially evident, as BAE patients typically deteriorate days or weeks after becoming symptomatic (Schuster et al., 2009).

Diagnosis: BAE is difficult to diagnose due to its lack of specific characteristics and a lack of familiarity with amoeba morphology in microbiological and histopathological investigations (Yagi et al., 2005). BAE is usually preceded by an initial cutaneous infection, which may appear on the face, trunk, hands, or feet (Doyle et al., 2011; Król-Turmińska & Olender, 2017). MRI and CT of the brains of the BAE patients discussed in this review showed multiple lesions with internal hemorrhage and cerebral edema resembling brain tumors, abscesses, toxoplasmosis, or cysticercosis. The CSF of some of these patients showed elevated protein and lymphocyte levels. However, CSF was negative for trophozoites in all patients (Table 3). Wet mount preparations are often found to be negative for

amoebic trophozoites in cases of GAE caused by *Acanthamoeba* and *Balamuthia* (Parija et al., 2015). Autopsy and biopsy samples of BAE patients have shown granulomatous necrotizing hemorrhagic lesions with amoebic trophozoites and cysts in histopathology sections. In this review, two BAE patients were diagnosed antemortem, two were diagnosed postmortem, and all four cases were confirmed by species-specific PCR in brain tissue (Table 3). *B. mandrillaris* cannot be grown on *E. coli*-coated non-nutrient agar plates, but it is possible to isolate them using tissue cultures (Jung et al., 2004; Schuster et al., 2009).

Treatment: The optimal antimicrobial therapy for BAE remains to be determined. Currently, BAE treatment relies on empirical combination therapy consisting of pentamidine, ketoconazole, fluconazole, flucytosine, sulfadiazine and macrolide antibiotics, azithromycin, or clarithromycin (Schuster et al., 2009). All the patients in this review who were treated with empirical or specific drugs had unfavorable outcomes (Table 3). Antibodies to *B. mandrillaris* have been demonstrated in the serum samples of healthy individuals and BAE patients. However, the role of these antibodies in protective responses remains to be determined (Huang et al., 1999; Schuster et al., 2009). Increased levels of IL-6 production in tissue cultures infected with *B. mandrillaris* suggest that IL-6 has a role in blood-brain barrier permeability (Jayasekera et al., 2005). Wearing protective clothing while working with soil might prevent infection by *B. mandrillaris*.

CONCLUSION

CNS infections caused by pathogenic FLA are underreported because only a few laboratories are capable of performing diagnostic tests for the detection of FLA. It is necessary to impart awareness of the diseases caused by these agents to healthcare workers. Research efforts are needed in the area of rapid diagnostics and optimum treatment of these diseases. Many FLA isolates from the hospital environment could not be identified using conventional PCR with species-specific primers (Khurana et al., 2015a). Next-generation sequencing is necessary to identify undiscovered FLA that may cause CNS infections.

ACKNOWLEDGEMENTS

Daisy Vanitha John is supported by the Women Scientist Scheme of Department of Science and Technology, Government of India.

Conflicting Interest

The author declares that they have no conflict of interests.

REFERENCES

- Aichelburg, A.C., Walochnik, J., Assadian, O., Prosch, H., Steuer, A., Perneczky, G., Visvesvara, G.S., Aspöck, H. & Vetter, N. (2008). Successful treatment of disseminated *Acanthamoeba* sp. infection with miltefosine. *Emerging Infectious Diseases* **14**: 1743-1746. <https://doi.org/10.3201/eid1411.070854>
- Angrup, A., Chandel, Y., Sood, A., Thakur, K. & Jaryal, S.C. (2010). Primary amoebic meningoencephalitis due to *Naegleria fowleri*. *Journal of Institute of Medicine Nepal* **32**: 56-59. <https://doi.org/10.3126/joim.v32i2.4949>
- Bedi, H.K., Devapura, J.C. & Bomb, B.S. (1972). Primary amoebic meningoencephalitis. *Journal of the Indian Medical Association* **58**: 13-14.
- Behera, H.S., Satpathy, G. & Tripathi, M. (2016). Isolation and genotyping of *Acanthamoeba* spp. from *Acanthamoeba* meningitis/meningoencephalitis (AME) patients in India. *Parasites and Vectors* **9**: 442. <https://doi.org/10.1186/s13071-016-1729-5>
- Booton, G.C., Carmichael, J.R., Visvesvara, G.S., Byers, T.J. & Fuerst, P.A. (2003). Identification of *Balamuthia mandrillaris* by PCR assay using the mitochondrial 16S rRNA gene as a target. *Journal of Clinical Microbiology* **41**: 453-455. <https://doi.org/10.1128/JCM.41.1.453-455.2003>

- Bose, K., Ghosh, D.K., Ghosh, K.N., Bhattacharya, A. & Das, S.R. (1990). Characterization of potentially pathogenic free-living amoebae in sewage samples of Calcutta, India. *Brazilian Journal of Medical and Biological Research* **23**: 1271-1278.
- Chandra, S.R., Adwani, S. & Mahadevan, A. (2014). *Acanthamoeba* meningoencephalitis. *Annals of Indian Academy of Neurology* **17**: 108-112. <https://doi.org/10.4103/0972-2327.128571>
- da Rocha-Azevedo, B., Tanowitz, H.B. & Marciano-Cabral, F. (2009). Diagnosis of infections caused by pathogenic free-living amoebae. *Interdisciplinary Perspectives on Infectious Diseases* **2009**: 251406. <https://doi.org/10.1155/2009/251406>
- Das, S., Saha, R., Rani, M., Goyal, R., Shah, D. & Asish, J.K. (2016). Central nervous system infection due to *Acanthamoeba*: A case series. *Tropical Parasitology* **6**: 88-91. <https://doi.org/10.4103/2229-5070.175130>
- Das, S., Gunasekaran, K., Ajjampur, S., Abraham, D., George, T., Janeela, M.A. & Iyadurai, R. (2020). *Acanthamoeba* encephalitis in immunocompetent hosts: A report of two cases. *Journal of Family Medicine and Primary Care* **9**: 1240-1243. https://doi.org/10.4103/jfmpc.jfmpc_1010_19
- Deetz, T.R., Sawyer, M.H., Billman, G., Schuster, F.L. & Visvesvara, G.S. (2003). Successful treatment of *Balamuthia* amoebic encephalitis: Presentation of 2 cases. *Clinical Infectious Diseases* **37**: 1304-1312. <https://doi.org/10.1086/379020>
- Devi, U. & Mahanta, J. (2019). Isolation of *Acanthamoeba* from pond water in Dibrugarh district of Assam: A report. *Tropical Parasitology* **9**: 62-63. https://doi.org/10.4103/tp.TP_34_15
- Doyle, J.S., Campbell, E., Fuller, A., Spelman, D.W., Cameron, R., Malham, G., Gin, D. & Lewin, S.R. (2011). *Balamuthia mandrillaris* brain abscess successfully treated with complete surgical excision and prolonged combination antimicrobial therapy. *Journal of Neurosurgery* **114**: 458-462. <https://doi.org/10.3171/2010.10.JNS10677>
- Feingold, J.M., Abraham, J., Bilgrami, S., Ngo, N., Visvesara, G.S., Edwards, R.L. & Tutschka, P.J. (1998). *Acanthamoeba* meningoencephalitis following autologous peripheral stem cell transplantation. *Bone Marrow Transplantation* **22**: 297-300. <https://doi.org/10.1038/sj.bmt.1701320>
- Fowler, M. & Carter, R.F. (1965). Acute pyogenic meningitis probably due to *Acanthamoeba* sp.: A preliminary report. *British Medical Journal* **2**: 740-742. <https://doi.org/10.1136/bmj.2.5464.734-a>
- Ganguly, S., Malhotra, A., Chowdhuri, M., Ghosal, A., Sardar S. K., Okamoto, K., Dutta, S. & Bhattacharya, S.K. (2017). Intractable seizure in a case of primary amoebic meningoencephalitis caused by the free living amoeba *Naegleria fowleri*. *Archives of Parasitology* **1**:114.
- Gautam, P.L., Sharma, S., Puri, S., Kumar, R., Midha, V. & Bansal, R. (2012). A rare case of survival from primary amoebic meningoencephalitis. *Indian Journal of Critical Care Medicine* **16**: 34-36. <https://doi.org/10.4103/0972-5229.94432>
- Ghadage, D.P., Choure, A.C., Wankhade, A.B. & Bhole, A.V. (2017). Opportunistic free: Living amoeba now becoming a usual pathogen?. *Indian Journal of Pathology & Microbiology* **60**: 601-603. https://doi.org/10.4103/IJPM.IJPM_815_16
- Gogate, A., Singh, B.N., Deodhar, L.P. & Jhala, H.I. (1984). Primary amoebic meningo-encephalitis caused by *Acanthamoeba* (report of two cases). *Journal of Postgraduate Medicine* **30**: 125-128.
- Gogate, A. & Deodhar, L. (1985). Isolation and identification of pathogenic *Naegleria fowleri* (aerobia) from a swimming pool in Bombay. *Transactions of the Royal Society of Tropical Medicine and Hygiene* **79**: 134. [https://doi.org/10.1016/0035-9203\(85\)90258-5](https://doi.org/10.1016/0035-9203(85)90258-5)
- Greninger, A.L., Messacar, K., Dunnebacke, T., Naccache, S.N., Federman, S., Bouquet, J., Mirsky, D., Nomura, Y., Yagi, S., Glaser, C. et al. (2015). Clinical metagenomic identification of *Balamuthia mandrillaris* encephalitis and assembly of the draft genome: The continuing case for reference genome sequencing. *Genome Medicine* **7**: 113. <https://doi.org/10.1186/s13073-015-0235-2>
- Gupta, D., Panda, G.S. & Bakhshi, S. (2008). Successful treatment of *acanthamoeba* meningoencephalitis during induction therapy of childhood acute lymphoblastic leukemia. *Pediatric Blood and Cancer* **50**: 1292-1293. <https://doi.org/10.1002/pbc.21477>
- Gupta, N., Bhaskar, H., Duggal, S., Ghalaut, P.S., Kundra, S. & Arora, D.R. (2009). Primary amoebic meningoencephalitis: First reported case from Rohtak, North India. *The Brazilian Journal of Infectious Diseases* **13**: 236-237.
- Gupta, R., Parashar, M.K. & Kale, A. (2015). Primary amoebic meningoencephalitis. *The Journal of the Association of Physicians of India* **63**: 69-71.
- Hamide, A., Sarkar, E., Kumar, N., Das, A.K., Narayan, S.K. & Parija, S.C. (2002). *Acanthamoeba* meningoencephalitis: A case report. *Neurology India* **50**: 484-486.
- Hebbar, S., Bairy, I., Bhaskaranand, N., Upadhyaya, S., Sarma, M.S. & Shetty, A.K. (2005). Fatal case of *Naegleria fowleri* meningo-encephalitis in an infant: Case report. *Annals of Tropical Paediatrics* **25**: 223-226. <https://doi.org/10.1179/146532805X58166>
- Huang, Z.H., Ferrante, A. & Carter, R.F. (1999). Serum antibodies to *Balamuthia mandrillaris*, a free-living amoeba recently demonstrated to cause granulomatous amoebic encephalitis. *The Journal of Infectious Diseases* **179**: 1305-1308. <https://doi.org/10.1086/314731>
- Jager, B.V. & Stamm, W.P. (1972). Brain abscesses caused by free-living amoeba probably of the genus *Hartmannella* in a patient with Hodgkin's disease. *The Lancet* **2**: 1343-1345. [https://doi.org/10.1016/s0140-6736\(72\)92781-x](https://doi.org/10.1016/s0140-6736(72)92781-x)
- Jain, R., Prabhakar, S., Modi, M., Bhatia, R. & Sehgal, R. (2002). *Naegleria* meningitis: a rare survival. *Neurology India* **50**: 470-472.
- Jayasekera, S., Matin, A., Sissons, J., Maghsood, A.H. & Khan, N.A. (2005). *Balamuthia mandrillaris* stimulates interleukin-6 release in primary human brain microvascular endothelial cells via a phosphatidylinositol 3-kinase-dependent pathway. *Microbes and Infection* **7**: 1345-1351. <https://doi.org/10.1016/j.micinf.2005.05.001>
- Jung, S., Schelper, R.L., Visvesvara, G.S. & Chang, H.T. (2004). *Balamuthia mandrillaris* meningoencephalitis in an immunocompetent patient: An unusual clinical course and a favorable outcome. *Archives of Pathology and Laboratory Medicine* **128**: 466-468. <https://doi.org/10.5858/2004-128-466-BMMIAI>
- Kalra, S.K., Sharma, P., Shyam, K., Tejan, N. & Ghoshal, U. (2020). *Acanthamoeba* and its pathogenic role in granulomatous amoebic encephalitis. *Experimental Parasitology* **208**: 107788. <https://doi.org/10.1016/j.exppara.2019.107788>
- Karande, S.C., Lahiri, K.R., Sheth, S.S., Nadkarni, U.S., Jain, M.K. & Shah, M.D. (1991). *Acanthamoeba* meningoencephalitis complicating pyogenic meningitis. *Indian Pediatrics* **28**: 794-797.
- Kaushal, V., Chhina, D.K., Kumar, R., Pannu, H.S., Dhooria, H.P.S. & Chhina, R.S. (2008a). *Acanthamoeba* encephalitis. *Indian Journal of Medical Microbiology* **26**: 182-184. <https://doi.org/10.4103/0255-0857.40539>
- Kaushal, V., Chhina, D.K., Ram, S., Singh, G., Kaushal, R.K. & Kumar, R. (2008b). Primary amoebic meningoencephalitis due to *Naegleria fowleri*. *The Journal of the Association of Physicians of India* **56**: 459-462.
- Khan, N.A. (2008). *Acanthamoeba* and the blood-brain barrier: The breakthrough. *Journal of Medical Microbiology* **57**:1051-1057. <https://doi.org/10.1099/jmm.0.2008/000976-0>
- Khanna, V., Khanna, R., Hebbar, S., Shashidhar, V., Mundkar, S., Munim, F., Annamalai, K., Nayak, D. & Mukhopadhyay, C. (2011). Primary amoebic meningoencephalitis in an infant due to *Naegleria fowleri*. *Case Reports in Neurological Medicine* **2011**: 782539. <https://doi.org/10.1155/2011/782539>
- Khanna, V., Shastri, B.A., Anusha, G., Mukhopadhyay, C. & Khanna, R. (2014). *Acanthamoeba* meningoencephalitis in immunocompetent: A case report and review of literature. *Tropical Parasitology* **4**: 115-118. <https://doi.org/10.4103/2229-5070.138540>
- Khurana, S., Mewara, A., Verma, S. & Totadri, S.K. (2012). Central nervous system infection with *Acanthamoeba* in a malnourished child. *BMJ Case Reports* **2012**: bcr2012007449. <https://doi.org/10.1136/bcr-2012-007449>
- Khurana, S., Biswal, M., Kaur, H., Malhotra, P., Arora, P., Megha, K., Taneja, N. & Sehgal, R. (2015a). Free living amoebae in water sources of critical units in a tertiary care hospital in India. *Indian Journal of Medical Microbiology* **33**: 343-348. <https://doi.org/10.4103/0255-0857.158543>
- Khurana, S., Hallur, V., Goyal, M.K., Sehgal, R. & Radotra, B.D. (2015b). Emergence of *Balamuthia mandrillaris* meningoencephalitis in India. *Indian Journal of Medical Microbiology* **33**: 298-318. <https://doi.org/10.4103/0255-0857.154887>
- Khurana, S. & Mewara, A. (2021). *Textbook of Medical Parasitology*. Universities Press (India) Private Limited, pp. 137-144.
- Krishnamoorthi, S., Sharma, C., Mewara, A. & Khurana, S. (2022). Environmental water surveillance for free-living amoeba in North India. *Indian Journal of Medical Microbiology* (In press). <https://doi.org/10.1016/j.ijmmb.2022.05.002>
- Król-Turmińska, K. & Olender, A. (2017). Human infections caused by free-living amoebae. *Annals of Agricultural and Environmental Medicine* **24**: 254-260. <https://doi.org/10.5604/12321966.1233568>

- Kumar, M., Jain, R., Tripathi, K., Tandon, R., Gulati, A.K., Garg, A. & Gart, J. (2007). Acanthamoebae presenting as primary meningoencephalitis in AIDS. *Indian Journal of Pathology and Microbiology* **50**: 928-930.
- Lalitha, M.K., Anandi, V., Srivastava, A., Thomas, K., Cherian, A.M. & Chandi, S.M. (1985). Isolation of *Acanthamoeba culbertsoni* from a patient with meningitis. *Journal of Clinical Microbiology* **21**: 666-667. <https://doi.org/10.1128/jcm.21.4.666-667.1985>
- Liechti, N., Schürch, N., Bruggmann, R. & Wittwer, M. (2019). Nanopore sequencing improves the draft genome of the human pathogenic amoeba *Naegleria fowleri*. *Scientific Reports* **9**: 16040. <https://doi.org/10.1038/s41598-019-52572-0>
- Lorenzo-Morales, J., Martín-Navarro, C.M., Martínez-Carretero, E., Piñero, J.E. & Valladares, B. (2011). Encephalitis due to free living Amoebae: An emerging issue in human health. In: Non-Flavivirus Encephalitis, Tkachev, S. (editor). Croatia: InTech, pp. 329-338.
- Malhotra, K.K., Kakar, P.N., Pillay, P., Pathak, L.R. & Chuttani, H.K. (1978). Unusual presentation of primary amoebic meningoencephalitis-A serious diagnostic and therapeutic problem. *The Journal of Tropical Medicine and Hygiene* **81**: 113-115.
- Marciano-Cabral, F. & Cabral, G. (2003). *Acanthamoeba* spp. as agents of disease in humans. *Clinical Microbiology Reviews* **16**: 273-307. <https://doi.org/10.1128/CMR.16.2.273-307.2003>
- Matin, A., Siddiqui, R., Jayasekera, S. & Khan, N.A. (2008). Increasing importance of *Balamuthia mandrillaris*. *Clinical Microbiology Reviews* **21**: 435-448. <https://doi.org/10.1128/CMR.00056-07>
- Meenakshi, N.K., Gupta, S., Bansal, S. & Bhan, S. (2014). Primary meningoencephalitis in a new born due to *Naegleria* spp. - Extremely rare case presentation with review of literature. *Journal of Spine and Neurosurgery* **3**: 5. <http://doi.org/10.4172/2325-9701.1000158>
- Megha, K., Gupta, A., Sehgal, R. & Khurana, S. (2017). An improvised medium for axenic cultivation of *Acanthamoeba* spp. *Indian Journal of Medical Microbiology* **35**: 597-599. https://doi.org/10.4103/ijmm.IJMM_17_151
- Megha, K., Sehgal, R. & Khurana, S. (2018). Genotyping of *Acanthamoeba* spp. isolated from patients with granulomatous amoebic encephalitis. *The Indian Journal of Medical Research* **148**: 456-459. https://doi.org/10.4103/ijmr.IJMR_1564_17
- Mittal, N., Mahajan, L., Hussain, Z., Gupta, P. & Khurana, S. (2019). Primary amoebic meningoencephalitis in an infant. *Indian Journal of Medical Microbiology* **37**: 120-122. https://doi.org/10.4103/ijmm.IJMM_18_371
- Nampoothiri, R.V., Malhotra, P., Jain, A., Batra, N., Gupta, K., Saj, F., Khurana, S., Mahalingam, H., Lal, A., Mukherjee, K. et al. (2018). An unusual case of central nervous system infection during acute myeloid leukemia induction chemotherapy: *Acanthamoeba* Brain Abscess. *Indian Journal of Hematology and Blood Transfusion* **34**: 153-155. <https://doi.org/10.1007/s12288-017-0826-8>
- Nehete, L.S., Kumar, A., Chavali, P., Prabhuraj, A.R. & Devi, B.I. (2018). Fulminant acanthamoebic meningoencephalitis in immunocompetent patients: An uncommon entity. *British Journal of Neurosurgery* **36**: 98-101. <https://doi.org/10.1080/02688697.2018.1485873>
- Padmashree, D. & Swamy, N.R. (2015). Computational identification of putative miRNAs and their target genes in pathogenic amoeba *Naegleria fowleri*. *Bioinformation* **11**: 550-557. <https://doi.org/10.6026/97320630011550>
- Pan, N.R., Roy, B.C. & Ghosh, T.N. (1971). Primary amoebic meningoencephalitis in two Indian children. *Journal of the Indian Medical Association* **56**: 134-137.
- Panda, A., Khalil, S., Mirdha, B.R., Singh, Y. & Kaushik, S. (2015). Prevalence of *Naegleria fowleri* in environmental samples from northern part of India. *PLoS ONE* **10**: e0137736. <https://doi.org/10.1371/journal.pone.0137736>
- Parija, S.C., Dinooop, K. & Venugopal, H. (2015). Management of granulomatous amoebic encephalitis: Laboratory diagnosis and treatment. *Tropical Parasitology* **5**: 23-28. <https://doi.org/10.4103/2229-5070.149889>
- Perumalsamy, V., Sundaramoorthy, R., Ganesan, V. & Geni, V.G. (2020). Survival of primary amoebic meningoencephalitis by *Naegleria fowleri*: First reported case from Tamil Nadu, South India. *Tropical Parasitology* **10**: 150-152. https://doi.org/10.4103/tp.TP_34_19
- Prasad, K., Bhatia, R., Srivastava, M.V., Pardasani, V., Garg, A. & Rishi, A. (2008). Fatal subacute necrotising brainstem encephalitis in a young man due to a rare parasitic (*Balamuthia*) infection. *Practical Neurology* **8**: 112-117. <https://doi.org/10.1136/jnnp.2007.142547>
- Qvarnstrom, Y., Visvesvara, G.S., Sriram, R. & da Silva, A.J. (2006). Multiplex real-time PCR assay for simultaneous detection of *Acanthamoeba* spp., *Balamuthia mandrillaris*, and *Naegleria fowleri*. *Journal of Clinical Microbiology* **44**: 3589-3595. <https://doi.org/10.1128/JCM.00875-06>
- Radhakrishnan, V., Bhatia, R., Panda, G.S. & Bakhshi, S. (2009). Acanthamoebic meningoencephalitis presenting as personality change. *The Pediatric Infectious Disease Journal* **28**: 555. <https://doi.org/10.1097/INF.0b013e31819f3d29>
- Rai, R., Singh, D.K., Srivastava, A.K. & Bhargava, A. (2008). Primary amoebic meningoencephalitis. *Indian Pediatrics* **45**: 1004-1005.
- Ramanan, D., Nalaganta, R., Yadav Ram, K.S. & Ramani, R. (2010). Amoebic meningo-encephalitis. *Indian Journal of Pathology and Microbiology* **53**: 183-184. <https://doi.org/10.4103/0377-4929.59230>
- Ranjan, R., Handa, A., Choudhary, A. & Kumar, S. (2009). *Acanthamoeba* infection in an interhemispheric ependymal cyst: A case report. *Surgical Neurology* **72**: 185-189. <https://doi.org/10.1016/j.surneu.2008.04.008>
- Reddy, R., Vijayasradhi, M., Uppin, M.S., Challa, S., Jabeen, A. & Borghain, R. (2011). *Acanthamoeba* meningoencephalitis in an immunocompetent patient: An autopsy case report. *Neuropathology* **31**: 183-187. <https://doi.org/10.1111/j.1440-1789.2010.01151.x>
- Saxena, A., Mittal, S., Burman, P. & Garg, P. (2009). *Acanthamoeba* meningitis with successful outcome. *The Indian Journal of Pediatrics* **76**: 1063-1064. <https://doi.org/10.1007/s12098-009-0205-z>
- Schuster, F.L., Yagi, S., Gavali, S., Michelson, D., Raghavan, R., Blomquist, I., Glastonbury, C., Bollen, A.W., Scharnhorst, D., Reed, S.L. et al. (2009). Under the radar: *Balamuthia* amoebic encephalitis. *Clinical Infectious Diseases* **48**: 879-887. <https://doi.org/10.1086/597260>
- Sharma, P.P., Gupta, P., Murali, M.V. & Ramchandran, V.G. (1993). Primary amoebic meningoencephalitis caused by *Acanthamoeba*: successfully treated with cotrimoxazole. *Indian Pediatrics* **30**: 1219-1222.
- Shenoy, S., Wilson, G., Prashanth, H.V., Vidyalakshmi, K., Dhanashree, B. & Bharath, R. (2002). Primary meningoencephalitis by *Naegleria fowleri*: First reported case from Mangalore, South India. *Journal of Clinical Microbiology* **40**: 309-310. <https://doi.org/10.1128/JCM.40.1.309-310.2002>
- Shadrach, W.S., Rydzewski, K., Laube, U., Holland, G., Ozel, M., Kiderlen, A.F. & Flieger, A. (2005). *Balamuthia mandrillaris*, free-living amoeba and opportunistic agent of encephalitis, is a potential host for *Legionella pneumophila* bacteria. *Applied and Environmental Microbiology* **71**: 2244-2249. <https://doi.org/10.1128/AEM.71.5.2244-2249.2005>
- Shirwadkar, C.G., Samant, R., Sankhe, M., Deshpande, R., Yagi, S., Schuster, F.L., Sriram, R. & Visvesvara, G.S. (2006). *Acanthamoeba* encephalitis in patient with systemic lupus, India. *Emerging Infectious Diseases* **12**: 984-986. <https://doi.org/10.3201/eid1206.060087>
- Singh, S.N., Patwari, A.K., Dutta, R., Taneja, N. & Anand, V.K. (1998). *Naegleria* meningitis. *Indian Pediatrics* **35**: 1012-1015.
- Singh, P., Kochhar, R., Vashishta, R.K., Khandelwal, N., Prabhakar, S., Mohindra, S. & Singhi, P. (2006). Amoebic meningoencephalitis: Spectrum of imaging findings. *American Journal of Neuroradiology* **27**: 1217-1221.
- Singh, R., Sahu, A., Singh, K., Prasad, R.S. & Pandey, N. (2020). *Acanthamoeba* meningoencephalitis with hydrocephalus in an immunocompetent patient: A case report. *Indian Journal of Case Reports* **6**: 426-429. <https://doi.org/10.32677/IJCR.2020.v06.i08.003>
- Singhal, T., Bajpai, A., Kalra, V., Kabra, S.K., Samantaray, J.C., Satpathy, G. & Gupta, A.K. (2001). Successful treatment of *Acanthamoeba* meningitis with combination oral antimicrobials. *The Pediatric Infectious Disease Journal* **20**: 623-627. <https://doi.org/10.1097/00006454-200106000-00016>
- Siripurapu, G., Samad, S.A., Fatima, S., Wig, N. & Srivastava, M.V.P. (2021). Successful management of post-COVID-19 acanthamoebic encephalitis. *International Journal of Infectious Diseases* **110**: 226-228. <https://doi.org/10.1016/j.ijid.2021.07.046>
- Sood, A., Chauhan, S., Chandel, L. & Jaryal, S.C. (2014). Prompt diagnosis and extraordinary survival from *Naegleria fowleri* meningitis: A rare case report. *Indian Journal of Medical Microbiology* **32**: 193-196. <https://doi.org/10.4103/0255-0857.129834>
- Stubhaug, T.T., Reiakvam, O.M., Stensvold, C.R., Hermansen, N.O., Holberg-Petersen, M., Antal, E.A., Gaustad, K., Førde, I.S. & Heger, B. (2016). Fatal primary amoebic meningoencephalitis in a Norwegian tourist returning from Thailand. *JMM Case Reports* **3**: e005042. <https://doi.org/10.1099/jmmcr.0.005042>
- Tarai, B., Agarwal, P., Krishnamoorthi, S., Mewara, A. & Khurana, S. (2018). Fatal amoebic meningoencephalitis caused by *Balamuthia mandrillaris* in a sarcoidosis patient. *Japanese Journal of Infectious Diseases* **71**: 474-476. <https://doi.org/10.7883/yoken.JIID.2018.179>

- Thamtam, V.K., Uppin, M.S., Pyal, A., Kaul, S., Rani, J.Y. & Sundaram, C. (2016). Fatal granulomatous amoebic encephalitis caused by *Acanthamoeba* in a newly diagnosed patient with systemic lupus erythematosus. *Neurology India* **64**: 101-104. <https://doi.org/10.4103/0028-3886.173662>
- Tilak, R., Tilak, V., Singh, D.P., Rai, M., Agarwal, S.S. & Gulati, A.K. (2008). Primary amoebic meningoencephalitis relatively undiagnosed public health problem. *Indian Journal of Preventive and Social Medicine* **39**: 178-180.
- Tungikar, S.L., Kulkarni, A.G., Deshpande, A.D. & Gosavi, V.S. (2006). Primary amoebic meningoencephalitis. *The Journal of the Association of Physicians of India* **54**: 327-329.
- Velho, V., Sharma, G. K. & Palande, D.A. (2003). Cerebrospinal acanthamoebic granulomas: Case report. *Journal of Neurosurgery* **99**: 572-574. <https://doi.org/10.3171/jns.2003.99.3.0572>
- Visvesvara, G.S., Moura, H. & Schuster, F.L. (2007). Pathogenic and opportunistic free-living amoebae: *Acanthamoeba* spp., *Balamuthia mandrillaris*, *Naegleria fowleri*, and *Sappinia diploidea*. *FEMS Immunology and Medical Microbiology* **50**: 1-26. <https://doi.org/10.1111/j.1574-695X.2007.00232.x>
- Vyas, S., Jain, V., Goyal, M.K., Radotra, B.D. & Khandelwal, N. (2013). Granulomatous amoebic meningoencephalitis. *Neurology India* **61**: 530-531. <https://doi.org/10.4103/0028-3886.121938>
- Yadav, D., Aneja, S., Dutta, R., Maheshwari, A. & Seth, A. (2013). Youngest survivor of *naegleria* meningitis. *Indian Journal of Pediatrics* **80**: 253-254. <https://doi.org/10.1007/s12098-012-0756-2>
- Yagi, S., Booton, G.C., Visvesvara, G.S. & Schuster, F.L. (2005). Detection of *Balamuthia* mitochondrial 16S rRNA gene DNA in clinical specimens by PCR. *Journal of Clinical Microbiology* **43**: 3192-3197. <https://doi.org/10.1128/JCM.43.7.3192-3197.2005>