

RUNX1::RUNX1T1 Fusion in Pediatric Acute Myeloid Leukemia: A Description of Two Cases

Jill Jaime,¹ Ivy Mae Medalla,² Steffanie Charlyne Tamayo,³ Qareem Pido,¹ Francisco Tria IV,^{1,3} Ma. Luisa Enriquez,³ Jean Kamil Sy,¹ Reynaldo De Castro Jr.,¹ Daphne Ang^{1,3}

¹Philippine Children's Medical Center, Quezon City, Philippines

²Eastern Visayas Medical Center, Tacloban City, Leyte, Philippines

³St. Luke's Medical Center, Quezon City, Philippines

ABSTRACT

RUNX1::RUNX1T1 is a core-binding factor driving fusion gene which arises from t(8;21)(q22;q22). It is one of the most common chromosomal rearrangements in both pediatric and adult Acute Myeloid Leukemia (AML) with a reported incidence of 15% in children and young adults. There are few case reports documenting *RUNX1::RUNX1T1* translocation in pediatric AML. Although this is generally associated with a favorable prognosis, we report two (2) cases of de novo pediatric AML in the Philippines harboring a *RUNX1::RUNX1T1* translocation, one eventually relapsed while the other attained remission but succumbed to sepsis.

Key words: Pediatric acute myeloid leukemia, Next Generation Sequencing, *RUNX1::RUNX1T1* fusion, Berlin-Frankfurt-Münster (BFM-87) protocol, AML 15 Medical Research Council protocol

ISSN 2507-8364 (Online)

Printed in the Philippines.

Copyright© 2023 by the PJP.

Received: 6 December 2022

Accepted: 18 January 2023.

Published online first: 25 February 2023.

<https://doi.org/10.21141/PJP.2023.02>

Corresponding author: Jill J. Jaime, MD

E-mail: jillj.jaime@gmail.com

ORCID: <https://orcid.org/0000-0002-3740-0812>

INTRODUCTION

Hematologic malignancies affect approximately 38% of adolescents and young adults worldwide, with leukemias being more prevalent than lymphomas.¹

Acute Myeloid Leukemia (AML) is defined as the presence of myeloid blast count of more than 20% in a bone marrow or peripheral blood smear.² Since morphology alone cannot be used to determine blast lineage, immunophenotyping – either by immunohistochemical staining or by flow cytometry is used to confirm blast lineage.

Flow cytometry, a multi-parametric analytic technique on a cellular basis, assigns the lineage of the progenitor population and facilitates the classification of the acute leukemia.² Expression of markers such as CD33, CD13, HLA-DR, CD11c, cMPO, and CD117 characterizes the cell population of interest as belonging to the myeloid lineage. Flow cytometry is also useful in the detection of residual disease and monitoring of therapeutic response. With the acknowledgement of the role of recurrent genetic aberrations in the pathophysiology, prognosis, and treatment of AML, the demand for cytogenetic and molecular genetic testing continues to increase.³ The presence of certain recurrent genetic abnormalities, such as t(15;17)(q24;q21); *PML::RARA* in acute promyelocytic leukemia, and t(8;21)(q22;q22.1); *RUNX1::RUNX1T1* and inv(16)(p13.1q22) or t(16;16)(p3.1;q22); *CBFB::MYH11* in core binding factor AMLs, may also be used to diagnose AML, even with less than 20% blasts.⁴

In a study by Tamayo et al (2021), most Filipino pediatric cases of de novo AML have a normal karyotype (12/20) and harbors *CBFB::MYH11* (7/20).⁵ While a normal karyotype is associated with a generally intermediate prognosis, the same study also shows that cytogenetically normal patients may harbor significant alterations in *CEBPA*, *FLT3*, *PML*, *RARA*, *TET2*, *ASXL1*, *NPM1*, *RUNX1*, *RUNX1T1*, and



ZRSR2. It has been documented that a higher total number of mutations in core-binding factors and signaling genes at the time of diagnosis correlate with inferior prognosis and relapse.⁶

RUNX1::RUNX1T1 is the fusion gene generated from translocation t(8;21)(q22;q22). It is one of the most common chromosomal rearrangements with an incidence of 15% in children and young adults.⁷ We report two (2) cases of patients with *RUNX1::RUNX1T1* translocation.

CASE 1

A 12-year-old Filipino male presented with a 2-month history of pallor and intermittent fever. The patient had stable vital signs and pale palpebral conjunctiva. Past medical history was unremarkable. There was also no family history of cancer or other hematolymphoid disease. Complete blood count showed anemia (hemoglobin 102.0 g/L, hematocrit 0.28, and red blood cell count $3.4 \times 10^{12}/L$), thrombocytopenia (platelets $21 \times 10^9/L$), and presence of blasts (white blood cell count 7.9×10^9 , Differential count: segmenters 3%, lymphocytes 43% and blasts 54%). These blasts were characterized as having scant cytoplasm, increased nuclear to cytoplasmic ratio,

irregular nuclear membrane, fine chromatin pattern and occasionally conspicuous nucleoli (Figure 1A). Flow cytometry demonstrated 61% myeloblasts with the following immunophenotype: CD13, CD33, CD34, CD117, anti-HLA-DR and cMPO (Figure 1B). These findings were consistent with AML. Cytospin of the patient’s cerebrospinal fluid was negative for malignant cells.

Karyotype was 46,XYqh+ (normal male carrying a heteromorphic variant in the long arm of Y chromosome). The Fluorescence In Situ Hybridization (FISH) analysis using MetaSystems Translocation Probe (MetaSystems Asia Co. Ltd.) showed t(8;21)(q22;q22.1); *RUNX1::RUNX1T1* fusion gene in 50.47% of cells (Figure 2). Next Generation Sequencing (NGS) performed using the AmpliSeq™ for Illumina Myeloid Panel (Illumina, San Diego, CA, USA) run on MiSeq platform confirmed *RUNX1::RUNX1T1*. Additionally, alteration in variants of uncertain significance, *KIT* (*Proto-oncogene c-KIT*) M541L and SH2B3 (*Syc homology 2 B3*) P242S were detected. Berlin-Frankfurt-Münster (BFM-87) protocol for AML was done and patient was inducted with Cytarabine 100mg/m² and Doxorubicin 25mg/m².⁸ After two cycles, a minimal residual disease (MRD) panel showed 10% myeloblasts by flow cytometry. Remission was achieved after three (3) cycles. However, five (5) months after

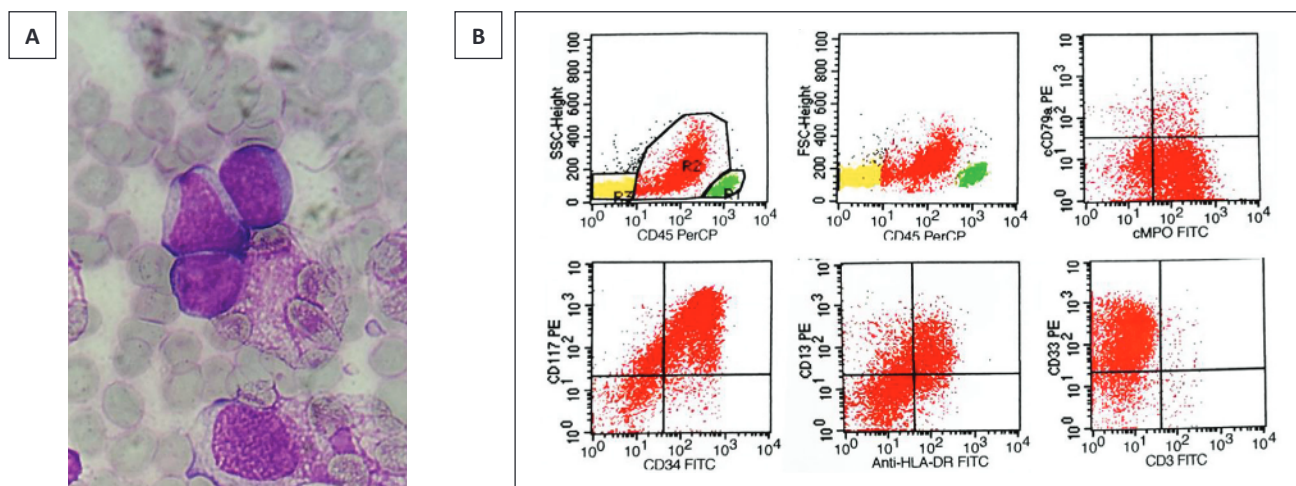


Figure 1. (A) Peripheral blood smear of the patient showing blasts with scant cytoplasm, increased nuclear to cytoplasmic ratio, irregular nuclear membrane, fine chromatin pattern and occasionally conspicuous nucleoli; **(B)** Flow Cytometry shows a dim CD45 blast population with the following immunophenotype: CD13, CD33, CD34, CD117, anti-HLA-DR and cMPO.

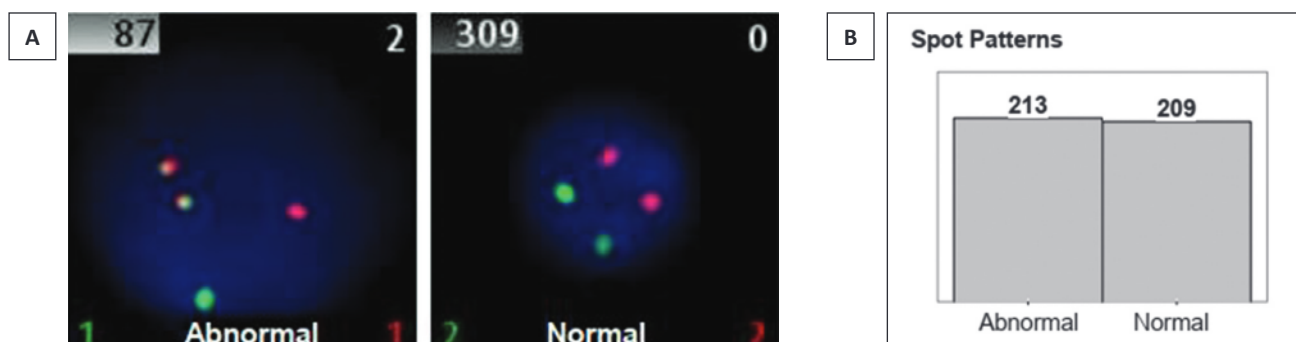


Figure 2. (A) Detection of *RUNX1::RUNX1T1* by Fluorescence in situ Hybridization (FISH). In normal cells, two red signals representing *RUNX1T1* and two green signals representing *RUNX1* are detected. In the abnormal cell containing *RUNX1::RUNX1T1* fusion gene, one red, one green and two red/green (yellow) fusion signals are observed. **(B)** Spot patterns showing 213 out of 422 total cells analyzed or 50.47% having *RUNX1::RUNX1T1* gene (MetaSystems *AML1::ETO (RUNX1::RUNX1T1)* DCDF Translocation Probe).

diagnosis, examination of the patient’s peripheral blood on routine follow-up showed myeloblasts (white blood cell count 9.6×10^9 , and blasts 47%), indicating relapse. Salvage therapy was started; however, the patient contracted Severe Acute Respiratory Syndrome Coronavirus-2 (SARS-CoV-2) infection shortly before his 3rd cycle and the patient did not achieve remission. Bone marrow transplant was contemplated but did not push through due to lack of a compatible donor. The patient expired from intracranial hemorrhage 8 months after initial leukemia diagnosis.

CASE 2

An 18-year-old Filipino male presented with a 2-month history of generalized pallor. The patient had stable vital signs and pale palpebral conjunctiva. Other physical examination findings and past medical history were unremarkable. There was also no history of cancer or other hematolymphoid disease in the family. Complete blood count showed anemia (hemoglobin 85.0 g/L, hematocrit 0.25, and red blood cell count $2.7 \times 10^{12}/L$), thrombocytopenia (platelets $11 \times 10^9/L$), and presence of immature granulocytes and blasts (white blood cell count $6.8 \times 10^9/L$, Differential count: segmenters 10%, lymphocytes 60%, monocytes 2%, stabs 3%, myelocytes 3%, metamyelocytes 2% and blasts 20%). These blasts

exhibited a perinuclear hof and large, pink-colored cytoplasmic granules (Figure 3A). Flow cytometry showed 85% myeloblasts with the following immunophenotype: CD13, CD33, CD34, CD117, anti-HLA-DR, and cMPO (Figure 3B). These findings were consistent with AML.

Karyotype was normal (46,XY) but FISH using MetaSystems Translocation Probe (MetaSystems Asia Co. Ltd.) revealed $t(8;21)(q22;q22.1)$; *RUNX1::RUNX1T1* in 56.31% cells (Figure 4). NGS performed using the AmpliSeqTM for Illumina Myeloid Panel (Illumina, San Diego, CA, USA) run on MiSeq platform confirmed *RUNX1::RUNX1T1*. In addition, mutation of *TET2* (*Tet methylcytosine dioxygenase 2*) N281Gfs*2 was also noted. The patient was optimized by giving blood transfusion and chemotherapy was initiated. Patient was part of a trial on Low-dose chemotherapy (Cytarabine 10 mg/m² and Doxorubicin 25 mg/m²) with Granulocyte Colony Stimulation Factor (G-CSF) AML Protocol.⁹ After 1 cycle, monitoring by flow cytometry showed low level residual (1% blast). Patient was shifted to BFM-87 protocol and then attained remission after induction. After the late intensification phase, patient presented with dry cough, fever and vomiting, and eventually succumbed to septic shock secondary to febrile neutropenia. Table 1 summarizes the clinical data, karyotype, FISH and NGS result of the two cases.

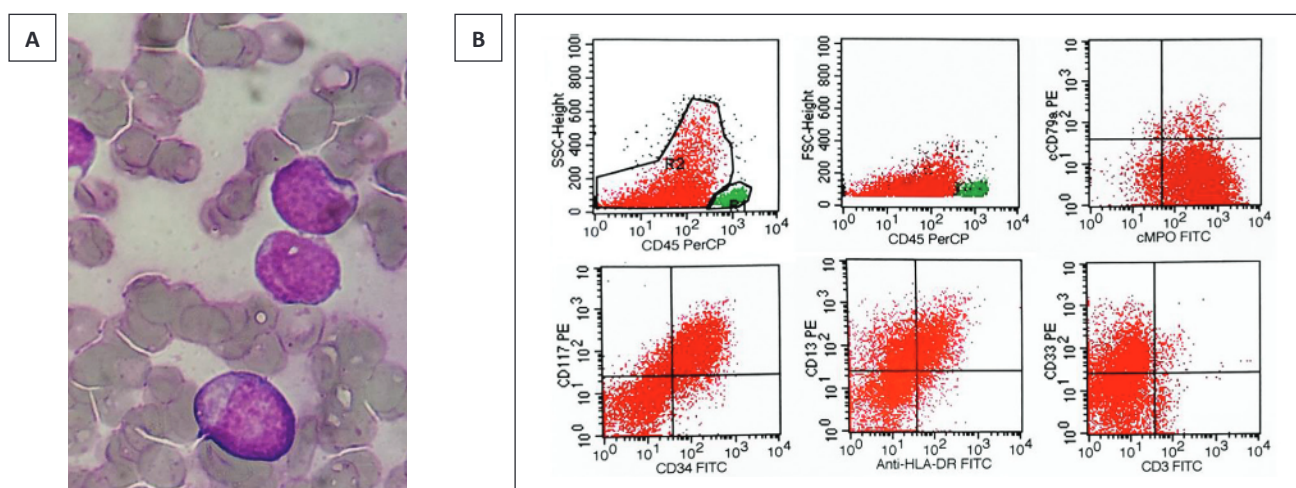


Figure 3. (A) Blasts in the peripheral blood exhibiting perinuclear hof and large, pink-colored granules; **(B)** Flow Cytometry showing 85% myeloblasts with the following immunophenotype: CD13, CD33, CD34, CD117, anti-HLA-DR and cMPO consistent with AML.

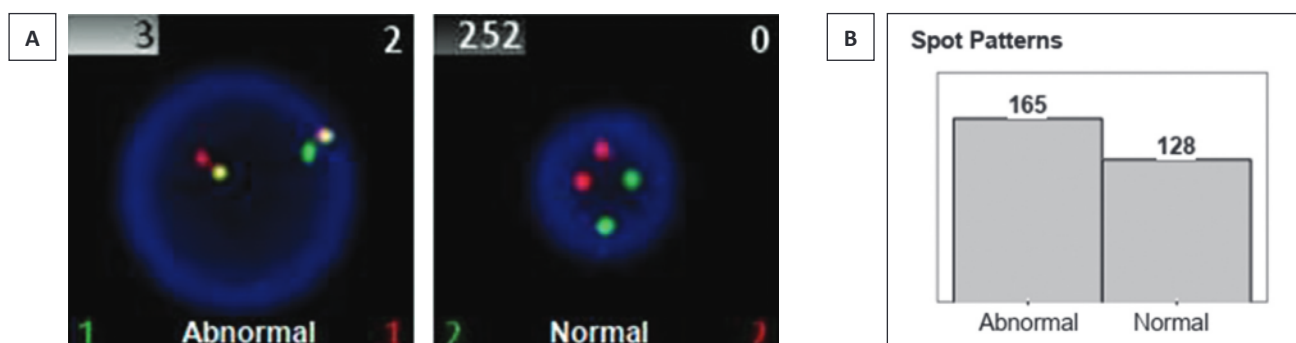


Figure 4. (A) Detection of *RUNX1::RUNX1T1* by Fluorescence in situ Hybridization (FISH). As with the first case, the abnormal cells containing *RUNX1::RUNX1T1* fusion gene show one red, one green and two red/green (yellow) fusion signals. **(B)** Spot patterns showing 165 out of 293 total cells analyzed or 56.31% having *RUNX1::RUNX1T1* gene (MetaSystems *AML1::ETO (RUNX1::RUNX1T1)* DCDF Translocation Probe).

Table 1. Clinical data, karyotype, FISH and NGS result of the two cases		
Clinical and molecular data	Case 1	Case 2
Patient age/sex	12/Male	18/Male
WBC at diagnosis	7.9 x 10 ⁹ /L	6.8 x 10 ⁹ /L
% Blast at diagnosis (flow cytometry)	61%	85%
Immunophenotype (flow cytometry)	CD13, CD33, CD34, CD117, anti-HLA-DR and cMPO	CD13, CD33, CD34, CD117, anti-HLA-DR, and cMPO
Karyotype	46,XYqh+	46,XY
FISH result	<i>RUNX1::RUNX1T1</i> (50.47%)	<i>RUNX1::RUNX1T1</i> (56.31%)
NGS result	<i>RUNX1::RUNX1T1</i> KIT M541L SH2B3 P242S	<i>RUNX1::RUNX1T1</i> TET2 N281Gfs*2
Initial MRD (flow cytometry) after 1 cycle of chemotherapy	Residual AML (10% blasts)	Low-level residual AML (1% blast)
Treatment Protocol	Berlin-Frankfurt-Münster (BFM-87) protocol	Low dose chemotherapy AML protocol BFM-87 protocol
Course	Attained remission after 3 cycles but relapsed and had SARS-CoV-2 infection. Expired from intracranial hemorrhage.	Attained remission after 1 cycle of BFM-87 protocol. Succumbed to sepsis.

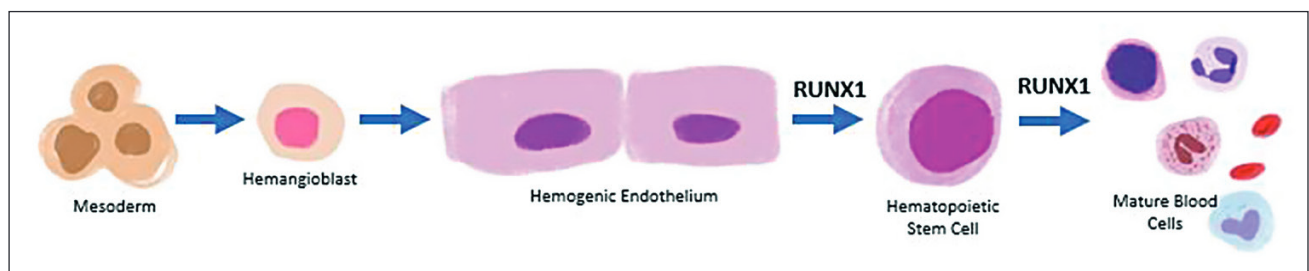


Figure 5. The role of *RUNX1* in the embryonic origin of the blood. The mesoderm cells in the yolk sac transform into hemangioblasts which are the precursor of hemogenic endothelium. *RUNX1* encodes for the transcription factor RUNX1 which was identified as the first specific marker of hemogenic endothelium (HE).¹⁰ HE is now considered as the immediate precursor of hematopoietic stem cells (HSC), and laboratory models show that removal of RUNX1 prevents HE to transform into HSCs.¹¹ In adult hematopoiesis, RUNX1 also plays a role in the differentiation of mature blood cells from hematopoietic stem cells.

DISCUSSION

Both cases included in this case series were found to harbor a core binding factor driver fusion, the *RUNX1::RUNX1T1* fusion gene. *RUNX1* has been identified as the first hemogenic endothelium marker shown to have a critical function in the earliest stages of blood cell formation¹⁰ (Figure 5). In adult hematopoiesis, the protein it encodes, RUNX1 is expressed by hematopoietic cells and forms a complex with core binding factor β (CBFB encoded by *CBFB* gene). This DNA-binding heterodimer regulates hematopoietic differentiation.³ *RUNX1T1* is a translational corepressor expressed in the megakaryocytic and erythrocytic lineages, basophils and eosinophils, and B progenitors.⁷

Similar to wildtype RUNX1, the protein encoded by the resulting *RUNX1::RUNX1T1* fusion gene forms a complex with CBFB, increasing its DNA-binding activity.⁷ This competes with wildtype RUNX1 and plays a role in leukemogenesis by influencing cell proliferation, differentiation and self-renewal capacity¹² (Figure 6). Despite being one of the most common translocation in AML, the study by Tamayo et al., demonstrated that only three (3) out of 20 Filipino pediatric AML cases harbor this fusion gene.⁵

Phenotypically, myeloid blasts in patients with AML with *RUNX1::RUNX1T1* translocation express high positivity with HLA-DR and CD34, and less CD33.¹³ They may

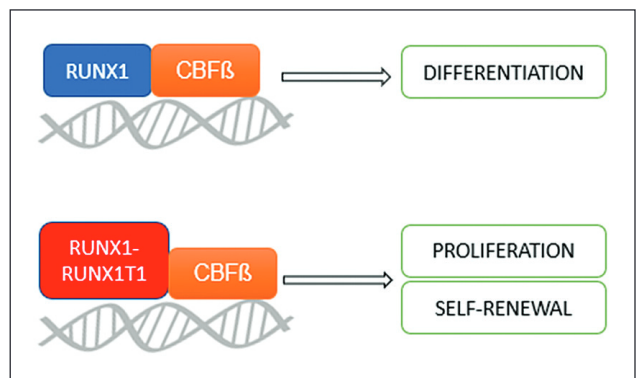


Figure 6. The role of *RUNX1::RUNX1T1* in leukemogenesis. RUNX1 forms a DNA-binding heterodimer with CBFB which promotes hematopoietic differentiation. In the presence of *RUNX1::RUNX1T1* fusion gene, the protein it encodes compete with wildtype RUNX1 and promotes leukemogenic proliferation and self-renewal.

also co-express CD19 or PAX5 and CD56.^{13,14} With both of our cases, flow cytometry showed positivity with HLA-DR, CD34 and CD33 and did not express CD19. PAX5 or CD56 were not included in the performed panel. Morphologically, the blasts in the second case showed the characteristic perinuclear hof and abundant, large cytoplasmic pink- or salmon-colored granules, while non-blastic granulocytes showed Auer Rods.¹³

Clinically, pediatric AML commonly arises *de novo* while adult AML is associated with an underlying myeloproliferative neoplasms (MPN) or myelodysplastic syndrome (MDS).¹⁵ Whereas adult AML has the propensity to harbor somatic sequence variance, pediatric AML exhibits chromosomal rearrangements such as *RUNX1::RUNX1T1* fusion gene.¹⁶ There is evidence that such chromosomal rearrangements may exist in utero, however, these do not all develop into AML.¹⁵ Furthermore, *RUNX1::RUNX1T1* -positive cells may still be detected in patients who have received treatment for AML and has undergone complete remission.¹⁵

In congruence with the favorable prognosis observed in AML with *RUNX1::RUNX1T1* clinically, the two cases described herein achieved complete remission initially. In core-binding factor driven leukemias, 90% of patients achieve complete remission with chemotherapy, and 70% overall survival.¹⁶ Unfortunately, relapse is seen in 30% of cases, with overall survival being reduced to 51%.^{7,12} In the first case, the patient had a relapse after attaining remission with 3 cycles of chemotherapy.

The two patients were given BFM-87 protocol, for which *RUNX1::RUNX1T1* is recognized to have good response.¹⁷ The second patient was part of a trial and was given initially low dose chemotherapy. This regimen is documented to have comparable complete response and overall survival but with less toxicity; and based on 149 AML cases with known molecular alterations, there was no significant difference on the rate of morphologic and molecular remission between the low dose chemotherapy and the standard protocol.⁹ The second patient was shifted to the standard BFM-87 protocol when complete remission was not attained after 1 cycle of low-dose chemotherapy. The patient then had complete remission after induction phase and never went into relapse.

There are few case reports documenting *RUNX1::RUNX1T1* translocation in pediatric AML. Totadri et al., reported a case of a 9-year-old male who had an extramedullary presentation of *RUNX1::RUNX1T1* translocated AML.¹⁸ The patient presented with cranial nerve palsies; however peripheral blood smears showed blasts with Auer rods. Patient underwent AML 15 Medical Research Council protocol and cranial radiotherapy and attained a 1-month disease-free survival at the time of publication of the case report.¹⁸ Additionally, Kondo et al., reported a case of a 7-year-old male with *RUNX1::RUNX1T1* translocated AML who achieved complete remission after conventional chemotherapy but relapsed after six (6) months, like in our first case.¹⁹

RUNX1::RUNX1T1 is also used in MRD monitoring through multiparameter-flow cytometry or molecular techniques. The induction regimen used in chemotherapy is found to be an independent factor influencing the prognostic significance of MRD.²⁰ A repetitive and sensitive detection of MRD negativity has the best prognostic value.⁶ In a study by Hollein et al., 68% of the patients with *RUNX1::RUNX1T1* translocation who underwent allogenic stem cell transplant achieved complete molecular remission (CMR) post transplantation. In patients who relapsed following CMR, transplantation also confers

an increase in overall survival to 69% at 2 years while the median survival of patients who did not undergo transplant is only 5 months.²¹

The *RUNX1::RUNX1T1* fusion gene usually coexists with additional chromosomal mutations such as *KIT*, *NRAS* and *ASXL1* in leukemogenesis.¹² The first case has a *KIT* M541L mutation, the most common chromosomal mutation associated with core binding factor driver fusion genes. The other gene mutated in the first case is *SH2B3* P242S and the protein it encodes is a negative regulator of *JAK2*. This is present in 13% of secondary AML, 1% of essential thrombocythemia, and 3% of primary myelofibrosis.²² Studies on the role of *SH2B3* in primary AML are scarce. The second case harbors a concurrent *TET2* (Ten-Eleven Translocation 2) gene mutation, specifically *TET2* N281Gfs*2, which encodes for a protein critical in promoting DNA demethylation and immune homeostasis.²³ The effect of *TET2* in the prognosis of AML is controversial, but has been recurrently detected in the early events of AML pathogenesis.^{21,22}

While certain somatic mutations such as somatic mutations of *WT1*, *ELF1*, *KMT2C*, and *MLLT10* were associated with primary chemotherapy resistance in pediatric AML, it is unclear if the additional mutations in both cases trumped the prognosis to worse. In the first case, *KIT* mutations have been shown to have no significant effect in the prognosis of pediatric AML, in contrast to the poor prognosis it confers to adult patients.^{13,24} It is also not known if the concurrent *TET2* mutation seen in the second case conferred a worse prognosis as discussed, as the patient died of other cause. Nevertheless, genomic testing for this population of AML patients will pave the way for optimizing prognosis and the development of targeted therapies.

In developing countries, other prognostic factors identified that are associated with decreased overall survival includes WBC at presentation and response to induction therapy.²⁵ Our two cases had a WBC of less than $50 \times 10^9/L$ at presentation, which is associated with a better overall survival. Both cases were in partial remission after induction chemotherapy, which is associated with less favorable prognosis. In the study done in Pakistan, neutropenic sepsis and bleeding are the most common cause of treatment-associated mortality, similar to our two cases.²⁵ These complications may have trumped the favorable prognosis associated with *RUNX1::RUNX1T1* translocation to worse.

The findings of this paper is limited to the two (2) cases discussed and cannot be used to generalize the prognostic factors and treatment of AML with *RUNX1::RUNX1T1* translocation and/or additional mutations. In the Philippines, molecular testing in pediatric AML is not routinely done due to limited resources. Further studies are warranted for correlation of the molecular profile of pediatric AML with prognosis and treatment in our setting.

CONCLUSION

Although the presence of *RUNX1::RUNX1T1* translocation is generally considered to confer favorable prognosis in AML, up to 30% of cases relapse, leading to worse outcome

and decreased overall survival. Additional genetic mutations may coexist with *RUNX1::RUNX1T1* translocation, and the effect of these mutations on the prognosis is an evolving field. This emphasizes the significance of genomic testing in patient management, prognostication and in the development of targeted therapies.

ETHICAL CONSIDERATION

Efforts were made to have the patients' relatives sign the consent form for publication, however there was no reply. Initially, consent for the second case was obtained verbally, however, there was no reply when they were contacted to sign the consent form.

STATEMENT OF AUTHORSHIP

The authors certified fulfillment of ICMJE authorship criteria.

AUTHOR DISCLOSURE

The authors declared no conflict of interest.

FUNDING SOURCE

None.

REFERENCES

- Allen-Rhoades W, Whittle SB, Rainusso N. Pediatric solid tumors in children and adolescents: an overview. *Pediatr Rev.* 2018;39(9):444-53. PMID: 30171055. <https://doi.org/10.1542/pir.2017-0268>.
- McPherson RA, Pincus M. Henry's clinical diagnosis and management by laboratory methods. 23rd ed. Saunders Elsevier; 2016.
- Swerdlow SH. WHO classification of tumours of haematopoietic and lymphoid tissues Revised 4th ed, vol 2. International Agency for Research on Cancer; 2017.
- George TI, Bajel A. Diagnosis of rare subtypes of acute myeloid leukaemia and related neoplasms. *Pathology.* 2021;53(3):312-27. PMID: 33676766. <https://doi.org/10.1016/j.pathol.2021.02.001>.
- Tamayo SCA, Medalla IMC, Roque EMP, et al. Molecular characterization of acute myeloid leukemia among pediatric Filipino patients using karyotype analysis, fluorescence in situ hybridization and comprehensive next generation sequencing: a multi-center experience [abstract]. In: 35th International Symposium on Technical Innovations in Laboratory Hematology; 2022 Sep 8-10; Bologna, Italy: ISLH; 2022. Abstract number 93.
- Höllein A, Nadarajah N, Meggendorfer M, et al. Molecular characterization of AML with *RUNX1-RUNX1T1* at diagnosis and relapse reveals net loss of co-mutations. *Hemasphere.* 2019;3(1):e178. PMID: 31723813. PMID: PMC6745937. <https://doi.org/10.1097/HS9.0000000000000178>.
- Swart LE, Heidenreich O. The *RUNX1/RUNX1T1* network: translating insights into therapeutic options. *Exp Hematol.* 2021;94:1-10. PMID: 33217477. PMID: PMC7854360. <https://doi.org/10.1016/j.exphem.2020.11.005>.
- Rasche M, Zimmermann M, Borschel L, et al. Successes and challenges in the treatment of pediatric acute myeloid leukemia: a retrospective analysis of the AML-BFM trials from 1987 to 2012. *Leukemia.* 2018;32(10):2167-77. PMID: 29550834. PMID: PMC6170392. <https://doi.org/10.1038/s41375-018-0071-7>.
- Hu Y, Chen A, Zheng X, et al. Ecological principle meets cancer treatment: treating children with acute myeloid leukemia with low-dose chemotherapy. *Natl Sci Rev.* 2019;6(3):469-79. PMID: 34691895. PMID: PMC8291445. <https://doi.org/10.1093/nsr/nwz006>.
- Gao L, Tober J, Gao P, Chen C, Tan K, Speck NA. *RUNX1* and the endothelial origin of blood. *Exp Hematol.* 2018;68:2-9. PMID: 30391350. PMID: PMC6494457. <https://doi.org/10.1016/j.exphem.2018.10.009>.
- Daniel MG, Rapp K, Schaniel C, Moore KA. Induction of developmental hematopoiesis mediated by transcription factors and the hematopoietic microenvironment. *Ann N Y Acad Sci.* 2020;1466(1):59-72. PMID: 31621095. PMID: PMC7162702. <https://doi.org/10.1111/nyas.14246>.
- Krauth M-T, Eder C, Alpermann T, et al. High number of additional genetic lesions in acute myeloid leukemia with t(8;21)/*RUNX1-RUNX1T1*: frequency and impact on clinical outcome. *Leukemia.* 2014;28(7):1449-58. PMID: 24402164. <https://doi.org/10.1038/leu.2014.4>.
- Kita K, Nakase K, Miwa H, et al. Phenotypical characteristics of acute myelocytic leukemia associated with the t(8;21)(q22;q22) chromosomal abnormality: frequent expression of immature B-cell antigen CD19 together with stem cell antigen CD34. *Blood.* 1992;80(2):470-7. PMID: 1378322.
- Haferlach T, Meggendorfer M. More than a fusion gene: the *RUNX1-RUNX1T1* AML. *Blood.* 2019;133(10):1006-7. PMID: 30846508. <https://doi.org/10.1182/blood-2019-01-896076>.
- Aung MMK, Mills ML, Bittencourt-Silvestre J, Keeshan K. Insights into the molecular profiles of adult and paediatric acute myeloid leukaemia. *Mol Oncol.* 2021;15(9):2253-72. PMID: 33421304. PMID: PMC8410545. <https://doi.org/10.1002/1878-0261.12899>.
- Krock B, Oberley MJ. Molecular genetics of pediatric acute myeloid leukemia. *Clin Lab Med.* 2021;41(3):497-515. PMID: 34304778. <https://doi.org/10.1016/j.cll.2021.03.014>.
- Reinhardt D, Antoniou E, Waack K. Pediatric acute myeloid leukemia—past, present, and future. *J Clin Med.* 2022;11(3):504. PMID: 35159956. PMID: PMC8837075. <https://doi.org/10.3390/jcm11030504>.
- Totadri S, Bhatia P, Sreedharanunni S. *RUNX1-RUNX1T1*-positive acute myeloid leukaemia presenting as bilateral proptosis and multiple cranial nerve palsy. *BMJ Case Rep.* 2017;2017:bcr2017221402. PMID: 28993357. PMID: PMC5652363. <https://doi.org/10.1136/bcr-2017-221402>.
- Kondo H, Kanayama T, Matsumura U, et al. Relapsed *RUNX1-RUNX1T1*-positive acute myeloid leukemia with pseudo-Chediak-Higashi granules. *Int J Hematol.*

- 2021;113(5):616-7. PMID: 33782817. <https://doi.org/10.1007/s12185-021-03141-7>.
20. Wei H, Liu X, Wang Y, et al. Optimized clinical application of minimal residual disease in acute myeloid leukemia with RUNX1–RUNX1T1. *Exp Hematol*. 2021;96:63-72.e3. PMID: 33524443. <https://doi.org/10.1016/j.exphem.2021.01.007>.
21. Höllein A, Jeromin S, Meggendorfer M, et al. Minimal residual disease (MRD) monitoring and mutational landscape in AML with RUNX1-RUNX1T1: a study on 134 patients. *Leukemia*. 2018;32(10):2270-4. PMID: 29568097. <https://doi.org/10.1038/s41375-018-0086-0>.
22. Higgins A, Shah MV. Genetic and genomic landscape of secondary and therapy-related acute myeloid leukemia. *Genes (Basel)*. 2020;11(7):749. PMID: 32640569. PMCID: PMC7397259. <https://doi.org/10.3390/genes11070749>.
23. Feng Y, Li X, Cassady K, Zou Z, Zhang X. TET2 function in hematopoietic malignancies, immune regulation, and DNA repair. *Front Oncol*. 2019;9:210. PMID: 31001476. PMCID: PMC6454012. <https://doi.org/10.3389/fonc.2019.00210>.
24. Badr P, Elsayed GM, Eldin DN, Riad BY, Hamdy N. Detection of KIT mutations in core binding factor acute myeloid leukemia. *Leuk Res Rep*. 2018;10:20-5. PMID: 30112273. PMCID: PMC6092444. <https://doi.org/10.1016/j.lrr.2018.06.004>.
25. Ghafoor T, Khalil S, Farah T, Ahmed S, Sharif I. Prognostic factors in childhood acute myeloid leukemia; experience from a developing country. *Cancer Rep (Hoboken)*. 2020;3(5):e1259. PMID: 33085844. PMCID: PMC7941425. <https://doi.org/10.1002/cnr2.1259>.

Disclaimer: This journal is **OPEN ACCESS**, providing immediate access to its content on the principle that making research freely available to the public supports a greater global exchange of knowledge. As a requirement for submission to the PJP, all authors have accomplished an **AUTHOR FORM**, which declares that the ICMJE criteria for authorship have been met by each author listed, that the article represents original material, has not been published, accepted for publication in other journals, or concurrently submitted to other journals, and that all funding and conflicts of interest have been declared. Consent forms have been secured for the publication of information about patients or cases; otherwise, authors have declared that all means have been exhausted for securing consent.

*Publish in the new PJP.
Visit our website:
<http://philippinejournalofpathology.org>*