

# Stiff person syndrome: An unusual paraneoplastic neurological phenomenon in Carcinoid tumour

Sahathevan Vithoosan *MBBS*, Tharuka Herath *MBBS*, Dayal S. Gamlaksha *MBBS*, Nilukshana Yogendranathan *MBBS*, Aruna Kulatunga *MD FRCP*, Bimsara Senanayake *MD FRCP*

National Hospital, Colombo, Sri Lanka

## Abstract

Stiff person syndrome is a rare neurologic disorder characterised by rigidity of the truncal and proximal limb muscles with intermittent superimposed spasms. It's unique because it lacks similarity to any other neurologic disorder. Possibly tetanus is the closest related condition with both inhibiting central gamma-aminobutyric (GABA) systems. Stiff person syndrome is extremely rare with less than 20 cases reported from South Asia which has a population of nearly 2 billion. In its classic form, it is associated with the presence of high titres of glutamic acid decarboxylase (GAD) antibodies. Paraneoplastic stiff person syndrome comprising of around 5% of the patients has been reported with malignancies of the breast, colon, lung, thymus and Hodgkin's lymphoma. Antibodies against amphiphysin and gephyrin are detected in paraneoplastic stiff person syndrome. We report a 58 year old Sri Lankan male with stiff person syndrome with a high GAD antibody titre and classical electromyographic changes, who was found to have an underlying carcinoid tumour. We postulate that stiff person syndrome was a paraneoplastic phenomenon secondary to the carcinoid in this case. Although neurological syndromes such as sensory neuropathy, limbic encephalitis and, myelopathy have been described as paraneoplastic features in carcinoid, we believe this is the first report of stiff person syndrome associated with carcinoid tumour.

**Keywords:** Paraneoplastic, stiff person syndrome, carcinoid, anti-GAD antibody

## INTRODUCTION

Stiff person syndrome (SPS) is a rare neurological disorder of unclear aetiology. It is characterized by progressive rigidity and stiffness primarily affecting the truncal muscles and is superimposed by spasms and postural deformities.<sup>1</sup> It frequently affects people in their 40s but can occur between 30-60years.<sup>2</sup> It is unique because it lacks similarity to any other neurologic disorder. SPS is extremely rare with less than 20 cases reported from South Asia which has a population of nearly 2 billion.<sup>3</sup> Muscle rigidity in SPS waxes and wanes with concurrent spasms. The pathophysiology of the disease is autoimmune.<sup>4</sup> The most common pathologic correlate is anti-glutamic acid decarboxylase (GAD) antibodies which is associated with the idiopathic form.<sup>4</sup> The paraneoplastic form which comprises around 5% was reported with malignancies of the breast, colon, lung, and thymus.<sup>1</sup> Only a few reports associate paraneoplastic neurological syndromes with a carcinoid tumour of which the majority

being a serotonin-related myopathy.<sup>5</sup> SPS as paraneoplastic phenomenon secondary to a carcinoid tumour has not been reported previously.

## CASE REPORT

A previously healthy 58 year old Sri Lankan male, presented with progressive difficulty in walking and painful stiffness of the back for 3 months. He also had intermittent painful muscle spasms lasting for 10-15seconds predominantly in the truncal muscles and proximal lower limb muscles. In between the spasms he noted rigidity especially in the axial muscles. Bladder and bowel functions were normal. There were no psychiatric manifestations and his cognition was normal. On examination he had hyperlordosis of the lumbar spine due to the rigid contraction of the thoracolumbar paraspinal muscles. He had increased tone in both lower limbs with brisk knee reflexes and normal ankle reflexes but with normal muscle power. Clonus was absent and plantar responses were flexor. The gait was spastic. The upper limb, cranial nerves and sensory examinations

Address correspondence to: Sahathevan Vithoosan (MB.BS.), National Hospital, Colombo, Sri Lanka. No. 15B1, Campbell Place, Dehiwela, Sri Lanka. Tel: 0094774435759, e-mail: vithoosan@gmail.com

were normal. Even though he was initially able to walk at the onset of the illness, his mobility was greatly reduced subsequently especially due to the stiffness. His distribution of stiffness index was 4 / 6 while the modified Rankin score was 4/6.

Routine hematological and biochemical assays including full blood count, renal and liver function tests, and inflammatory markers and septic screening were normal. The MRI of the brain and the whole spine was normal. The auto immune markers were negative. Electromyography revealed continuous uniform activation of normal motor unit potential especially in para spinal muscles which was in favour of SPS. The nerve conduction study was normal. The GAD antibody titre was 1826.0 IU/ml (Normal < 10). Other causes of rigidity and spasm were excluded. He had elevated thyroid microsomal antibodies of 696 IU/ml (Normal < 35 IU/ml) but with a normal thyroid function test. Contrast CT of the chest, abdomen and pelvis was performed. It revealed multiple ill-defined hypodense nodular lesions in the liver segments IVa, V, VII and VIII which were suggestive of multiple liver secondaries. The whole body MRI scan also revealed multiple liver secondaries without a primary site. In the liver biopsy immune- morphological features were compatible with deposits of a neuro endocrine tumour. Cords and nests of the tumour were positive for chromogranin (Figure 1) and synaptophysin (Figure 2). Colonoscopy did not find any abnormal lesions. Serum 5-HIAA and chromogranin A levels were elevated. In spite of an extensive search, primary site of the carcinoid was not found. Further testing with Indium 111 pentreotide (Octreoscan) or functional PET imaging with 68-Ga Dotatate were not done. He was initially treated with intravenous methyl prednisolone pulse therapy (1 g daily for 3 days) followed by intravenous human immunoglobulin (IV Ig) 0.4 g/kg daily for 5 days. He was also given diazepam 5 mg daily to reduce the spasms. The patient improved markedly with the treatment and was given chemotherapy for the carcinoid tumour.

## DISCUSSION

SPS is a unique diagnosis with a wide range of presentations from mild symptoms to severe disability. Dalakas' criteria which our patient fulfilled is useful in the diagnosis of SPS.<sup>2</sup> Characteristic lumbar hyper lordosis is the clinical diagnostic hallmark.<sup>3</sup> Continuous contraction of agonist and antagonist muscles caused by involuntary motor-unit firing at rest

is the characteristic electrophysiologic sign of the disease which was also demonstrated here. In most patients, activities of daily living are grossly affected due to spasm, rigidity and falls.<sup>6</sup>

The clinical manifestations of SPS have been attributed to dysfunction of inhibitory mechanisms within the central nervous system.<sup>4</sup> Clinical variants of SPS have been reported.<sup>2</sup> All auto-antigens identified in SPS are synaptic proteins involved in inhibitory synaptic transmission. The pre-synaptic auto antigens are GAD and amphiphysin, and the postsynaptic autoantigens are GABA (A) receptor-associated protein and gephyrin.<sup>1</sup> GAD antibodies are usually elevated in autoimmune SPS. Rarely typical SPS patients with positive anti-GAD antibodies go on to develop malignancies.<sup>1</sup> In our patient with possible paraneoplastic SPS secondary to a carcinoid

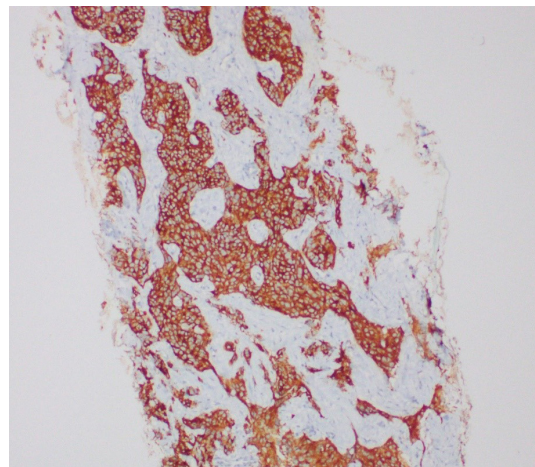


Figure 1. Light Microscopy immuno stain of the liver secondary deposit. Chromogranin X 100

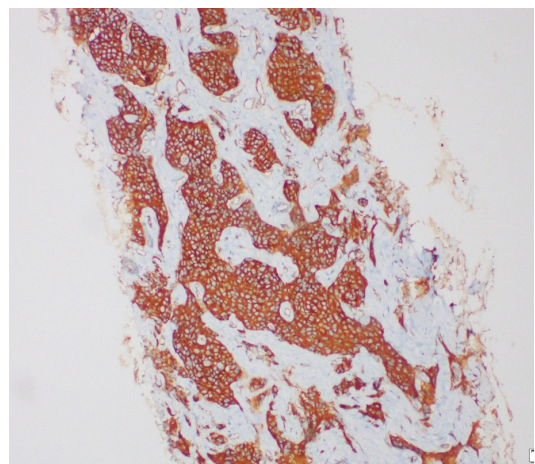


Figure 2. Light Microscopy immunostain of the liver secondary deposit. Synaptophysin X 100

**Table 1: Paraneoplastic Features and associated carcinoid tumours**

Paraneoplastic Neurological Feature	Associated Carcinoid Tumour
Lambert Eaton Myasthenic Syndrome	Atypical carcinoid of the lung
Limbic encephalitis	Bronchial carcinoid
Paraneoplastic cerebellar degeneration	Gastric carcinoid
Intestinal pseudo obstruction	Bronchial carcinoid
Paraneoplastic encephalomyelitis	Atypical carcinoid of the lung
Limbic encephalitis	Bronchial carcinoid
Sensory neuropathy	Bronchial carcinoid
Myelopathy	Bronchial carcinoid

tumour, anti-GAD titers were high. Such high anti-GAD titers occurring rarely in paraneoplastic SPS suggest the possibility of an overlap in the pathogenesis. A paraneoplastic association is found in about 5% of the cases SPS.<sup>1</sup> It is essential to aggressively look for an underlying malignancy in all cases of SPS. Malignancies of the breast, colon, lung, thymus and Hodgkin's lymphoma have been reported in SPS. Auto antibodies against amphiphysin and gephyrin were detected in paraneoplastic SPS.<sup>1</sup> Unfortunately, we did not have the facilities to check for these antibodies associated with paraneoplastic SPS in our patient.

SPS has never been previously reported in association with a carcinoid tumour. Few other paraneoplastic neurologic syndromes such as sensory neuropathy, limbic encephalitis, myelopathy and serotonin related myopathy have been described in association with carcinoid tumours (Table 1).<sup>5</sup> Even though antineuronal antibodies, e.g. anti-Hu, anti-Yo and antinuclear antibodies have been associated with paraneoplastic carcinoids they are not always present.<sup>5</sup> In literature bronchial carcinoid tumors were more commonly associated with paraneoplastic neurologic syndromes.<sup>7</sup>

In our patient, the primary site of the carcinoid tumour was not found. In addition he had multiple liver metastasis. So he was unable to undergo surgical resection and was treated with intravenous octreotide for the carcinoid tumour. Our patient was treated with IV methyl prednisolone pulse therapy followed by intravenous immunoglobulin therapy at the time of diagnosis of SPS. The patient had a dramatic improvement after this treatment, and later subsequent treatment with

intravenous octreotide after the diagnosis of the underlying carcinoid. He became almost completely asymptomatic. This also suggest the possibility of an overlap in the pathogenesis.

In conclusion, this is the first report of SPS as a paraneoplastic neurologic syndrome with underlying carcinoid tumour. There was also high GAD titres, suggesting the importance of search for underlying malignancies despite a high anti-GAD status in SPS.

## DISCLOSURE

Financial support: None

Conflict of interest: None

## REFERENCES

1. Dalakas MC. Stiff person syndrome: Advances in pathogenesis and therapeutic interventions. *Curr Treat Options Neurol* 2009;11(2):102-10.
2. Hadavi S, Noyce AJ, Leslie RD, Giovannoni G. Stiff person syndrome. *Practical Neurol* 2011;272-82.
3. Chang T, Lang B, Vincent A. Stiff person syndrome in South Asia. *BMC Res Notes* 2016;9(1):9-12.
4. Baizabal-Carvallo JF, Jankovic J. Stiff-person syndrome: Insights into a complex autoimmune disorder. *J Neurol Neurosurg Psychiatry* 2015;86(8):840-8.
5. Tschernatsch M, Dierkes C, Gerriets T, et al. Paraneoplastic neurological syndromes in patients with carcinoid. *Eur J Neurol* 2008;15(12):1390-4.
6. Dalakas MC, Fujii M, Li M, Mcelroy B. The clinical spectrum of anti-GAD antibody-positive patients with stiff- person syndrome. *Neurology* 2000;1531-6.
7. Akpınar ÇK, Tilkı HE, Şahin H, Özbenlı T. Carcinoid tumor-associated paraneoplastic polyneuropathy that mimics Guillain – Barre syndrome. *Arch Neuropsychiatry* 2016;53:368-9.