

MR neurography of median nerve using diffusion tensor imaging (DTI) and its efficacy to diagnose carpal tunnel syndrome in Malaysian population

¹Vikneswary Paniandi *MBBchBAO*, ^{1,2}John George *FRCR(UK)DMRD(Aberdeen)*, ³Khean Jin Goh *FRCP(Glasgow) MRCP (UK)*, ¹Li Kuo Tan *MEng(Biomedical Monash)*

¹Biomedical Imaging Department, ²University of Malaya Research Imaging Centre, ³Department of Medicine, Faculty of Medicine, University of Malaya, Kuala Lumpur, Malaysia.

Abstract

Objective: This study evaluates the feasibility of diffusion tensor imaging (DTI) in assessing median nerve by measuring diffusion parameters such as fractional anisotropy (FA), mean diffusivity (MD), axial diffusivity (AD) and radial diffusivity (RD) at different sites of median nerve and evaluating their differences in patients with and without carpal tunnel syndrome (CTS) in local setting. **Methods:** A prospective cross sectional study was performed with 9 female patients diagnosed with CTS by clinical evaluation and nerve conduction study and 8 age and sex matched normal patients. Magnetic resonance imaging (MRI) wrist was performed with pre-set axial PD and DTI protocol on a 3T MRI, images post-processed using 3D SLICER software to generate median nerve tract and measure diffusion parameters FA, MD, AD and RD in segments and focal points. **Results:** The FA values were significantly lower in CTS patients, $0.454 (\pm 0.065)$, $p < 0.002$ and demonstrates negative correlation with disease severity, $r = -0.510$, $p = 0.002$. The mean MD, $1.090 (\pm 0.178)$ and mean RD, $0.834 (\pm 0.128)$ is higher in CTS patients, $p = 0.041$ and $p = 0.014$ respectively. They show an increasing trend with increasing disease severity. Negative correlation was noted between the FA values and age groups. FA cut of value of ≤ 0.487 with sensitivity 70.6 % and specificity 76.5%, is suggested for diagnosing CTS.

Conclusion: MR neurography using DTI can be utilised to detect CTS. Patients with CTS demonstrate lower FA and higher MD and RD values.

Keywords: Median nerve, carpal tunnel syndrome, MRI, diffusion

INTRODUCTION

The median nerve arises from the brachial plexus (C6–T1) and at the wrist, it passes under the flexor retinaculum through the carpal tunnel and divides into digital and muscular branches distally.¹ Compression neuropathy of the median nerve at the carpal tunnel, results in decreased function of the nerve at this level giving rise to a constellation of symptoms and signs called carpal tunnel syndrome (CTS).²

CTS is not restricted by age, gender, ethnicity or occupation. It occurs in 4% of the general population^{3,4}, and approximately 7.5 to 22.5% of the Malaysian population.^{5,6} Left untreated, it can progress to muscle dysfunction, atrophy of the thenar muscles and irreversible damage to the nerve.⁷ However, no gold standard is currently available to accurately diagnose carpal tunnel

syndrome.⁸ A combination of positive symptoms, clinical tests and electrodiagnostic tests are used as a mean of diagnosis.⁸

MRI is not routinely used in the diagnosis of CTS as its sensitivity and specificity is low. Subjective signs such as nerve enlargement, nerve flattening, and increased nerve signal intensity are used for diagnosis.³ Currently, a new subtype of diffusion weighted imaging in MRI which measure the molecular diffusion of water along different directions in space, called diffusion tensor imaging (DTI), is being used to study anisotropic tissues which contain fibers that restrict the diffusion of water molecules along certain directions, such as white matter tracts in the central nervous system⁹ and peripheral nerves such as sciatic, lumbar and median nerve.^{1,10}

DTI enables measurements of quantifiable values such as fractional anisotropy (FA), mean

Address correspondence to: Dr. Vikneswary Paniandi, Biomedical Imaging Department, University Malaya Medical Centre, Lembah Pantai, 59100 Kuala Lumpur, Malaysia. Tel: +6017-4390776, e-mail: viki_187@yahoo.co.uk

diffusivity (MD), axial diffusivity (AD) and radial diffusivity (RD) to measure the integrity of the median nerve. Some studies show significant differences in the FA and MD of carpal tunnel patients from the normal population.^{11,12} Some studies also correlate DTI findings with nerve conduction studies to predict the nature of nerve damage that may have occurred.¹³ However, no standard values have been established to diagnose CTS and its severity in a quantifiable manner in the Malaysian population. The feasibility of diagnosing CTS through DTI has not been explored in our local setting.

METHODS

Subjects

A cross sectional study was carried out from May 2015 to December 2016 and approved by the Medical Ethics Committee, University Malaya Medical Centre (UMMC), Kuala Lumpur in (MREC ID NO: 201541243). Only female Malaysian patients, of age 40-70 years were recruited. All subjects with contraindication to MRI, history of wrist injury/surgery, or relevant systemic neuromuscular / musculoskeletal disorders were excluded. Nine patients with clinical symptoms of carpal tunnel and positive nerve conduction study were recruited and divided into 3 age groups, 41-50, 51-60 and 61-70 years old, mean age 56.3 years.

The CTS patients were graded into 3 groups of severity based on nerve conduction values [Mild: abnormal median sensory nerve conduction velocity (median versus ulnar palm to wrist nerve conduction velocity difference > 10 m/sec) with normal median distal motor latency; Moderate: abnormal median sensory nerve conduction velocity and prolonged median distal motor latency (more than 4.5 msec); Severe: absent median sensory responses.¹⁴]. Eight corresponding age matched subjects were then recruited as controls.

Bilateral hands were imaged in all subjects and each hand was recorded as a separate sample. All the CTS patients except one had bilateral hand involvement. The normal hand was included as a sample in the control group making a total of 17 CTS and control hands respectively.

Imaging

All MRI scans were performed on a clinical 3.0 Tesla MRI Systems (Signa® HDx GE Healthcare, Milwaukee, Wisconsin, USA). A dedicated cardiac

coil was used with subjects positioned prone and arms extended above the head ('superman' position). The imaging protocol included axial proton density weighted fast spoiled gradient echo (AX PD FSE) with parameters of TR = 2000ms, TE = minimum (< 30)ms, FOV = 14mm, matrix = 64 x 64, thickness = 3.0mm, number signals averaged = 2, and scan time of 4mins, 30s. The DTI pulse sequence was done in axial plane with acquisition parameters of TR = 7650ms, TE = <30ms, FOV = 14mm, matrix = 64 x 64 and thickness = 4.0 mm, number of slices = 35, slice gap = 0, number signals averaged = 1, 32 directions and diffusion-weighted factor, $b = 1000 \text{ s/mm}^2$ with scan time of 4mins 20s covering the wrist from proximal to carpal tunnel (distal radioulnar joint) to distal to carpal tunnel (mid metacarpal).

Post processing

The acquired images were converted from DICOM (Digital Imaging and Communications in Medicine) format to NRRD (nearly raw raster data) format. 3D SLICER software version 4.5.0-1 was then used for nerve tracking and DTI measurements. The axial PD images were overlaid on the DTI axial images, the median nerve was identified on the axial PD slices and fiducial points were placed at 4 different locations using carpal bones as specific anatomical landmarks: a) at the region of lunate bone, b) pisiform and scaphoid tubercle, c) hook of hamate and d) distal to hook of hamate to denote points proximal, entrance of carpal tunnel, exit point of carpal tunnel and distal to carpal tunnel respectively (Figure 1). The slicer application then generated the median nerve tract using the fiducial locations as seed points (Figure 2).

The parameters for fibre tractography were set as following: Minimum path length : 10.0mm, Maximum path length : 800.0mm, Stopping FA value: 0.20, Stopping track curvature: 0.5, Integrating step length: 0.5mm, Fiducial seed spacing: 2.0mm, Fiducial size: 2.5mm, Linear measure start threshold: 0.25

The fibre tract is then divided into 3 segments: proximal (most proximal slice of the nerve tract until the level of lunate bone), within (level of pisiform and scaphoid tubercle until the hook of hamate) and distal (above the hook of hamate until the most distal slice of nerve tract) to carpal tunnel. The mean FA, MD, AD and RD were then measured within the individual segments (Figure 3).

These segments were then reduced to leave 4 focal points (single slices) at the regions of lunate bone, pisiform and scaphoid tubercle,

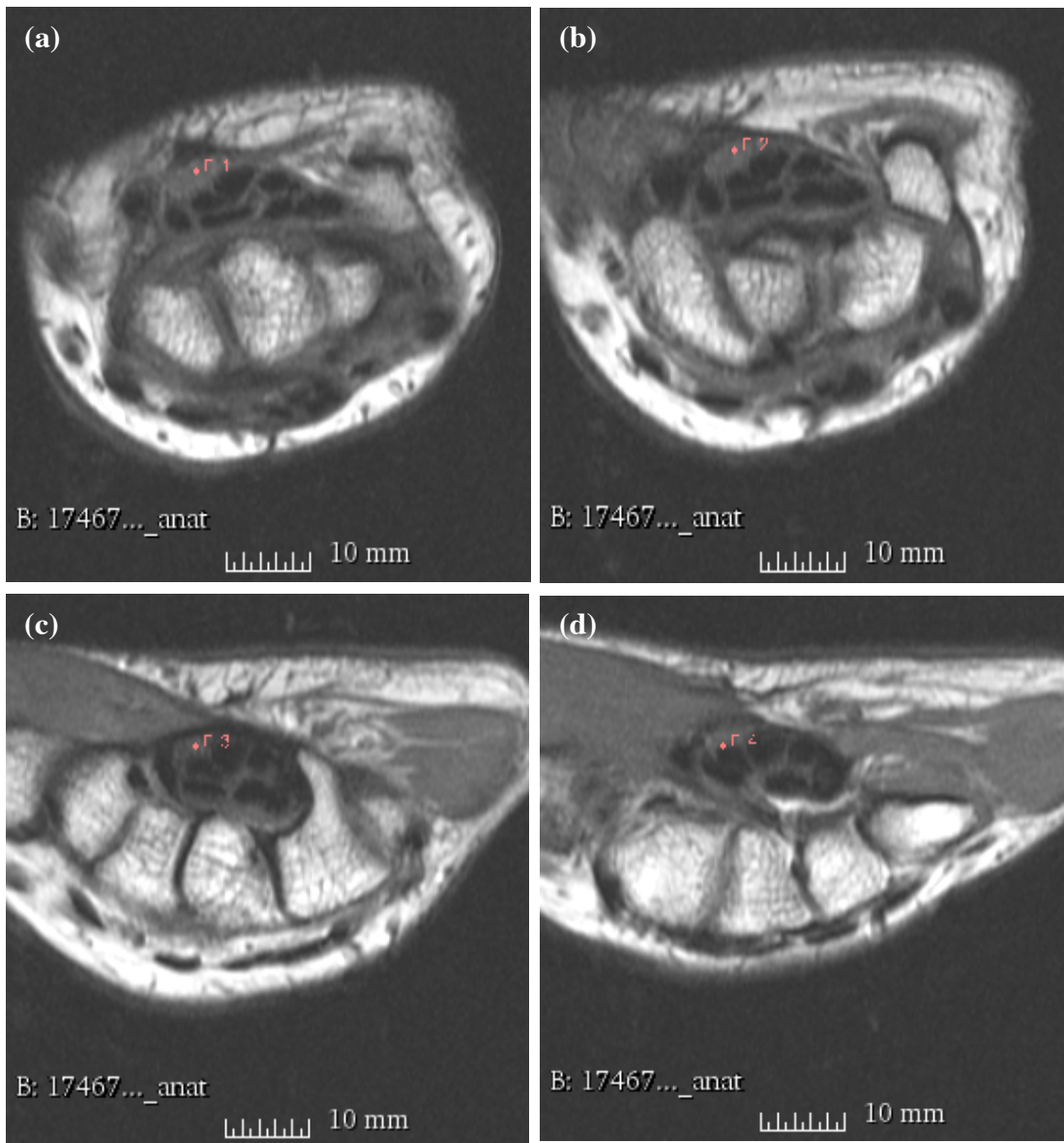


Figure 1. Fiducial points placed on the median nerve on axial PD slices overlaid on the axial DTI slices. The fiducial points are placed at the region of lunate bone (a), pisiform and scaphoid tubercle (b), hook of hamate (c), and distal to hook of hamate (d) to denote points proximal, entrance of carpal tunnel, exit point of carpal tunnel and distal to carpal tunnel.

hook of hamate and distal to hook of hamate on the generated nerve tract (Figure 4). Focal measurements of the mean FA, MD, AD and RD values were measured.

Statistical analysis was performed using IBM SPSS (Statistical Package for the Social Sciences) version 22.0. In view of small sample size non-parametric statistical tests were utilized.

Group comparisons for DTI parameter in CTS versus control were done using non parametric

independent sample Mann Whitney-U test, and group comparisons for DTI parameter and CTS severity (including control) were done using independent sample Kruskal-Wallis test. Spearman's Rho correlation coefficient was utilized for assessment of correlations between 2 continuous data (DTI parameter and disease severity or age group).

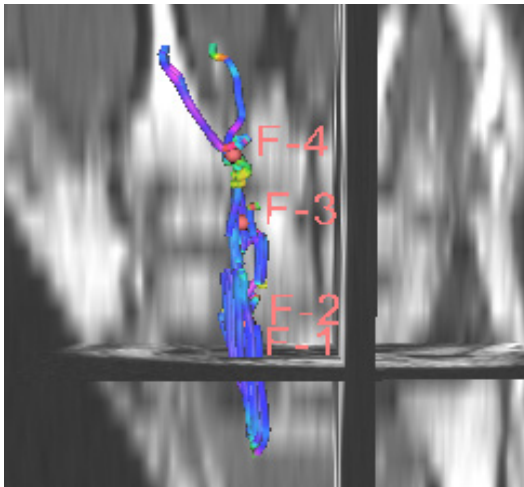


Figure 2. Median nerve tract generated by 3D slicer application

RESULTS

Measurements with FA

Among all DTI measurements, the FA measurements demonstrated the most significant differences between carpal and non-carpal tunnel subjects. FA values were generally lower

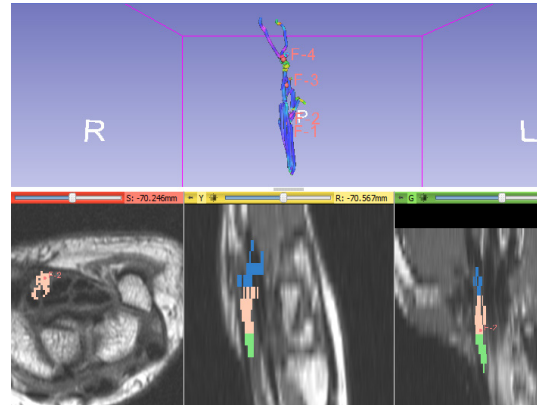


Figure 3. Division of nerve tract into segments proximal, within and distal to carpal tunnel.

in CTS using both segmental and focal point measurements. The segmental measurements demonstrated stronger statistical significance compared to focal points, with all segmental values being significantly lower in CTS patients. Among the three different segments, the segment within tunnel demonstrates the lowest median FA value of 0.450 (\pm 0.068), $p = 0.009$ in CTS

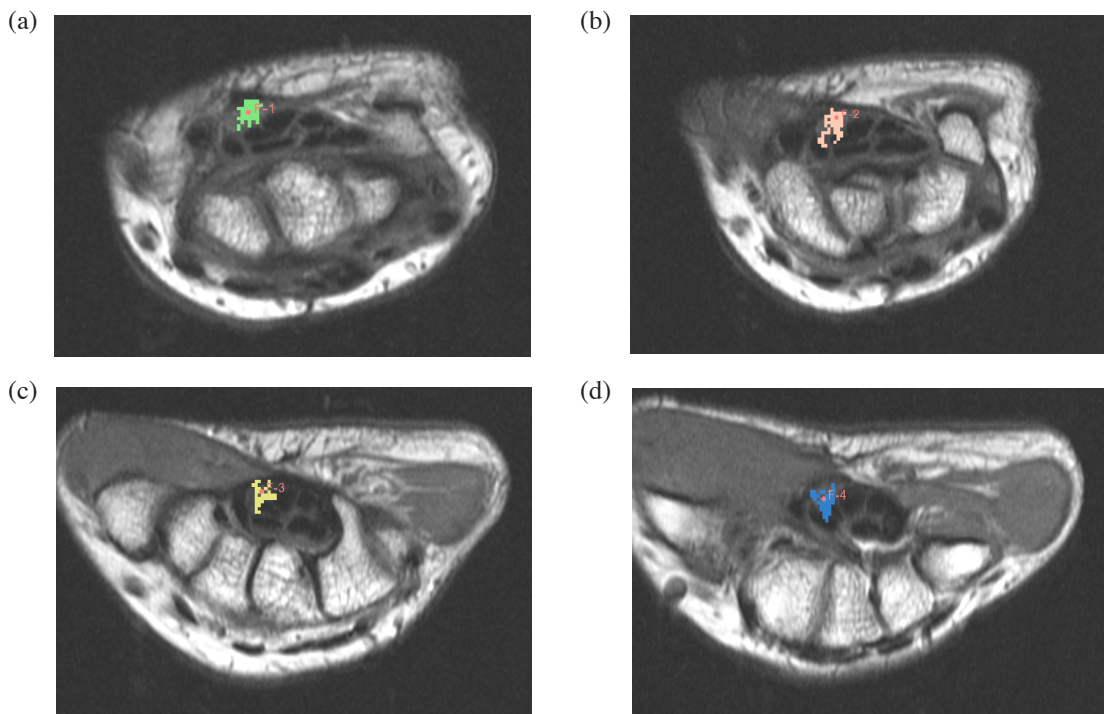


Figure 4. Focal points at region of (a) lunate bone, (b) pisiform and scaphoid tubercle, (c) hook of hamate and (d) distal to hook of hamate on the generated nerve tract to represent the region of proximal to carpal tunnel, entrance of carpal tunnel, exit point of carpal tunnel and distal to carpal tunnel.

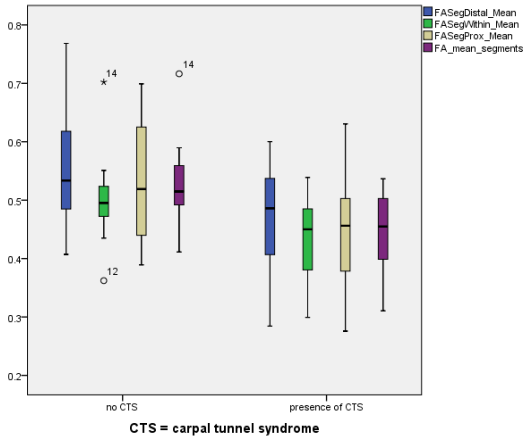


Figure 5. Boxplot of mean FA of all segments in carpal and non-CTS patients.

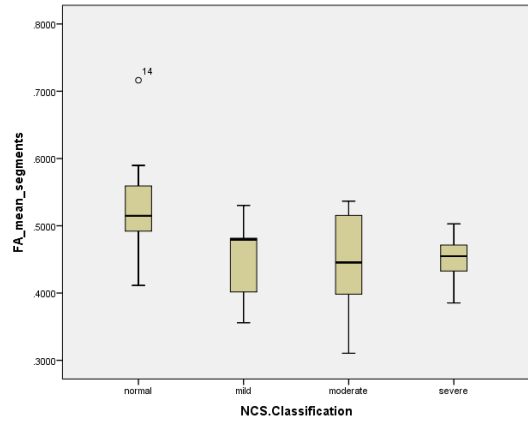


Figure 6. Boxplot of FA values at different segments and different severity of CTS

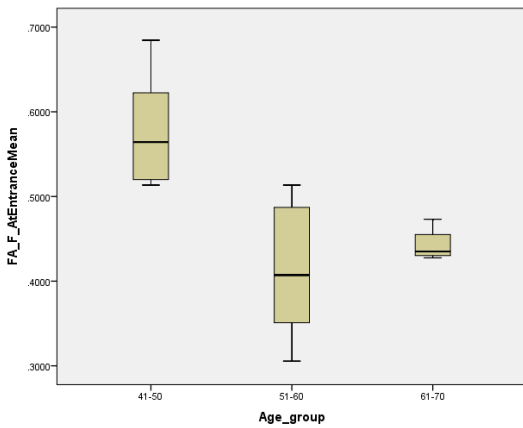


Figure 7. Box plot showing correlation between FA of focal point at tunnel entrance and age group.

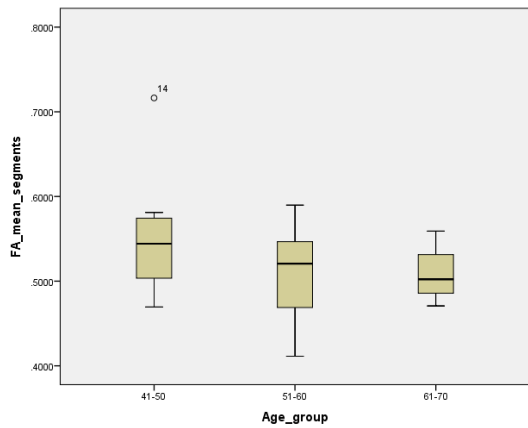


Figure 8. Box plot demonstrating correlation between FA mean of segments and age group.

patients. However the mean of all segments demonstrates the strongest significant difference $p=0.002$, with median FA of $0.454 (\pm 0.065)$ in CTS patients. Comparing with disease severity, the mean of all segments shows the strongest negative correlation, $r = -0.510$, $p = 0.002$ and intergroup difference, $p=0.026$.

Utilizing focal points, mixed pattern noted, only the point above hook of hamate demonstrated statistical significance, $p = 0.041$ showing lower FA in subjects with CTS. No significant correlation were noted with disease severity.

Measurements with MD, RD and AD

The segmental MD and RD values were noted to be higher in CTS than control group. Mean of segment value demonstrated strongest statistical significance in both MD and RD. Correlating

with disease severity classification, MD shows a weak positive correlation, $r = 0.318$, $p=0.07$ but RD demonstrated good positive correlation, $r = 0.412$, $p = 0.026$. Both the segmental and focal point AD values, as well as focal point values of MD and RD showed mixed pattern in comparing the CTS and non CTS group and none of the measurements reached statistical significance.

FA and age group

Control subjects were divided into three age groups, 41-50, 51-60 and 61-70 years and their DTI parameters compared. There is a generally negative relationship between the FA values and age groups in all the measured segments and points. The FA value of focal point at entrance showed the strongest statistical significance, $r = -0.745$, $p = 0.001$. The mean FA of segments however

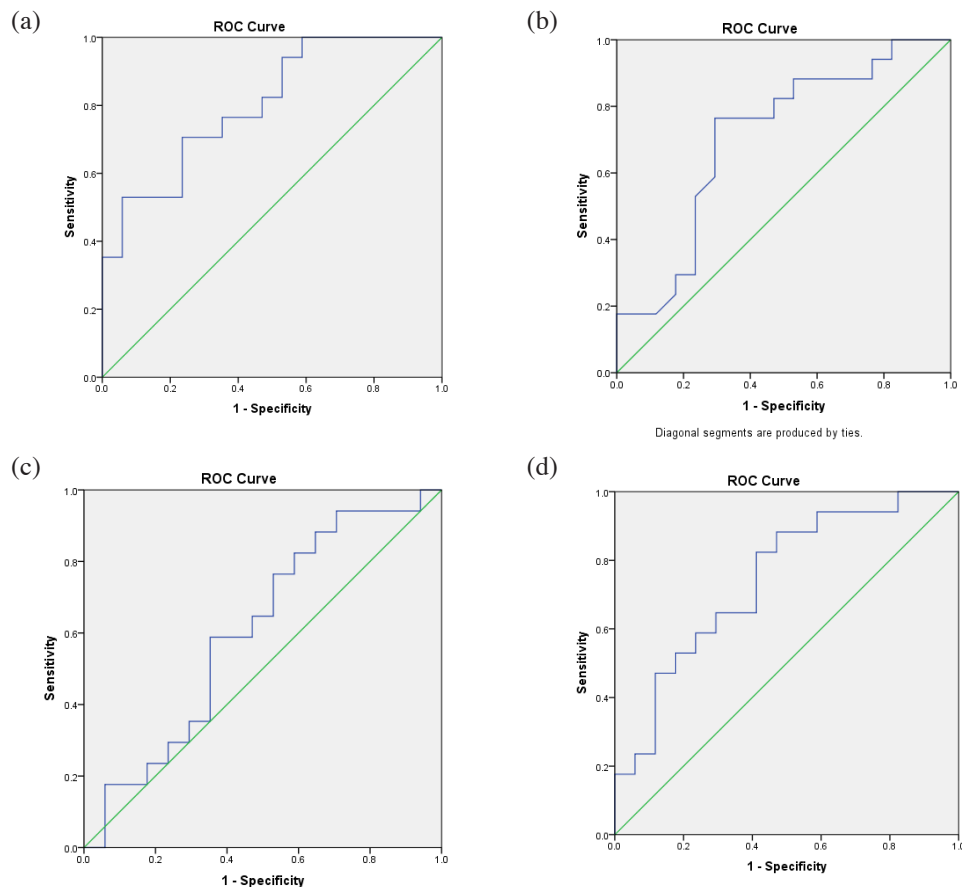


Figure 9. ROC curve for Mean of all segments a) Mean of FA segments, b) mean of MD segments, c) mean of AD segments, d) mean of RD segments

did not demonstrate significant correlation with age. The MD, AD and RD measurements did not demonstrate statistical significance.

ROC curve analysis

Mean of segments were noted to demonstrate the most consistent results and were utilized for ROC curve analysis. FA measurement was the best predictor with AUC : 803 (95% CI, 0.658 – 0.948), and a cut of value of ≤ 0.487 with sensitivity 70.6 % and specificity 76.5% . Mean segments of RD and MD were less useful with AUC of 0.744 and 0.706 respectively. AD demonstrated poor accuracy with AUC of 0.606. The ROC curve values are summarized in the table below.

DISCUSSION

DTI parameters measure diffusivity of water molecules along the nerve fiber. It has been established from white matter DTI studies that these parameters could reflect structural

characteristics of nerve fibers, for example nerve demyelination, axonal damage and nerve integrity.¹⁵

High FA indicates good nerve integrity, while high MD/ ADC reflects presence of axonal damage and nerve demyelination. In order to hypothesize on the type of nerve damage that may be occurring, AD and RD values are measured whereby AD which measures parallel diffusivity reflects axonal integrity while RD which measures perpendicular diffusivity reflects integrity of the myelin.^{16,17}

Most studies of median nerve DTI have generated median nerve tractography and made measurements of the DTI parameters by measuring the value at a particular reference ROI in the generated tract or calculating whole tract values using specific software.

We have proposed, to the best of our knowledge, a novel method of measuring FA value for median nerve by segmenting the nerve into proximal, within tunnel and distal to tunnel, to assess the location of maximal nerve damage instead of at

Table 1: FA values segments distal, within and proximal to carpal tunnel as well as mean of all segments with significance testing in groups with and without carpal tunnel, correlation to classification of disease severity and intergroup of disease severity significance testing

FA SM	Median FA In CTS	Median FA Without CTS	MW-U test sig	KW test, p	Sp CC, r	Sp Sig, p
DS	0.486 (\pm 0.099)	0.533 (\pm 0.099)	p = 0.041	p = 0.240	r = -0.329	p = 0.057
WT	0.450 (\pm 0.068)	0.495 (\pm 0.069)	p = 0.009	p = 0.052	r = -0.365	p = 0.034
PT	0.456 (\pm 0.093)	0.519 (\pm 0.105)	p = 0.034	p = 0.148	r = -0.402	p = 0.019
MS	0.454 (\pm 0.065)	0.515 (\pm 0.067)	p = 0.002	p = 0.026	r = -0.510	p = 0.002

FA SM, FA values of segments measured; MW – U test sig, Mann Whitney-U test significance; KW test, Kruskal-Wallis test; Sp CC - Spearmans rank correlation coefficient; Sp Sig - Spearmans rank significance; DS, distal segment; WT, within tunnel; PT, proximal to tunnel; MS, mean of all segments

focal point. Specific bony landmarks as described in methodology had been used for this purpose. It was noted from our study that this segmental measurements were more reliable in identifying CTS than focal point measurements.

The median FA values of the segments in our study were significantly lower in CTS patients and show negative correlation with severity of disease in all the segments. This corroborates with other studies such as Barcelo *et al.*¹⁸, Brienza *et al.*¹¹, Tasdelen *et al.*¹⁹, and Guggenberger *et al.*¹⁰

Among the three segments, segment within the tunnel demonstrated the strongest significant decrease in FA in CTS. This signifies that the median nerve becomes more isotropic in CTS, maximally at the region within the tunnel. It is hypothesized that in CTS the maximal compression occurs at the level of carpal tunnel causing intraneural microcirculation disruption, which results in nerve edema, increasing extracellular fluid. This increases isotropic water diffusivity at this region and therefore correlates

with a decrease in FA with increasing severity of disease.²⁰ This somewhat corroborates with the studies of Naraghi *et al.*²¹, Ohana *et al.*²² and Kwon *et al.*²³ which demonstrate focal point at pisiform level to be the most sensitive compared to other locations.

However, the mean of all segments shows the most consistent significant difference in CTS. It also demonstrated significant difference between different groups of severities of CTS disease (Kruskal Wallis test, p < 0.026) which is not demonstrated with measurements from segment within tunnel. Therefore our study demonstrates whole nerve measurements to be more reliable than any particular segment. This is noted by Tasdelen *et al.*¹⁹ in his study where his whole nerve measurements showed significant difference between groups of disease severity than focal points.

The increase in extracellular fluid at the region affected by compression neuropathy also causes an increase in MD values as is seen in the studies

Table 2: DTI values of MD, AD and RD using mean of all segments with significance testing in groups with and without carpal tunnel, correlation to classification of disease severity and intergroup of disease severity significance testing

DTI of MS	Median In CTS	Median FA Without CTS	MW-U test sig	KW test, p	Sp CC, r	Sp Sig, p
MD	1.090 (\pm 0.178)	0.957 (\pm 0.266)	p = 0.041	p = 0.223	r = 0.318	p = 0.07
RD	0.834 (\pm 0.128)	0.741 (\pm 0.151)	p = 0.014	p = 0.075	r = 0.412	p = 0.026
AD	1.701 (\pm 0.165)	1.645 (\pm 0.245)	p = 0.306	p = 0.712	r = -0.147	p = 0.407

MS, mean of segments; CTS, carpal tunnel syndrome; FA values of segments measured; MW – U test sig, Mann Whitney-U test significance; KW test, Kruskal-Wallis test; Sp CC - Spearmans rank correlation coefficient; Sp Sig - Spearmans rank significance; MD, mean diffusivity; RD, radial diffusivity; AD, axial diffusivity

Table 3: Cut off value of ROC curves of DTI values using mean of segments

DTI parameter	Cut off value	AUC	(95% CI)	Sensitivity	Specificity
FA	≤ 0.487	0.803	0.658 – 0.948	0.706	0.765
MD	≥ 1.012	0.706	0.526 – 0.886	0.765	0.706
AD	≥ 1.650	0.606	0.411 – 0.800	0.647	0.53
RD	≥ 0.812	0.744	0.577 – 0.910	0.647	0.706

AUC, area under the curve; CI, confidence interval; FA values of segments measured; MD, mean diffusivity; AD, axial diffusivity; RD, radial diffusivity

by Brienza *et al.*¹¹ and Stein *et al.*¹² with lower FA and increase in ADC in CTS patients. Barcelo *et al.*¹⁸ and Khalil *et al.*²⁴ however obtained lower FA with non-significant ADC values. This suggests that in CTS, changes in FA probably occurs first before changes in ADC, therefore making FA a more sensitive parameter to evaluate for CTS.

We had also obtained higher RD values in all the measured segments, with mean RD of segments showing most significant results. High RD is believed to be caused by loss of myelin sheath integrity in CNS nerves. This corroborates with the pathology in CTS where nerve compression is believed to cause myelin sheath damage in the initial phases before progressing to axonal damage. This is noted in studies by Stein *et al.*¹² and Kwon *et al.*²³

ROC curve analysis demonstrated highest area under the curve for FA followed by RD. This suggests FA to be the best parameter to be used as a cut-off value as suggested by Kwon *et al.*²³ A cut-off value of 0.487 is proposed by our study which shows a sensitivity of 70.6% and specificity of 76.5%. This is lower than the cutoff value proposed by Tasdelen *et al.*¹⁹ where the cut off value suggested is 0.660 with AUC of 0.884, sensitivity of 82.5% and specificity of 80%. However it is somewhat similar to the value proposed by Guggenberger *et al.*¹⁰, where FA value of 0.47 was proposed (AUC : 0.773, sensitivity 83% and specificity 67%).

Evaluation of DTI parameters and age groups did not yield convincing results. The mean of segments which demonstrated relatively consistent significant difference between CTS and non CTS groups, did not demonstrate a significant correlation with age. However, the boxplot suggests a generally reducing trend of FA with increasing age group as noted in the studies of Guggenberger *et al.*¹⁰ and Kabakci *et al.*¹ Evaluation of DTI parameters and nerve

conduction parameters also did not show any significant correlation in our study.

The small sample size limits accuracy and reliability of our data. In addition, a cardiac coil was utilized for scanning due to the unavailability of a wrist coil at the time of study. This may have lead to poor image quality, and might affect the reliability of defining the nerve - requiring an axial PD image to be overlaid on DTI image to identify the nerve - a small degree of mismatch may exist in this process. In addition, post processing in nerve tractography is an observer dependent process, and assessment of inter-observer difference was not evaluated in this study.

In conclusion, this study demonstrates that DTI is able to assess the median nerve and its parameters such as FA, MD, AD and RD values at different locations. It also establishes the mean whole nerve value as a more reliable method of measurement, and there is a significant reduction of FA and increase in MD and RD in patients with carpal tunnel syndrome. An FA cut off value of <0.487 is proposed as a rough guide to diagnose carpal tunnel syndrome. However, no significant correlation was established with nerve conduction values.

ACKNOWLEDGEMENT

The authors would like to thank the staff of neurology lab and department of biomedical imaging of UMMC for their help in the electrophysiological assessment of the patients and obligating us in conducting this novel MRI protocol for median nerve DTI.

DISCLOSURE

Financial support: This study was funded by University Malaya postgraduate research grant, grant number: PO 057-2015A and approved by Medical Research Ethics Committee, University

Malaya Medical Center, MREC ID NO: 20154-1243.

Conflict of interest: None

REFERENCES

1. Kabakci N, Gürses B, Firat Z, *et al.* Diffusion tensor imaging and tractography of median nerve: normative diffusion values. *AJR Am J Roentgenol* 2007;189(4):923-7.
2. Fisher B, Gorsche R, Leake P. Diagnosis, causation and treatment of carpal tunnel syndrome: An evidence-based assessment. A background paper prepared for Medical Services Workers' Compensation Board. WCB Alberta May 2004.
3. Andreisek G CD, Burg D, Marineek B, Weishaupt D. Peripheral neuropathies of the median, radial and ulnar nerves: MR imaging features. *Radiographics* 2006;26:1267-87
4. Atroshi I, Gummesson C, Johnsson R, Ornstein E, Ranstam J, Rosén I. Prevalence of carpal tunnel syndrome in a general population. *JAMA* 1999;282(2):153-8.
5. Ithnin A, Dinnee K, Venkataraman S. Occupational risk factors for carpal tunnel syndrome among nurses in medical. *Int J Public Health Res* 2012;2(2):137-43.
6. Munirah M, Normastura A, Azizah Y, Aziah D. Prevalence of probable carpal tunnel syndrome and its associated factors among dentists in Kelantan. *International Journal of Collaborative Research on Internal Medicine & Public Health* 2014;6(8):247-59.
7. Cantatore F, Dell'Accio F, Lapadula G. Carpal tunnel syndrome: a review. *Clin Rheumatol* 1997;16(6):596-603.
8. Surgeons AAoO. Clinical practice guideline on the diagnosis of carpal tunnel syndrome. In: AAOS, editor. 2007.
9. Stieltjes B, Kaufmann WE, van Zijl PC, *et al.* Diffusion tensor imaging and axonal tracking in the human brainstem. *NeuroImage* 2001;14(3):723-35.
10. Guggenberger R, Markovic D, Eppenberger P, *et al.* Assessment of median nerve with MR neurography by using diffusion-tensor imaging: normative and pathologic diffusion values. *Radiology* 2012;265(1):194-203.
11. Brienza M, Pujia F, Colaiacomo MC, *et al.* 3T diffusion tensor imaging and electroneurography of peripheral nerve: a morphofunctional analysis in carpal tunnel syndrome. *J Neuroradiology* 2014;41(2):124-30.
12. Stein D, Neufeld A, Pasternak O, *et al.* Diffusion tensor imaging of the median nerve in healthy and carpal tunnel syndrome subjects. *J Magn Reson Imaging* 2009;29(3):657-62.
13. Heckel A, Weiler M, Xia A, *et al.* Peripheral nerve diffusion tensor imaging: Assessment of axon and myelin sheath integrity. *PloS one* 2015;10(6):e0130833.
14. Stevens JC. AAEM minimonograph# 26: the electrodiagnosis of carpal tunnel syndrome. *Muscle Nerve* 1997;20(12):1477-86.
15. Lindberg PG, Feydy A, Le Viet D, Maier MA, Drape JL. Diffusion tensor imaging of the median nerve in recurrent carpal tunnel syndrome - initial experience. *Eur Radiol* 2013;23(11):3115-23.
16. Budde MD, Kim JH, Liang HF, *et al.* Toward accurate diagnosis of white matter pathology using diffusion tensor imaging. *Mag Reson Med* 2007;57(4):688-95.
17. Song SK, Sun SW, Ramsbottom MJ, Chang C, Russell J, Cross AH. Demyelination revealed through MRI as increased radial (but unchanged axial) diffusion of water. *NeuroImage* 2002;17(3):1429-36.
18. Barcelo C, Faruch M, Lapègue F, Bayol MA, Sans N. 3-T MRI with diffusion tensor imaging and tractography of the median nerve. *Eur Radiol* 2013;23(11):3124-30.
19. Tasdelen N, Gurses B, Kilickesmez O, *et al.* Diffusion tensor imaging in carpal tunnel syndrome. *Diagn Interv Radiol* 2012;18(1):60-6.
20. Aboonq MS. Pathophysiology of carpal tunnel syndrome. *Neurosciences* 2015;20(1):4.
21. Naraghi A, da Gama Lobo L, Menezes R, *et al.* Diffusion tensor imaging of the median nerve before and after carpal tunnel release in patients with carpal tunnel syndrome: feasibility study. *Skeletal Radiol* 2013;42(10):1403-12.
22. Ohana M, Moser T, Meyer N, Zorn PE, Liverneaux P, Dietemann JL. 3T tractography of the median nerve: optimisation of acquisition parameters and normative diffusion values. *Diagn Interv Imaging* 2012;93(10):775-84.
23. Kwon BC, Koh SH, Hwang SY. Optimal parameters and location for diffusion-tensor imaging in the diagnosis of carpal tunnel syndrome: a prospective matched case-control study. *AJR Am J Roentgenol* 2015;204(6):1248-54.
24. Khalil C, Hancart C, Le Thuc V, Chantelot C, Chechin D, Cotten A. Diffusion tensor imaging and tractography of the median nerve in carpal tunnel syndrome: preliminary results. *Eur Radiol* 2008;18(10):2283-91.