

Anatomical Variations of the Celiac Trunk in Adult Filipino Cadavers: A Retrospective Study

Karen June P. Dumlao, MD,¹ Pio Renato F. Villacorta, MD¹ and Olivia Agnes D. Mejia²

¹Department of Anatomy, College of Medicine, University of the Philippines Manila, Philippines

²Department of ENT, Medical Center Manila, Manila, Philippines

ABSTRACT

Objectives. The celiac trunk (CT) is the first major branch of the abdominal aorta and typically gives rise to the left gastric artery (LGA), common hepatic artery (CHA), and splenic artery (SA), which supply blood to the abdominal viscera. Variations in the branching pattern of the CT exist and knowledge of such is crucial when performing surgical, laparoscopic, and angiographic procedures. The aim of this study is to determine the anatomic variations of the CT in adult Filipino cadavers and to compare the proportions of these with those reported in the foreign literature.

Methods. Adult Filipino cadavers from the University of the Philippines College of Medicine Anatomy Laboratory were dissected by first year medical students from 2014-2019. The CT and its branches were identified, drawn on a separate piece of paper, and confirmed to be correct and accurate by an anatomist. The data collected from that period was reviewed. Percentages were calculated for the branching patterns identified. A Z-test of Two Populations was used to compare the results of the current study to that of Pinal-Garcia (2018), Pillay (2020) and Venieratos (2013).

Results. A total of 107 drawings based on 107 dissected preserved cadavers were reviewed. Ninety-two specimens (85.98%) showed typical branching into the LGA, CHA, and SA. The CT presented as a true tripod (*tripus Halleri*) in 75 specimens (70.09%) and as a bifurcation with one of the three arteries arising first along the trunk (false tripod) in 17 specimens (15.89%). Nine cadavers (8.41%) showed additional branches arising from the CT and four (3.74%) showed bifurcation of the CT with the third branch arising from a different artery.

Conclusion. The most common configuration of the CT among Filipino adult cadavers is a true tripod, followed by a false tripod, additional branching, and bifurcation of the CT with the third branch arising elsewhere. The present study most closely resembles the results of the study of Venieratos.

Keywords: celiac trunk, anatomic variations, Filipino

INTRODUCTION

The celiac trunk (CT) is the first major branch of the abdominal aorta (AA). It arises on the ventral aspect of the AA just as it passes through the aortic hiatus, at the level of T12. It supplies arterial blood to several abdominal organs, namely the stomach, liver, spleen, pancreas, biliary apparatus, and distal esophagus.¹ The three arteries considered to classically arise from the CT are the left gastric, common hepatic, and splenic arteries. This trifurcation was first described by von Haller in 1756 and is still known today as "*tripus Halleri*." Typically, the left gastric artery (LGA) supplies the lesser curvature of the stomach and lower esophagus, and anastomoses with the right gastric artery; the common hepatic artery (CHA) supplies the liver, biliary apparatus, pancreas, pylorus, and duodenum; and the splenic artery (SA) supplies the spleen.^{1,2} Knowledge of the CT branching

Corresponding author: Karen June P. Dumlao, MD
Department of Anatomy
College of Medicine
University of the Philippines Manila
547 Pedro Gil St., Ermita, Manila 1000, Philippines
Email: kpdumlaou@up.edu.ph

pattern is crucial in surgical, laparoscopic, organ retrieval and transplant, and interventional radiologic procedures in order to prevent post-procedural complications.^{2,3}

Variations in the branching of the CT are known to exist. These are believed to be parts of the fetal blood supply which failed to involute. During human development, the paired, fused dorsal aortas are connected to a primitive ventral anastomotic artery through a series of vitelline arteries. Failure of regression of some parts of the ventral anastomosis or vitelline arteries leads to anatomic variations in the branching of the CT and the abdominal viscera's blood supply.⁴

Numerous scholars have reported on the different anatomic variations of the CT. Most of these have been in the form of case reports and case series of cadaveric, clinical, and radiologic/angiographic studies. The most encompassing attempt at classifying the CT anatomy is from a systematic review of Panagouli in 2013³, which incorporated all known classifications of the CT. Among the classifications included in this review were the Lipschultz classification, which described four anatomic variations (Type I, where the CT trifurcates into the LGA, CHA, and SA [*tripus Halleri*]; Type II, where it bifurcates into the CHA and SA [hepatosplenic trunk] while the LGA arises from the AA; Type III, where it bifurcates into the CHA and LGA, while the SA arises from the AA; and Type IV, where the CT bifurcates into the SA and LGA, with the CHA arising from the AA) and the Michel classification, which described six CT variations (Type I, which is the classic *tripus Halleri*; Type II, where the CT bifurcates into a hepatosplenic trunk and the LGA arises from either the SA, CHA, or AA; Type III, wherein the CT forms a hepatosplenomesenteric trunk with the LGA arising from the AA; Type IV, where the CT forms a hepatogastric trunk with the SA arising from the superior mesenteric artery (SMA); Type V, where it forms a splenogastric trunk and the CHA arises from the SMA or other structures; and Type VI, where in the CT has a common origin with the SMA, forming a celiacomesenteric trunk). Other known classifications that were included were those of Higashi (2009), Adachi (1928), and Morita (1935). The Morita classification described a Type V variation, wherein the CT was absent and the LGA, SA, and CHA arose independently from the AA.³

Panagouli's systematic review included 36 articles composed of cadaveric, imaging, liver transplantation, and arteriography/corrosion/dissection studies, garnering a total of 12,196 specimens. A 10-tier classification consolidating all previously published variations was proposed. The review described the incidence and probability of occurrence of each type, and explored the influence of gender and race. The anatomical variations of the CT were described in five ethnicities, namely Korean, Caucasian, Japanese, Indian, and Negro/colored/Black. Across all ethnicities, the most common configuration of the CT was that where it branched into the LGA, CHA, and SA. Interestingly, Koreans and Japanese were found to have more variations compared to Caucasians.

The main objective of the study is to determine the anatomic variations of the CT among adult Filipino cadavers in order to provide baseline knowledge of CT branching patterns among Filipinos. Specifically, it aims to compare the proportions of these anatomic relationships with those reported in the foreign literature. Data gathered in this study may prove to be useful in preventing post-procedural complications among Filipino patients.

MATERIALS AND METHODS

All data collected from the dissection of preserved human cadavers at the University of the Philippines College of Medicine Anatomy Laboratory from 2014 to 2019 were included in the study. The dissection of the 107 cadavers were performed by first year medical students under the supervision of two anatomists as part of their requirements in their anatomy laboratory course. All cadavers were adult Filipinos with unknown sex, age, and medical histories. Instructions on how to do the abdominal incisions and dissection were given to the students and adherence to these instructions were guaranteed through direct supervision by the anatomists. Once the celiac trunk has been identified, the branches of the CT were traced and drawn on a separate piece of paper for documentation, these were checked and confirmed by the anatomists to be an accurate representation. This is a retrospective study using convenience sampling from the submitted drawings of the first year medical students. The drawings were assessed and recorded from October 15 to October 17, 2022. A trifurcation of the CT into the LGA, CHA, and SA was considered the typical branching pattern and all other configurations were considered variations. Percentages were calculated for the patterns of branching identified. The results were compared to the studies of Pinal-Garcia, Pillay, and Venieratos, based on Panagouli's proposed classification. The Z-test of Two Proportions was performed with the confidence interval set at 95% and the level of significance set at $p < 0.05$.

This study was approved and exempted by the University of the Philippines Manila Research Ethics Board. Since this is a retrospective study on previously collected data from cadavers, no informed consent was needed. No funding was required for this study.

RESULTS

A total of 107 drawings from 107 Filipino cadavers were included in the study. Among these, the CT gave rise to its three typical branches (LGA, CHA, SA) in 85.98% of the cadavers ($n=92$). It presented as a true trifurcation (*tripus Halleri*; true tripod; Lipschutz, Adachi, Morita, Michel, and Panagouli Type I) with a common origin for all three branches in 75 specimens (70.09%; 75/107) (Figure 1) and as a bifurcation with one of the three arteries arising first along the trunk (false tripod; Higashi Type I, III, IV; Panagouli Type I) in 17 specimens (15.89%; 17/107).

Among those presenting as a false tripod, the LGA, CHA, and SA arose as the first branch of the CT in 64.71% (11/17) (Higashi Type I), 23.53% (4/17) (Higashi Type III), 11.76% (2/17) (Higashi Type IV), respectively. (Figure 2)

Four of the 107 specimens (3.74%) demonstrated bifurcation of the CT with the third branch arising from a different artery (Lipshutz Type II, III, IV; Adachi Type II, V, VI; Morita Type II, III, IV; Michel Type II, IV, V; Panagouli Type II) (Figure 3). In all four specimens, the CT formed a hepatosplenic trunk with the LGA arising independently from the AA (n=1) (Lipshutz, Adachi, Morita, Michel, and Panagouli Type II), SA (n=1) (Michel and Panagouli Type II),

superior mesenteric artery (SMA) (n=1) (Panagouli Type II), and proper hepatic artery (n=1) (Panagouli Type II).

Nine cadavers (8.41%) had additional CT branches, a pattern that corresponds to Type III of Panagouli's classification. In these cadavers, a fourth branch arose from the CT in addition to the LGA, CHA, and SA (Figure 4). These branches were the dorsal pancreatic artery (n=3), gastroduodenal artery (n=1), and right gastric artery (RGA) (n=1). One specimen had an unidentified fourth branch which formed an anastomosis with the SMA and three other specimens had ambiguous, unidentified fourth branches.

A celiacomesenteric trunk, wherein the CT and the SMA had a common origin, was seen in one cadaver (0.93%) (Adachi Type IV; Michel Type VI; Panagouli Type IV) (Figure 5). Similarly, in one specimen (0.93%), the CT bifurcated into the CHA and an unidentified trunk (Panagouli Type II). The unidentified trunk subsequently branched into the SMA and RGA, while the LGA and SA arose from the CHA.

Tables 1 and 2 compare the results of the present study with that of Pinal-Garcia, Pillay, and Venieratos, respectively. Pinal-Garcia dissected 140 Mexican cadavers, Pillay dissected 66 South African Caucasian cadavers, and Venieratos dissected 77 Greek cadavers. The results of the current study most closely resemble the results of Venieratos, where a trifurcation was the most common configuration with a predominantly true tripod branching pattern.

DISCUSSION

In the Department of Anatomy, we use all available learning strategies in teaching our students. Requiring our students to draw anatomical structures as they see it after their dissection is one of the methods we use to help the

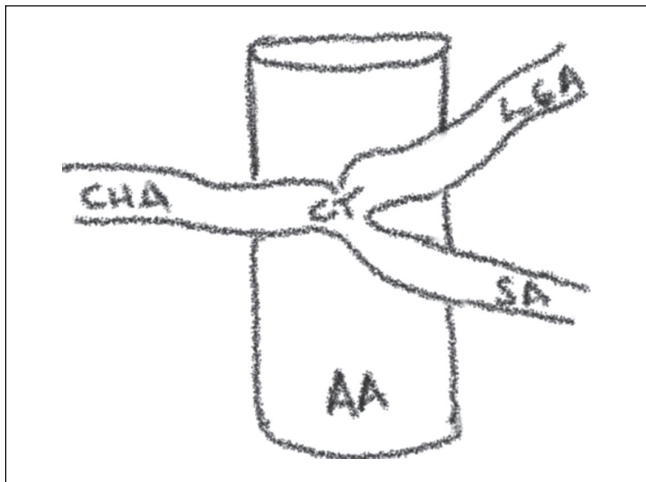


Figure 1. True trifurcation with a common origin for all three branches. AA: Abdominal aorta; CT: celiac trunk; LGA: left gastric artery; CHA: common hepatic artery; SA: splenic artery.

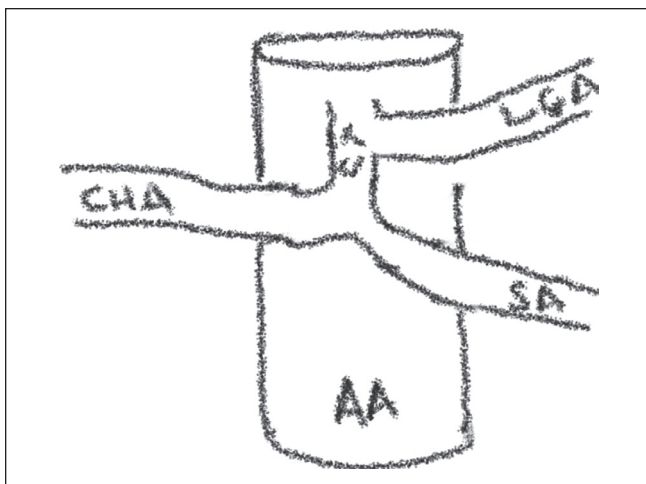


Figure 2. False tripod wherein one of the branches arose as the first branch of the CT. AA: Abdominal aorta; CT: celiac trunk; LGA: left gastric artery; CHA: common hepatic artery; SA: splenic artery.

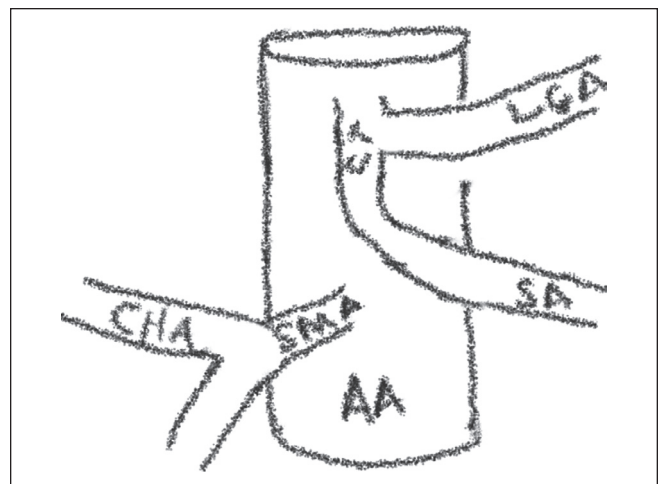


Figure 3. Bifurcation of CT with the third branch arising from a different artery. AA: Abdominal aorta; CT: celiac trunk; LGA: left gastric artery; CHA: common hepatic artery; SA: splenic artery; SMA: superior mesenteric artery.

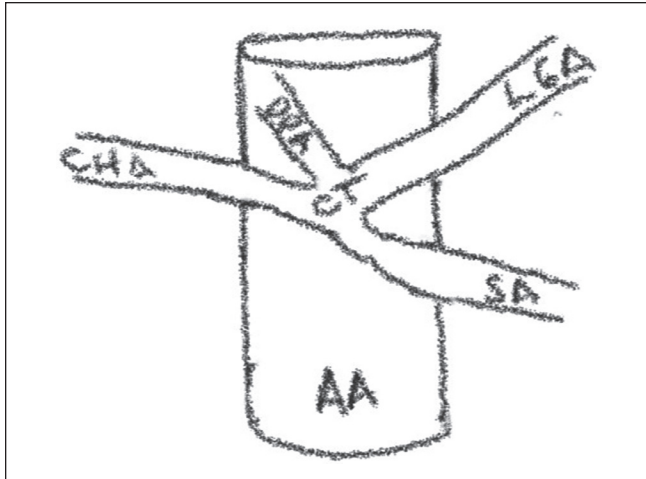


Figure 4. A fourth branch arose from the CT in addition to the LGA, CHA, and SA. AA: Abdominal aorta; CT: celiac trunk; LGA: left gastric artery; CHA: common hepatic artery; SA: splenic artery; DPA: dorsal pancreatic artery.

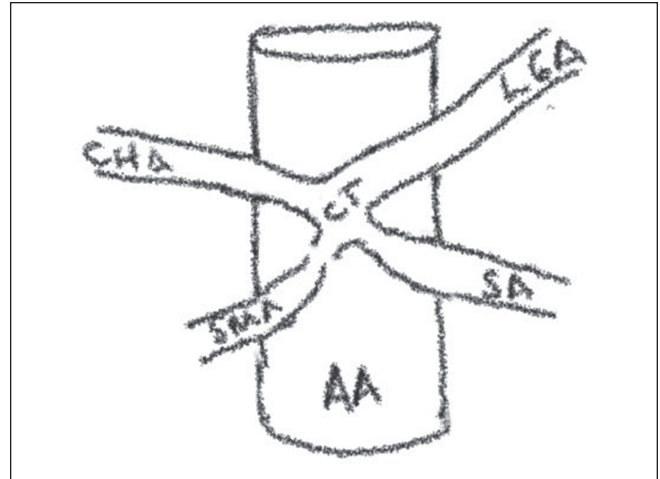


Figure 5. A celiacomesenteric trunk, wherein the CT and the SMA had a common origin. AA: Abdominal aorta; CT: celiac trunk; LGA: left gastric artery; CHA: common hepatic artery; SA: splenic artery; SMA: superior mesenteric artery.

Table 1. Comparison of Percentage Distribution to the Pinal-Garcia Study⁵

Pattern	Present Study (N=107)	n	Pinal-Garcia (N=140)	n	p-value
Trifurcate	85.98%	92	43.6%	61	0
True	70.09%	75	7.1%	10	0
False	15.89%	17	36.4%	51	0.0003
Bifurcation	3.74%	4	7.1%	10	0.2578
Additional branches	8.41%	9	47.9%	67	0

Table 2. Comparison of Percentage Distribution between studies (Pillay⁶ and Venieratos⁷)

Pattern	Present Study (N=107)	n	Pillay (N=66)	n	Venieratos (N=77)	n	p-value
Trifurcate	85.98%	92	84.84%	56	90.9%	70	0.3102
True	70.09%	75	46.96%	31	74.0%	57	0.5612
False	15.89%	17	37.88%	25	16.9%	13	0.8548
Bifurcation	3.74%	4	4.55%	3	1.3%	1	0.3153
Additional branches	8.41%	9	10.61%	7	5.2%	4	0.4019

students retain the knowledge. Drawing from observation and actual dissection of cadavers has been proven to improve memorization of anatomical structures.⁸

In our study, the typical branching into the LGA, CHA, and SA was the predominant CT configuration. Specifically, most specimens exhibited the true tripod or *tripus Halleri* branching pattern, followed only by the false tripod pattern. Among those that exhibited the false tripod configuration, the LGA was the most common first branch. It is also important to note that in our study, there were a number of cadavers where there was a fourth branch that arose from the CT (n=9, 8.41%). There were also a few where the CT bifurcated into two of its typical branches and the third artery arose separately from a different vessel (n=4, 3.47%). This distribution is different from the results of Panagouli's systematic review

and classification wherein additional branches (Type III) was less common than a bifurcated CT (Type II). The presence of a celiacomesenteric trunk however, was similarly rare in our study and in that of Panagouli's study where its incidence was only 0.93% and 0.76%, respectively.

As previously mentioned, multiple studies have described anatomical differences in the branching pattern of the CT. The most common type of branching, which is considered typical or normal, is the division of the CT into three branches – the LGA, CHA, and SA. This presentation of the CT has been reported to be between 40-94% in cadaveric studies.⁵ In Panagouli's systematic review, this presentation was found in 89.42% of cases.³ However, the study did not delineate between the true and false tripod configuration. Some studies have reported that the false

tripod, wherein the CT was bifurcated and one of the three arteries arose earlier in the course of the trunk, was the predominant configuration.⁹⁻¹¹ However, as seen above, the study of Venieratos demonstrated that the true tripod was the predominant form.⁶

As shown on the Z-test of Two Populations, the present study most closely resembles the results of Venieratos. Among adult Filipino cadavers, the most common configuration of the CT among Filipino adult cadavers is that of a true tripod, followed by a false tripod, additional branching, and bifurcation of the CT with the third branch arising from elsewhere.

This study had several limitations. First, the past medical history of all cadavers was unknown. This precluded knowledge on previous surgeries that may have altered the current anatomy. Second, dissection was done by first year medical students. Although supervised, inadvertent damage to the original anatomy may have happened secondary to amateur dissection techniques. Third, classification of the anatomic variations was based on 2-dimensional representative drawings and analyzed by individuals who were not present in all dissections. This could have been a source of reader bias.

Despite the limitations, the importance of this study cannot be discounted. To the best of the author's knowledge, this is the first anatomic study on the CT among Filipino cadavers.

Proper dissection and anatomical identification of the CT and all its branches is very important in procedures involving the abdomen. In liver harvest and transplantation, and tumor chemoembolization for liver malignancies, for example, accurate vascular identification is crucial to avoid bleeding or ischemia of the said organ.¹² In the study by Nuossios et al., they encountered rare and unclassified anatomical variations of the CT. These vessels which course through an unusual path, when not recognized or traced are very susceptible to damage during surgery and may have detrimental effects on the vascularity of the organ and cause leaks in anastomosis.¹³ Different racial groups have exhibited differences in the predominant branching pattern of the CT.³ Our study offers baseline knowledge of CT branching pattern among Filipinos. Familiarization with what is common and recognition of what is aberrant arterial vasculature surrounding the CT will prove beneficial in preventing procedural complications in the Filipino patient.

CONCLUSION

The most common configuration of the CT among Filipino adult cadavers is a true tripod, followed by a false tripod, additional branching, and bifurcation of the CT with the third branch arising elsewhere. The present study most closely resembles the results of the study of Venieratos involving Greek cadavers. This cadaveric study provides baseline data on anatomic CT configuration among Filipinos.

Statement of Authorship

All authors have substantial contributions to the conception or design of the work, the acquisition, analysis, or interpretation of data for the work, drafting the work or revising it critically for important intellectual content, final approval of the version to be published, and agreed to be accountable for all aspects of the work in ensuring that questions related to the accuracy or integrity of any part of the work are appropriately investigated and resolved.

Author Disclosure

All authors have nothing to disclose.

Funding Source

None.

REFERENCES

- Moore K, Dalley A. *Clinically Oriented Anatomy*, 4th ed. Philadelphia: Lippincott Williams & Wilkins; 1999. pp. 221, 235.
- Karrar Alsharif MH, Taha KM, Elamin AY, Al-Dosari KH. Behavioral anatomy of the celiac trunk based on human embryology. *Br J Med Res*. 2016;14(11):1-7.
- Panagouli E, Venieratos D, Lolis E, Skandalakis P. Variations in the anatomy of the celiac trunk: a systematic review and clinical implications. *Ann Anat*. 2013 Dec;195(6):501-11. doi: 10.1016/j.aanat.2013.06.003.
- Gregory Walker T. Mesenteric vasculature and collateral pathways. *Semin Intervent Radiol*. 2009 Sep;26(3):167-74. doi: 10.1055/s-0029-1225663.
- Pinal-Garcia DF, Nuno-Guzman CM, Gonzalez-Gonzalez ME, Ibarra-Hurtado TR. The celiac trunk and its anatomical variations: a cadaveric study. *J Clin Med Res*. 2018 Apr;10(4):321-9. doi: 10.14740/jocmr3356w.
- Pillay D, Nischk SD, Ndou R. Variations in the configuration of the celiac trunk among South Africans: clinical relevance. *Int J Morphol*. 2020;38(6):1662-7.
- Venieratos D, Panagouli E, Lolis E, Tsaraklis A, Skandalakis P. A morphometric study of the celiac trunk and review of the literature. *Clin Anat*. 2013 Sep;26(6):741-50. doi: 10.1002/ca.22136.
- Reid S, Shapiro L, Louw G. How Haptics and Drawing Enhance the Learning of Anatomy. *Anat Sci Educ*. 2019 Mar;12(2):164-72. doi: 10.1002/ase.1807.
- Higashi N, Shimada H, Simamura E, Hatta T. [Branching patterns of the celiac artery as the hepato-gastro-splenic trunk]. *Kaibogaku Zasshi*. 2009 Mar;84(1):7-10.
- Dos Santos PV, Barbosa ABM, Targino VA, de Almeida Silva N, de Melo Silva YC, Barbosa F, et al. Anatomical variations of the celiac trunk: a systematic review. *Arq Bras Cir Dig*. 2018 Dec;31(4):e1403. doi: 10.1590/0102-672020180001e1403.
- Iezzi R, Cotroneo AR, Giancristofaro D, Santoro M, Storto ML. Multidetector-row CT angiographic imaging of the celiac trunk: anatomy and normal variants. *Surg Radiol Anat*. 2008 Jun;30(4):303-10. doi: 10.1007/s00276-008-0324-7.
- Tanka M, Abazaj E. Anatomical variations of celiac trunk anatomy and their clinical importance. *Int J Sci Res*. 2015 Dec;4(12):12-4.
- Nuossios G, Dimitriou I, Chatzis I, Katsourakis A. The main anatomic variations of the hepatic artery and their importance in surgical practice: review of the literature. *J Clin Med Res*. 2017 Apr;9(4):248-52. doi: 10.14740/jocmr2902w.