

Paraneoplastic relapsing minimal change disease associated with type A thymoma in an elderly patient: A case report and literature review

Clara Lee Ying Ngoh, MBChB, MRCP¹, Giap Hean Shaun Goh, MBBS, FRCPA², Weng Kin Wong, MRCP, FAMS³

¹Department of Medicine, National University Health System, Singapore, ²Department of Pathology, National University Health System, Singapore, ³Department of Medicine, National University Health System, Singapore

SUMMARY

Thymoma is a rare mediastinal tumour that can be accompanied by different paraneoplastic syndromes. Here we report a case of Type A thymoma associated with relapsing minimal change disease (MCD). This case highlights: (1) The need to balance rapid prednisolone weaning against risk for relapse in an elderly patient at risk for steroid-induced complications. (2) The addition of calcineurin inhibitor in relapsed thymoma-related MCD, to achieve steroid sparing effects. Resection of the offending tumour and prompt immunosuppressive therapy are critical in getting best renal and overall outcomes in this rare entity.

CASE REPORT

A 65-year-old Chinese female presented with an incidental finding of a right 11cm x 7cm anterior mediastinal mass on chest radiograph in January 2016. Computer tomography detailed the mass abutting the mediastinum and right heart. She declined further investigation until May 2016, when she re-presented with a one-month history of new onset lower extremity and abdominal swelling. She had no known history of liver or kidney disease.

Vital signs revealed high blood pressure. Physical examination was significant for ascites, pitting oedema in lower extremities up to level of mid-thighs and decreased breath sounds on right lung field. There was no lymphadenopathy or breast mass.

Laboratory values were indicative of nephrotic syndrome: Serum albumin 17g/L and 24-hour urinary protein excretion 14.7g/day. There was evidence of acute kidney injury with serum urea 12.7mmol/L and serum creatinine 212µmol/L (baseline 5.2mmol/L and 55µmol/L in January 2016 respectively). Anti-nuclear antibodies were detected at 1:320 titers with homogenous pattern, although anti-double stranded DNA antibodies were absent with normal complement levels. Renal vein thrombosis was excluded with Doppler examination. Anti-acetylcholine receptor antibodies were detected at 0.91nmol/L, although there was no clinical or neurophysiological evidence of myasthenia gravis.

Fine needle aspiration of the mediastinal mass confirmed a large thymoma. A native kidney biopsy showed no histologic

abnormalities on light microscopy and negative immunofluorescence. These changes were consistent with MCD. The patient was treated with diuretics and started on oral prednisolone 60mg/day (1mg/kg ideal body weight/day) on 19 July 2016, until she underwent complete thymoma resection and partial pericardiectomy on 18 August 2016. Pathological results showed a World Health Organization (WHO) type A, Masaoka stage IIA thymoma^{1,2} (Figure 1). She declined neoadjuvant radiotherapy.

After four weeks of steroid therapy, and prior to thymoma resection, her serum creatinine had improved to 113µmol/L with marked improvement in generalised oedema and reduction in 24-hour urinary protein excretion to 11.2g/day (Figure 2). She never required renal replacement therapy.

The patient experienced personality changes, which occurred around the time of onset of nephrotic syndrome. Neurological examination and computed tomography (CT) brain imaging were normal. After four weeks of steroid therapy and post thymoma resection, she developed steroid induced psychosis 22 Aug 2016, with delusions that family members were using "black magic" against her. Prednisolone was hence tapered to 40mg daily. Creatinine remained stable at 70–80µmol/L and 24-hour urinary protein excretion continued to improve to 8.8g/day. Unfortunately, she required psychiatric admission for aggressive behaviour in December 2016, prompting further reduction in prednisolone to 10mg daily by 24th January 2017. This, together with prescribed risperidone, has resolved her psychiatric symptoms. Her prednisolone dose was further reduced in February 2017 to 5mg thrice per week due to Cushing's features.

Unfortunately, the patient had a MCD relapse on 11 March 2017 while on prednisolone 5mg thrice a week. There was again evidence of acute kidney injury with creatinine 127µmol/L. Her prednisolone dose was increased back to 60mg/day. Because of previous side effects with steroids, cyclosporin was concomitantly started at 100mg twice daily (4mg/kg per day in divided doses), with a plan to taper off prednisolone eventually.

She went into complete remission on 25 April 2017, with resolution of acute kidney injury. During this time, CO levels

This article was accepted: 21 December 2017
Corresponding Author: Weng Kin Wong
Email: wkwong100@yahoo.com

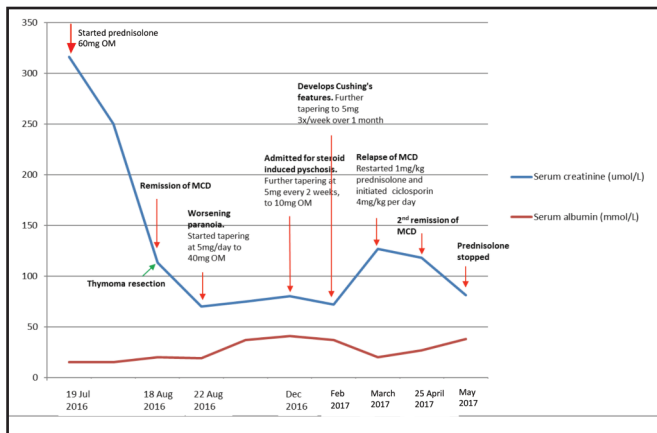


Fig. 1: Trajectory of serum creatinine and albumin levels from July 2016 to May 2017. Horizontal axis dimensions are not drawn to scale.

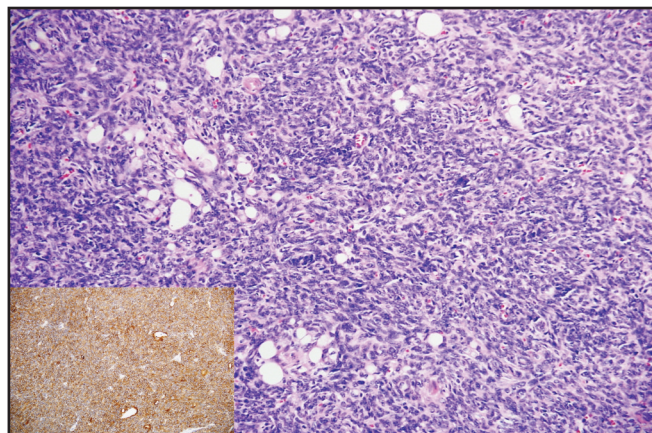


Fig. 2: Thymoma (Type A) composed of sheets of ovoid to spindle cells. Inset: Diffuse expression of cytokeratin AE1/3.

have been maintained between 100–150µg/L. Prednisolone has also been tapered by 10mg every 1.5 weeks. As of end May 2017, she remains in remission on cyclosporin without prednisolone.

DISCUSSION

This case depicts a rare presentation of thymoma-associated paraneoplastic glomerulonephritis, specifically manifesting as MCD. The most frequently observed type of thymoma associated with MCD is B2, followed by AB, B3 and C.³ To the best of our knowledge, this is the first reported case of Type A thymoma with renal disease association.

The case is made more unique because renal and thymic abnormalities were diagnosed simultaneously. In the largest series of thymoma-associated renal diseases to date, nephropathy occurred at a mean interval of nine years after the tumour had been treated.³

The link between thymoma and MCD remains elusive. It is hypothesised that an imbalance between autoreactive lymphocytes and immunoregulatory mechanisms occur when patients develop thymomas.⁴ Unregulated T-cells then secrete lymphokines that increase glomerular basement membrane permeability, leading to MCD.⁴ Paradoxically, thymectomy has been reported to further suppress immunoregulatory lymphocytic subpopulations - explaining the lead time between thymoma resection and MCD occurrence.⁴ We speculate that Type A thymomas may have caused a different lymphocyte signature that led to much earlier presentation of nephropathy in our patient.

Most case reports of thymoma-related MCD have employed surgical resection of primary thymoma and corticosteroids as mainstay of therapy.³ The most frequent regimen employed is prednisolone 1mg/kg/day until remission, followed by progressive tapering of dose over six months. 84% of patients are steroid responsive, just as in our case.³ However, we had to taper steroids more quickly due to this patient’s psychiatric complications. One wonders if there were thymoma-related synaptic antibodies that increased her risk for mental illness. There has been a case report of anti-N-methyl-D-aspartate

(NMDA) receptor encephalitis with concurrent thymic hyperplasia, and further workup for these antibodies will be considered if her psychiatric symptoms recur.⁵ This case should encourage nephrologists to taper high dose steroids more quickly than current guidelines suggest, in certain subgroups of patients.

In addition, there has been little published data on treatment of relapsed thymoma-related MCD. Here we report the concomitant use of prednisolone and cyclosporin during her MCD relapse, which allowed us to achieve rapid remission, and taper off prednisolone quickly to minimise steroid-related complications.

The majority of deaths in the series of thymoma-associated renal diseases were from unresectable or recurrence of thymoma.³ Hence, this patient has a good renal prognosis so long as malignancy does not recur.

CONCLUSION

This case presents a rare entity of paraneoplastic minimal change disease in an elderly patient. Prompt resection of the offending tumour, as well as early immunosuppressive therapy, are critical in getting best renal and overall outcomes in this rare entity.

REFERENCES

1. Borst HG, Walterbusch G, Schaps D: Extensive aortic replacement using “elephant trunk” prosthesis. *Thorac Cardiovasc Surg* 1983; 31: 37-40.
2. Wong CH, Wyatt MG, Jackson R, Hasan A. A dual strategic approach to mega-aortic aneurysms. *Eur J Cardiothorac Surg* 2001; 19: 528-30.
3. Milewski RK, Szeto WY, Pochettino A, Moser GW, Moeller P, Bavaria JE. Have hybrid procedures replaced open aortic arch reconstruction in high-risk patients? A comparative study of elective open arch debranching with endovascular stent graft placement and conventional elective open total and distal aortic arch reconstruction. *J Thorac Cardiovasc Surg* 2010; 140: 590-7.
4. Karck M, Kamiya H. Progress of the treatment for extended aortic aneurysms; is the frozen elephant trunk technique the next standard in the treatment of complex aortic disease including the arch? *Eur J Cardiothorac Surg* 2008; 33: 1007-13.
5. Tian DH, Wan B, Di Eusanio M, Black D, Yan TD: A systematic review and meta-analysis on the safety and efficacy of the frozen elephant trunk technique in aortic arch surgery. *Ann Cardiothorac Surg* 2013 Sep; 2(5): 581-91.