

Reliability of the ultrasound classification system of thyroid nodules in predicting malignancy

Fariahah Abd Ghani, MB BCh BAO¹, Nurismah Md Isa, Mpath³, Husyairi Harunarashid, MCLinEpid², Shahrin Niza Abdullah Suhaimi, MS⁴, Radhika Sridharan, FRCR¹

¹Department of Radiology, Universiti Kebangsaan Malaysia Medical Center, Cheras, Kuala Lumpur, Malaysia, ²Center for Research in Emergency Medicine (CREM), Universiti Kebangsaan Malaysia Medical Center, Cheras, Kuala Lumpur, Malaysia, ³Department of Pathology, Universiti Kebangsaan Malaysia Medical Center, Cheras, Kuala Lumpur, Malaysia, ⁴Department of General Surgery, Universiti Kebangsaan Malaysia Medical Center, Cheras, Kuala Lumpur, Malaysia

ABSTRACT

Aim: This study aims to evaluate the reliability of the Ultrasound (U) Classification system in predicting thyroid malignancy by using pathology diagnosis as the reference standard.

Materials and Methods: It was a cross sectional study carried out at Universiti Kebangsaan Malaysia Medical Centre (UKMMC), Malaysia. Records of patients with focal thyroid nodules on ultrasound (US) for which US guided fine needle aspiration cytology (FNAC) was performed and pathology results were available, from January 2014 to May 2016 were selected for review. Correlation of the U Classification with pathology results was assessed. Sensitivity, specificity, positive likelihood ratio, negative likelihood ratio, predictive value, negative predictive value and accuracy were calculated in a conservative and non-conservative method. The threshold for statistical performance was set at 0.05. Each sonographic feature was also compared with its pathology results.

Results: A total of 91 patients with 104 nodules were eligible. 12 nodules out of 104 (11.5%) were malignant. The sensitivity, specificity, positive likelihood ratio, negative likelihood ratio, positive predictive value, negative predictive value and accuracy were 100%, 91.3%, 11.5, 0.0, 60%, 100% and 92.3%, and 100%, 91.4%, 11.7, 0.0, 78.6%, 100% and 93.5%, for the non-conservative and conservative method of calculations respectively.

Conclusion: The U Classification is reliable in predicting thyroid malignancy. More evidence is nevertheless necessary for widespread adaptation and use.

KEY WORDS:

Ultrasound; Thyroid Nodules; Thyroid Carcinoma; Fine Needle Aspiration Biopsy

INTRODUCTION

Thyroid nodules are vastly prevalent whereas thyroid cancer is a relatively rare entity. While thyroid nodules are discovered on clinical examination in 3-7% of the adult population, the incidence of detectable nodules on ultrasound (US) is between 30% to 70% and rises

progressively with age.¹ However, only less than 10% of these ultrasound detected nodules are malignant.² Thyroid cancer incidence in Malaysia is 4.9 per 100 000 population.³

High resolution US is recommended as the best first line diagnostic tool in the evaluation of thyroid nodules.⁴ Ultrasound has been widely used to differentiate benign from malignant nodules, thus aids in selecting nodules for fine needle aspiration cytology (FNAC). The improved detection of thyroid nodules using US has resulted in an increased rate of FNAC and in the number of thyroid cancers diagnosed.² Appropriate sonographic criteria is hence valuable to avoid unnecessary FNAC in benign thyroid nodules, as well as causing inappropriate patient anxiety.

In 2015, the Malaysian Endocrine and Metabolic Society (MEMS) has proposed Malaysian Consensus Guidelines on screening, diagnosis, treatment and follow-up of patients with well-differentiated thyroid cancer. They recommended using US signs in summation to identify malignant nodules and guide FNAC, as proposed by the British Thyroid Association (BTA) (Figure 1). The BTA Guidelines in 2014 suggested the use of Ultrasound (U) Classification, allowing standardized follow up of indeterminate thyroid nodules.⁵ According to the Malaysian Consensus Guidelines, a benign nodule on an US (U2 category) should be considered as reassuring and does not necessitate FNAC, unless there is a statistically increased risk of malignancy, with no need for follow up.

The purpose of this study was to evaluate the reliability of the U Classification system in predicting thyroid malignancy using the sensitivity and specificity of the ultrasound classification system in predicting thyroid malignancy with the corresponding pathology results as the reference standard. In this study, we would also like to describe each ultrasound feature in predicting benign and malignant thyroid nodules, according to the U Classification system in the BTA Guidelines, with accompanying pictorial examples.

MATERIALS AND METHODS

Ethical Considerations

Institutional review board approval was obtained for this cross sectional retrospective study.

This article was accepted: 28 November 2017

Corresponding Author: Fariahah Abd Ghani

Email: fariahahghani@gmail.com

Study Population

This is a retrospective study conducted in the Radiology Department of Universiti Kebangsaan Malaysia Medical Centre (UKMMC), Malaysia. The patients' data were collected from records of all patients who underwent US guided FNAC for US-detected focal thyroid nodules from January 2014 to May 2016, with available pathology results.

The inclusion criteria were (a) Nodules with benign or malignant results at cytology or histology examination. (b) Patients who underwent thyroid surgery after specimens from cytology examination were classified as suspicious for thyroid carcinoma, indeterminate, or inadequate.

Patients who had nodules cytologically diagnosed as suspicious for thyroid carcinoma, indeterminate, or inadequate but did not undergo surgery were excluded from the study. Patients who have had previous history of total or partial thyroidectomy, with or without radio-iodide ablation were also excluded.

Thyroid Ultrasound

All available US scans of the thyroid gland and neck areas were performed using a linear-array transducer (5-12 MHz) on ultrasound scanners HD11/ HD11 XE/ iU22 Phillips Medical Systems or Toshiba Xario200 using an optimized gain.

Nodule Classification

The radiologist, using Osirix workstation or Medweb, reviewed all images. All thyroid nodules were characterized according to the relevant nodule size, nodule composition, cystic component, echogenicity, margins, evidence of calcifications, taller than wide, halo, colour flow and lymphadenopathy.

The nodule size was classified as <1cm, 1-2cm or >2cm. The nodule composition was classified as either solid, cystic, mixed solid and cystic or microcystic/ spongiform. If there was cystic component, the presence of ring down sign, if any, which represents colloid, was noted. Masses with mixed components were evaluated on the basis of its solid component. Echogenicity was classified as markedly hypoechoic, hypoechoic, isoechoic or hyperechoic. When the nodule echogenicity was similar to that of the thyroid parenchyma, it was classified as isoechoic. The nodule was classified as markedly hypoechoic when the echogenicity was less than that of the adjacent strap muscles. Margin was classified as well defined, irregular/ lobulated or spiculated. Calcifications, when present, were categorized as microcalcifications, macrocalcifications or rim/egg shell calcifications. Microcalcifications is defined as hyperechoic foci equal to, or less than 3 mm and macrocalcification is defined as hyperechoic foci larger than 3 mm. A nodule was categorized as taller than wide i.e. greater in its antero-posterior dimension than in its transverse dimension, or wider than tall. Presence of halo was classified as regular/ continuous or interrupted. Assessment on colour flow was classified as central, peripheral, mixed or none. Any lymphadenopathy was noted, in the context of suspected malignancy representing metastases. Suspicious lymph nodes is defined as size more than 10mm, loss of fatty hilum, rounded bulging shape, irregular margins, heterogeneous

echotexture, calcifications, cystic areas or increased vascularity throughout the lymph node.

The thyroid nodules were given a U1-U5 score based on the features that were described in the BTA Guidelines i.e. normal (U1), benign (U2), equivocal/indeterminate (U3), suspicious (U4) and malignant (U5).

Ultrasound Guided Fine Needle Aspiration and Histopathology

After US evaluation of the thyroid gland, US guided FNAC was performed. US guided FNAC was performed in either the thyroid nodule with suspicious US features or the largest thyroid nodule if no suspicious US features were detected. US guided FNAC was performed with a 23-gauge needle attached to a 10ml disposable plastic syringe. Aspirated materials were expelled onto glass slides, smeared and then sent to the cytopathology laboratory. The cytopathology reports were classified as benign, indeterminate, suspicious for malignancy, malignant, or inadequate. Histopathology reports were obtained for cases that were cytologically reported as inadequate, indeterminate or suspicious of malignancy.

Statistical Analysis

Statistical analysis was performed with the SPSS software package IBM version 23. There were conservative and non-conservative methods of analysis of the U classification. For conservative method, only U2 was classified as negative test whereas only U5 was classified as positive test. For non-conservative method, both U2 and U3 were classified as negative test whereas both U4 and U5 were classified as positive test. A significant difference was defined as p value less than 0.05.

A receiver operating characteristic (ROC) curve analysis was used to examine the diagnostic performance of the U Classification in determining a malignant result.

RESULTS

A total of 91 patients with 104 nodules were eligible for the study. There were 83 female and 21 male patients. The youngest patient was 27 years old and the oldest was 80, with a mean age of 54.7 years. Ethnically, there were 51 (49.0%) Malay patients, 25 (33.7%) Chinese, 13 (12.5%) Indian and 5 (4.8%) were of other races.

Each ultrasound characteristic and its corresponding pathology results are presented in Table 1. We present the pictorial examples of each U Classification from our study, and its associated discriminatory features (Figures 2-4).

The overall diagnostic yield in predicting benign and malignant nodules was (U2 n=32 + U5 n=14)/ (U2 n=32 + U3 n=52 + U4 n=6 + U5 n=14) 44.2%.

Diagnostic Accuracy of U Classification of Nodules

Of the 104 nodules, 92 (88.5%) were benign and 12 (11.5%) were malignant. Of the 12 malignant nodules, eight (66.7%) were papillary carcinoma, three (25%) were medullary carcinoma and one (8.3%) was poorly differentiated insular type. Out of 20 nodules, which were classified as U4 and U5,

Table I: Summary of US characteristics and corresponding pathology results

Characteristic	Malignant nodules (n=12)	Benign nodules (n=92)
Composition		
Solid	9 (75%)	30 (32.6%)
Cystic	0	1 (1.1%)
Mixed solid cystic	3 (25%)	44 (47.8%)
Microcystic/spongiform	0	17 (18.5%)
Ring down sign		
Present	0	2 (3.2%)
Absent	3 (100%)	60 (96.8%)
NA (no cystic component)	9	30
Echogenicity		
Markedly hypoechoic	2 (16.7%)	0
Hypoechoic	10 (83.3%)	19 (20.9%)
Isoechoic	0	61 (67.0%)
Hyperechoic	0	11 (12.1%)
NA (no solid component)	0	1
Calcification		
Microcalcification	6 (50%)	3 (3.2%)
Macrocalcification	5 (41.7%)	5 (5.4%)
Rim calcification	0	6 (6.5%)
Equivocal echogenic foci	0	7 (7.6%)
None	1 (8.3%)	71 (77.2%)
Margin		
Well defined	11 (91.7%)	91 (98.9%)
Irregular/ lobulated	1 (8.3%)	1 (1.1%)
Spiculated	0	0
Taller than wide		
No	7 (58.3%)	88 (95.7%)
Yes	5 (41.7%)	4 (4.3%)
Halo		
Regular	0	47 (51.1%)
Interrupted	0	0
Absent	12 (100%)	45 (48.9%)
Colour		
Central	0	5 (6.0%)
Peripheral	3 (37.5%)	14 (16.7%)
Mixed	1 (12.5%)	10 (11.9%)
None	4 (50%)	55 (65.4%)
NA (not taken)	4	8
Lymphadenopathy		
No	11 (91.7%)	92 (100%)
Yes	1 (8.3%)	0

*NA- non applicable

Table II: Diagnostic indices of US classification of nodules using the non-conservative and conservative method

Statistic	Non-Conservative Test Positive- U4-U5 Test Negative- U2-U3		Conservative Test Positive- U5 Test Negative- U2	
	Value	95% CI	Value	95% CI
Sensitivity	100%	73.5 to 100%	100%	71.5 to 100%
Specificity	91.3%	83.6 to 96.2%	91.4%	76.9 to 98.2%
Positive LR	11.5	5.9 to 22.3	11.7	4.0 to 34.4
Negative LR	0.0		0.0	
Prevalence	11.5%	6.11% to 19.3%	23.9%	12.6 to 38.8%
PPV	60.0%	36.1 to 80.9%	78.6%	49.2 to 95.3%
NPV	100.0%	95.7 to 100.0%	100%	89.1 to 100%
Accuracy	92.3%		93.5%	

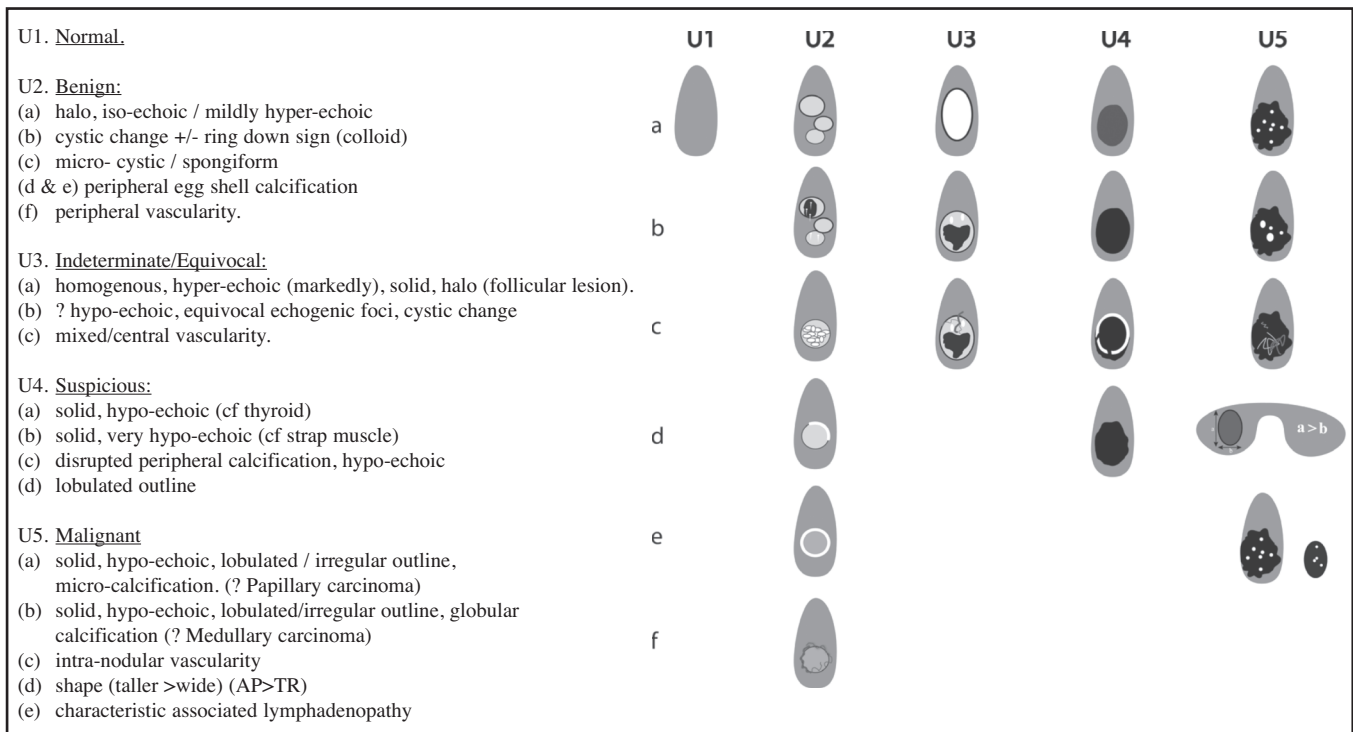


Fig. 1: U Classification for the ultrasound assessment of thyroid nodules: Descriptions and graphic compilation of the signs to provide the U score that can be used to differentiate benign from malignant nodules. (Table and Figure were taken directly from the 2014 BTA Guidelines.)⁵

eight nodules turned out benign on pathological diagnosis (five were classified as U4 and three were U5) giving a false positive rate of 0.09, with a few examples shown in Figure 6. All of the 84 nodules that were classified as U2 and U3 were confirmed benign on pathological diagnosis (true negatives). There were no false negatives in our study.

The ROC curve analysis revealed that the diagnostic accuracy of thyroid ultrasound using the U Classification system was very good AUC= 0.98 (CI 0.956-1.000).

DISCUSSION

Main Findings

The prevalence of thyroid cancer in our sample population of nodules of 11.5% is comparable to other studies, which ranges from 5-15%, depending on sex, age and exposure to other risk factors.⁶

The presence of some US features had earlier been described as highly suspicious of malignancy, and they include markedly hypoechoic, a taller than wide shape, irregular margins and the presence of calcifications.^{7,8,9,10} In this study, we did not analyse individual ultrasound characteristics of nodules in predicting malignancy, instead we compared the characteristics to their respective pathology. In our study, 50% and 41.7% of our malignant nodules contained micro- and macrocalcifications respectively, and were either hypoechoic or markedly hypoechoic with percentages of 16.7% and 83.3% respectively. However, shape (taller-than-wide), central vascularity and lobulated margins were not specific to either benign or malignant thyroid nodules. Kim et al⁸ found that a solid thyroid nodule that is taller than wide

has high specificity of 93%, but however has low sensitivity for malignancy. The growth of most benign nodules have been found to stay within normal tissue planes, whereas malignant nodules grow across normal tissue planes. This appearance is thought to be due to a centrifugal predisposition in tumor growth, which does not certainly occur at a uniform rate in all dimensions.¹¹ Moon et al concluded in his study that vascularity itself or vascularity in combination with gray-scale features was not as useful as the use of suspicious gray-scale US features alone in the prediction of thyroid malignancy.¹² Lymph node assessment is most common in papillary thyroid cancer.¹³ In our study, we had one case, where there was lymphadenopathy, which was suspicious and a diagnosis of papillary thyroid carcinoma was confirmed. It is important to emphasise that no single sonographic feature should be used to differentiate between benign and malignant nodule. Instead, the overall appearance and collective features of the thyroid nodule should be considered for diagnosis.

Sensitivity and PPV are important determining factors for diagnostic tests. In our practice, the U Classification had sensitivity, specificity, positive likelihood ratio, negative likelihood ratio, positive predictive value, negative predictive value and accuracy of 100%, 91.3%, 11.5, 0.0, 60%, 100% and 92.3%, and 100%, 91.4%, 11.7, 0.0, 78.6%, 100% and 93.5%, for the non-conservative and conservative methods respectively. The sensitivity and specificity were comparable to other similar studies.^{8,14,15} Analysis was done using both conservative and non-conservative methods to prove that despite using both methods, conservative being more accurate and non-conservative being more practical, results were still comparable, as demonstrated so.

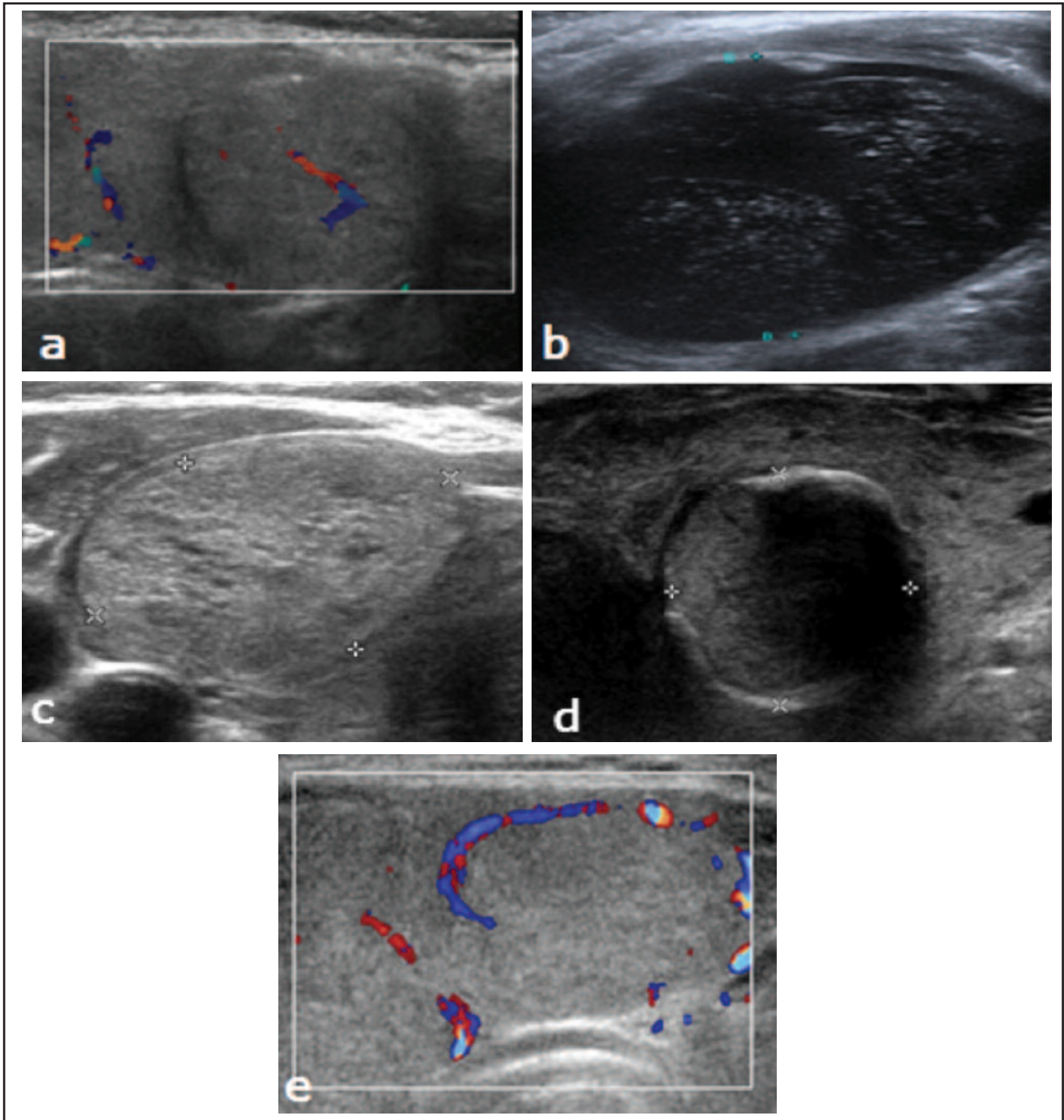


Fig. 2: U2 category, benign- (a) A benign nodule shows an ovoid isoechoic nodule with smooth margins and a regular halo. (b) A benign cystic nodule containing colloids, which are seen as hyperechoic spots with comet tail artefact. (c) A benign nodule with hypoechoic spaces resulting in a microcystic or spongiform appearance. (d) A benign nodule with rim/ eggshell calcification. Note the posterior shadowing due to the calcification. (e) A benign nodule with peripheral vascularity on colour Doppler.

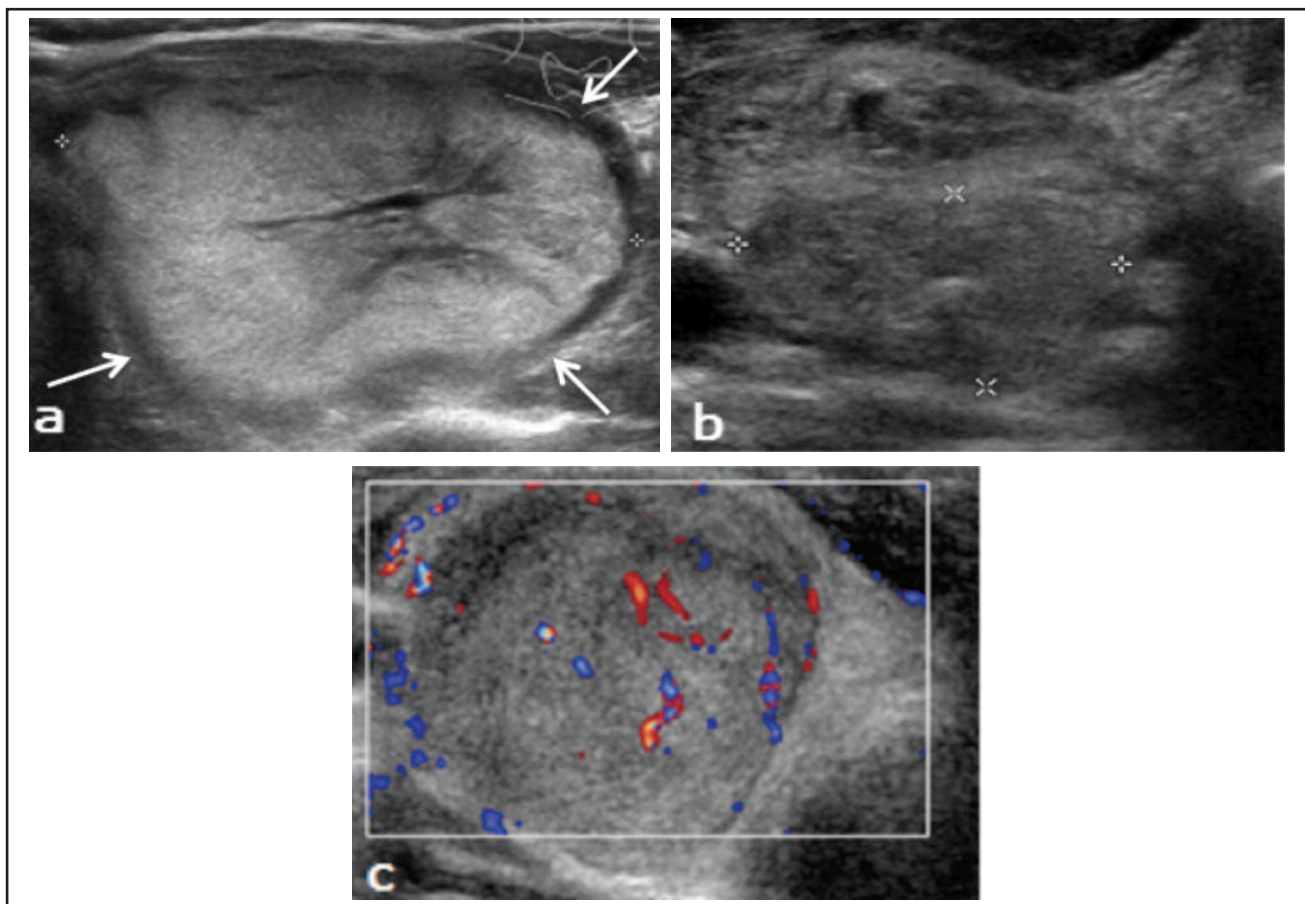


Fig. 3: U3 category, indeterminate/ equivocal- (a) A hyperechoic, predominantly solid nodule with central linear cystic component, which has regular margins and a regular halo (white arrows) is considered indeterminate regarding its risk of malignancy. (b) A nodule containing an equivocal echogenic focus is indeterminate. (c) Doppler assessment of an indeterminate nodule showing mixed vascularity, which consists of both peripheral and intra-nodular vascularity.

The lower specificity is due to eight false positive cases. The most common characteristic leading to a false positive is hypoechogenicity of the nodule, seen in all false positive cases. Two of these nodules, which were hypoechoic might have been due to the presence of rim calcification, which is a benign feature, that casts posterior shadowing, giving an apparent hypoechogenicity to the nodule. Four of the nodules had taller than wide appearance, while two had central vascularity. Two nodules had microcalcifications, one of which turned out to be a haemorrhagic cyst. Inspissated colloid calcifications in benign thyroid lesions may mimic microcalcifications in thyroid malignancies, but the former can be distinguished from malignant calcifications by the observation of ring down or reverberation artefacts.¹⁶

The overall good diagnostic yield of 44.2% translates to the ability of U Classification to rake out almost half of the thyroid nodules assessed as being either benign or malignant, with the remaining requiring FNAC to increase further diagnostic yield for diagnosis. This is a good yield and proves that we have an effective tool for selecting patients that require FNAC. Indeed, this result could improve if radiologists use the U Classification strictly. We would like to stress that the U Classification and the FNAC are complimentary procedures. The U Classification is only a tool to select high-risk nodules for FNAC.

Since the sample was retrospectively taken from the pool of patients who underwent FNAC in the Radiology Department as a result of referral from the clinicians, it is interesting to see the amount of unnecessary FNACs that have been performed in our practise. Radiologists play a role to further screen and decide if invasive procedure such as an FNAC of a benign thyroid nodule is necessary and in which according to the BTA Guideline does not even require further follow up.

Clinical Applicability

Apart from the BTA U Classification, there are other recognised guidelines for the management of thyroid nodules that includes the French Thyroid Imaging Reporting and Database System (TI-RADS) and the American Thyroid Association (ATA) Guidelines.^{7,9,17,18} The unique feature of the U Classification compared to the other guidelines is the graphic depiction of each classification, making it clear and easy to use and apply. The BTA Guidelines is a qualitative form of thyroid nodule risk stratification, whereas the TIRADS and ATA Guidelines are both quantitative. Efforts should be made to unify these different risk stratification systems practised throughout the world, and test the merged system in multi-centre prospective studies.

Application of the U Classification and subsequently adherence to the BTA Guidelines can potentially provide a

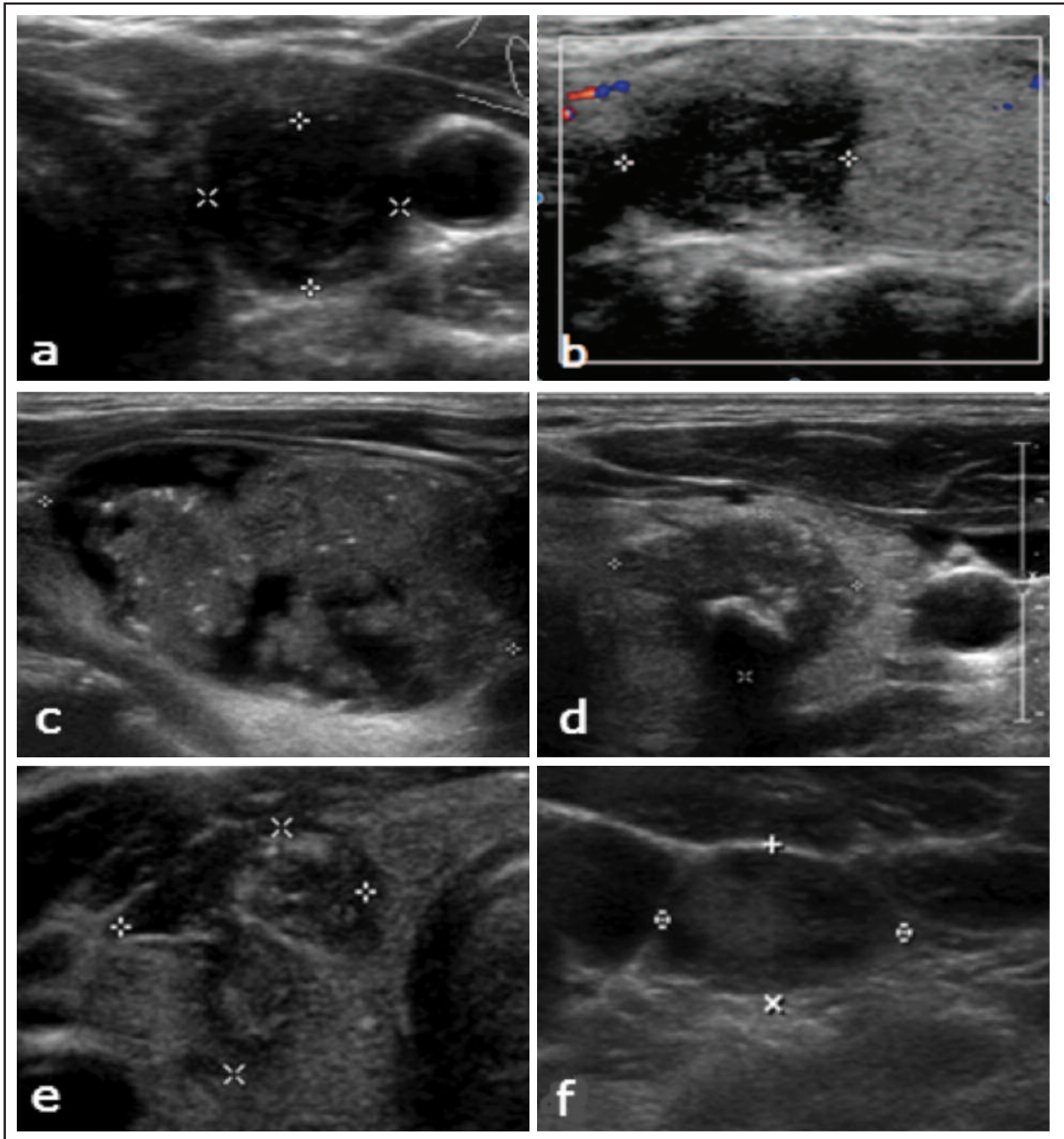


Fig. 4: U4 category, suspicious for malignancy and U5 category malignant- (a) A markedly hypoechoic solid nodule, with echogenicity lower than both thyroid tissue and strap muscle, (b) with irregular/ lobulated margins, suspicious of malignancy. FNAC showed a malignant papillary carcinoma. (c) A hypoechoic nodule with microcalcifications within shows malignant features. HPE confirmed a papillary carcinoma. (d) A hypoechoic nodule, which has a single coarse globular calcification and an irregular contour suggestive of malignant features. FNAC confirmed medullary thyroid carcinoma. (e) A hypoechoic nodule that is taller than wide is considered to be malignant. HPE revealed a papillary carcinoma (f) An abnormal lymph node with a malignant feature- enlarged, with loss of fatty hilum. An abnormal lymph node would result in a U5 category despite any benign features of the thyroid nodule.

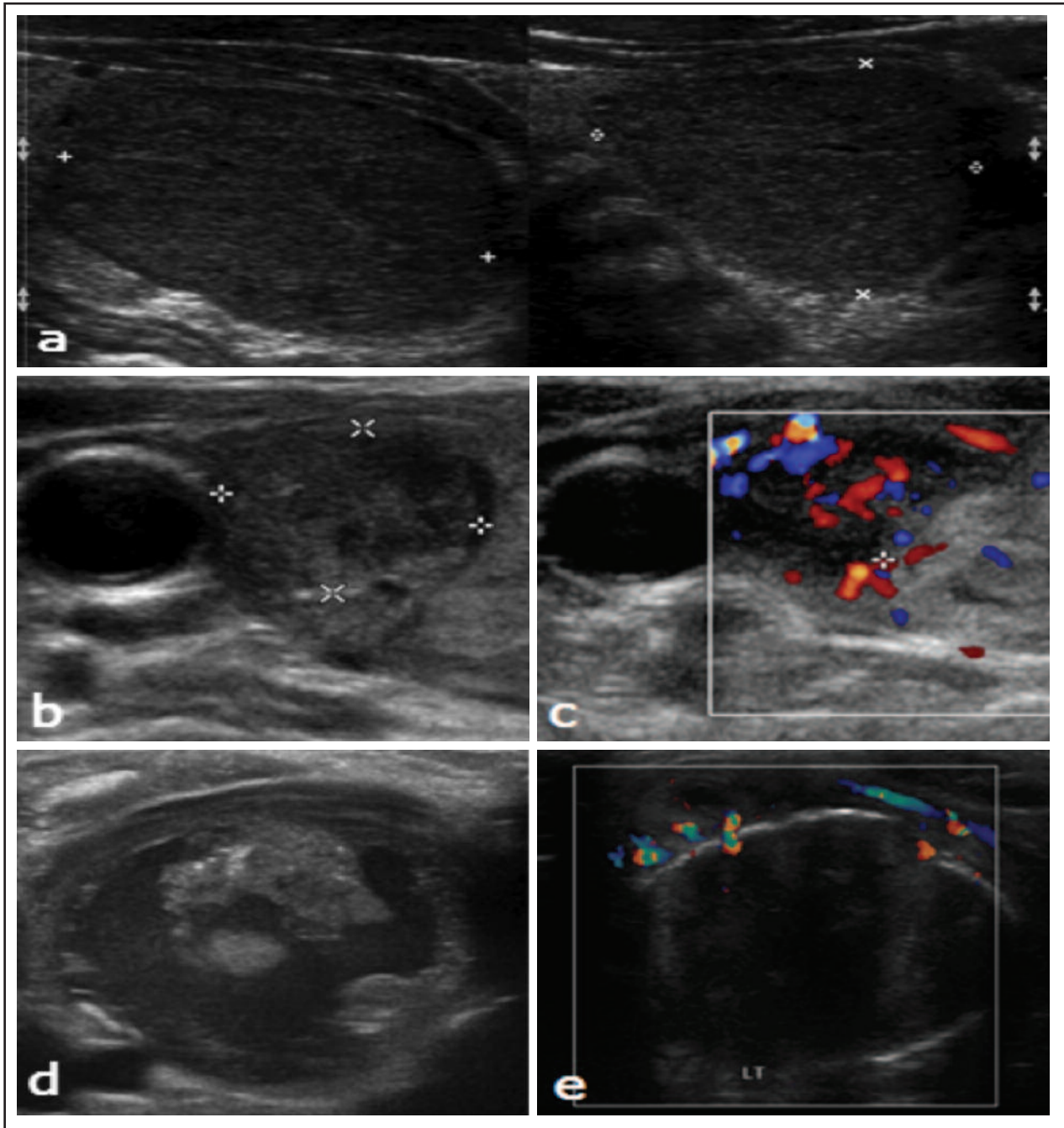


Fig. 5: False positive cases: (a) A hypoechoic solid nodule designated as suspicious for malignancy- U4 category. FNAC however was benign. (b and c) A hypoechoic solid nodule with central vascularity, designated as suspicious for malignancy- U4. FNAC however was benign, which may represent colloid nodule. (d) Nodule with microcalcifications, suspicious of malignancy. HPE turned out to be a hemorrhagic thyroid cyst. (e) Hypoechoic solid nodule with interrupted rim calcification suspicious of malignancy. HPE showed nodular hyperplasia with degenerative changes.

huge financial benefit to the healthcare system, largely achieved by a reduction in the number of unnecessary FNAC. On the other hand, for U4-U5 category, there is also role to expedite the necessary management.

It is important that radiologists, radiology trainees, endocrinologists, surgeons and sonographers understand the rationale of using and applying the U Classification of the BTA Guidelines and that the appropriate personnel are trained and competent to perform thyroid US as well as able to carry out FNAC if necessary.

Future considerations

Elastography is a sonographic feature which is not currently incorporated into the U Classification. It can be used as a supplementary tool particularly in indeterminate cases (U3 or U2/U3) and can potentially help to decide if FNAC is required or otherwise, depending on whether the nodule is elastic or stiff, respectively.^{19,20} With the increased availability and options for elastography in many US machines, it is likely that this tool will become utilized more widely. However, its full potential is still vague given that many trials have reported different results and one need to be aware of its limitations, such as its inability to be used for nodules which are cystic or significantly calcified.¹⁹

We hope to propose that the U Classification of the BTA Guidelines to be used and applied into the clinical practices across the institutions and hospitals in the country.

CONCLUSION

In summary, U Classification system proposed by BTA Guidelines is useful in diagnosing thyroid nodules for malignancy. It allows for better selection of nodules to be subjected to FNAC, avoiding unnecessary procedures. In addition, the use of a single standardized guideline in this instance the U Classification will help radiologists, sonographers and clinicians to have the same understanding of the thyroid nodule and can benefit and improve the management with cost effective follow-up and outcome.

ACKNOWLEDGEMENT

The authors wish to thank the Head of Department, lecturers, trainees and staff of the Radiology Department of UKMMC for supporting this study throughout its course. To Dr Husyairi Harunarashid from the Center for Research in Emergency Medicine (CREM) from Emergency Department UKMMC, who helped in the planning and statistics of this study, our wholehearted gratitude.

REFERENCES

1. Frates MC, Benson CB, Charboneau JW, Cibas ES, Clark OH, Coleman BG et al. Management of thyroid nodules detected at US: Society of Radiologists in Ultrasound consensus statement. *Radiology* 2005; 237: 794-800.
2. Kwak JY, Han KH, Yoon JH, Moon HJ, Son EJ, Park SH et al. Thyroid imaging reporting and data system for US features of nodules: a step in establishing better stratification of cancer risk. *Radiology* 2011; 260(3): 892-9.
3. Malaysian Cancer Statistics- Data and Figure Peninsular Malaysia 2006 National Cancer Registry.
4. Moon WJ, Jung SL, Lee JH, Na DG, Baek JH, Lee YH et al. Benign and malignant thyroid nodules: US differentiation-multicenter retrospective study. *Radiology* 2008; 247(3): 762-770.
5. Perros P, Boelaert K, Colley S, Evans C, Evans RM, Gerrard Ba G et al. Guidelines for the management of thyroid cancer. *Clin Endocrinol (Oxf)* 2014 Jul; 81 Suppl 1: 1-122.
6. Remonti LR, Kramer CK, Leitão CB, Pinto LC, Gross JL. Thyroid ultrasound features and risk of carcinoma: a systematic review and meta-analysis of observational studies. *Thyroid* 2015; 25(5): 538-50.
7. Kwak JW, Han KH, Yoon JH, Moon JH, Son EJ, Park SH et al. Thyroid Imaging Reporting and Data System for ultrasound features of nodules: A step in establishing better stratification of cancer risk. *Radiology* 2011; 260(3): 892-99.
8. Kim EK, Park CS, Chung WY, Oh KK, Kim DI, Lee JT et al. New sonographic criteria for recommending fine-needle aspiration biopsy of nonpalpable solid nodules of the thyroid. *AJR Am J Roentgenol* 2002; 178(3): 687-691.
9. Russ G, Bigorgne C, Royer B, Rouxel A, Bienvenu-Perrard M. The Thyroid Imaging Reporting and Data System (TIRADS) for ultrasound of the thyroid. *J Radiol* 2011 Jul-Aug; 92 (7-8): 701-13.
10. Hong YJ, Son EJ, Kim EK, Kwak JY, Hong SW, Chang HS. Positive predictive values of sonographic features of solid thyroid nodule. *Clin Imaging* 2010 Mar-Apr; 34(2): 127-33.
11. Hoang JK, Lee WK, Lee M, Johnson D, Farrell S. US features of thyroid malignancy: pearls and pitfalls. *RadioGraphics* 2007; 27: 847-865.
12. Moon HJ, Kwak JY, Kim MJ, Son EJ, Kim EK. Can vascularity at power Doppler US help predict thyroid malignancy? *Radiology* 2010; 255 (1): 260-69.
13. Xie C, Cox P, Taylor N, LaPorte S. Ultrasonography of thyroid nodules: a pictorial review. *Insights Imaging* 2016 Feb; 7(1): 77-86.
14. Lingam RK, Qarib MH, Tolley NS. Evaluating thyroid nodules: predicting and selecting malignant nodules for fine-needle aspiration (FNA) cytology. *Insights Imaging* 2013 Oct; 4(5): 617-24.
15. Lee YH, Kim DW, In HS, Park JS, Kim SH, Eom JW et al. Differentiation between benign and malignant solid thyroid nodules using an US classification system. *Korean J Radiol* 2011; 12(5): 559-67.
16. Jun P, Chow LC, Jeffrey RB. The sonographic features of papillary thyroid carcinomas: pictorial essay. *Ultrasound Q* 2005; 21(1): 39-45.
17. Cooper DS, Doherty GM, Haugen BR, Kloos RT, Lee SL, Mandel SJ et al. Revised American Thyroid Association management guidelines for patients with thyroid nodules and differentiated thyroid cancer. *Thyroid* 2009; 19(11): 1167-214.
18. Kim MJ, Kim EK, Park SI, Kim BM, Kwak JY, Kim SJ et al. US-guided fine-needle aspiration of thyroid nodules: indications, techniques, results. *Radiographics* 2008; 28(7): 1869-87.
19. Rago T, Santini F, Scutari M, Pinchera A, Vitti P. Elastography: new developments in ultrasound for predicting malignancy in thyroid nodules. *J Clin Endocrinol Metab* 2007; 92(8): 2917-22.
20. Sebag F, Vaillant-Lombard J, Berbis J, Griset V, Henry JF, Petit P et al. Shear wave elastography: a new ultrasound imaging mode for the differential diagnosis of benign and malignant thyroid nodules. *J Clin Endocrinol Metab* 2010; 95(12): 5281-8.