

Calcifying Fibrous Tumor of the Jejunum in a 27-year-old Primigravid: A Case Report*

Marvin Masalunga¹ and Jose Carnate Jr.²

¹Department of Laboratories, Philippine General Hospital, University of the Philippines – Manila

²Department of Pathology, College of Medicine, University of the Philippines – Manila

ABSTRACT

The most common mesenchymal tumors of the gastrointestinal tract are gastrointestinal stromal tumors (GIST) and smooth muscle neoplasms; however, other soft tissue tumors may also present in the intestines and cause diagnostic dilemmas. We report the case of a 27-year old primigravid, with no known complications, who underwent cesarean section for cephalopelvic disproportion. Intraoperatively, a well-demarcated, solid mass measuring 1.5 x 1.0 x 0.7 cm was noted at the jejunum. The patient underwent segmental resection of the mass. Microscopic examination of the mass reveals a non-encapsulated, solid mass composed of bland spindle cells and dense, hyalinized collagen in whorls and bundles. Dystrophic calcifications and a lymphoplasmacytic inflammatory infiltrate are seen within the collagen bundles. Immunohistochemical staining with desmin, CD117, and DOG-1 was done, which are all negative. The case was signed out as calcifying fibrous tumor (CFT). Inclusion of CFTs in the differential diagnoses for mesenchymal tumors of the gastrointestinal tract is important, as these neoplasms are benign and have an excellent prognosis.

Key words: Calcifying fibrous tumor, jejunum, neoplasms, fibrous tissue

ISSN 2507-8364 (Online)

Printed in the Philippines.

Copyright© 2020 by the PJP.

Received: 17 January 2020.

Accepted: 18 February 2020.

Published online first: 25 March 2020.

<https://doi.org/10.21141/PJP.2020.05>

Corresponding author: Marvin C. Masalunga, MD, MPM

E-mail: mcmasalunga@gmail.com

INTRODUCTION

Mesenchymal tumors, both benign and malignant, can arise at virtually any site. In the digestive system, benign soft tissue neoplasms are more common than soft tissue sarcomas, with an incidence of at least 100-fold higher than the latter.^{1,2} Common benign mesenchymal tumors of the gastrointestinal tract include small, clinically occult gastrointestinal stromal tumors (GIST), lipomas, leiomyomas, vascular lesions, nerve sheath tumors, and tumors of myofibroblastic origin.¹

A majority of these mesenchymal tumors arise spontaneously; however, a definitive etiology can be readily established in some cases, including viruses (e.g. Kaposi sarcoma), prior surgeries (e.g. angiosarcoma), genetic defects (e.g. desmoid fibromatosis), or as part of inherited syndromes (e.g. chondroid and vascular tumors in Maffucci syndrome). Somatic genetic mutations may also play a role in the pathogenesis of mesenchymal neoplasms, but the exact mechanisms of such molecular events remain to be elucidated.¹

Clinically, mesenchymal tumors typically present as painless masses. Unless they arise in the trunk and extremities, these neoplasms may go unnoticed for a long period of time. Occasionally, patients with intra-abdominal soft tissue masses may experience non-specific symptoms, such as abdominal discomfort or pain. The unremarkable presentation of these lesions may suggest a benign course; nevertheless, deep-seated lesions should be regarded as probably malignant and must be evaluated accordingly.²



One such tumor that is clinically benign but may raise suspicion for malignancy is calcifying fibrous tumor (CFT), a low-grade, soft tissue neoplasm that can arise anywhere within the gastrointestinal tract. CFT is a well-demarcated, hypocellular tumor characterized by the presence of hyalinized collagen, dystrophic calcifications and focal inflammatory infiltrates. It is usually encountered as an incidental finding in patients undergoing endoscopy or colonoscopy. In some cases, CFTs may be discovered in open abdominal procedures. Recognizing CFTs is important because surgery is curative and its prognosis is much better than other soft tissue tumors of the gastrointestinal tract.³

This paper reports the incidental finding of a jejunal CFT in a 27-year old primigravid who underwent cesarean section.

CASE

This is the case of a 27-year-old primigravid who was admitted at the labor room of a private hospital because of regular uterine contractions. The patient carried her pregnancy to term and had an unremarkable obstetric and maternal history. Due to dystocia secondary to cephalopelvic disproportion and premature rupture of membranes, the patient was scheduled for an elective cesarean section procedure.

Intraoperatively, an ovoid, firm, solid nodule measuring 1.5 x 1.0 x 0.7 cm was palpated incidentally at the jejunum. Located at the antimesenteric side, the mass does not appear to cause any degree of luminal obstruction. After the delivery of a live baby boy, the patient underwent segmental resection of the jejunum and the specimen was submitted for routine histopathologic examination.

Gross examination of the mass revealed an intramural, unencapsulated, cream white, solid mass that appeared to be centered at the muscularis propria on cut sections. Further sections of the mass revealed no hemorrhage or soft areas that might suggest necrosis. Occasionally, the mass was gritty to cut.

The case was signed out as a spindle cell neoplasm, with considerations of: 1) gastrointestinal stromal tumor and 2) leiomyoma. The case was referred to our institution for review.

MICROSCOPIC DESCRIPTION

There is a well-circumscribed, unencapsulated, paucicellular lesion located within the muscularis propria. The tumor distends the serosa and does not invade the mucosa and submucosa (Figure 1). Scanning the lesion reveals dense hyalinized collagenous tissues arranged in bundles and whorls, with scattered foci of dystrophic calcification (Figure 2). High-power views of the lesion reveal bland spindle cells with scant cytoplasm and occasional, scattered lymphoplasmacytic infiltrates (Figure 3). No prominent blood vessels are seen within the lesion. Myxoid changes are present in some areas; however, there is no necrosis, mitoses, atypia, and pleomorphism.

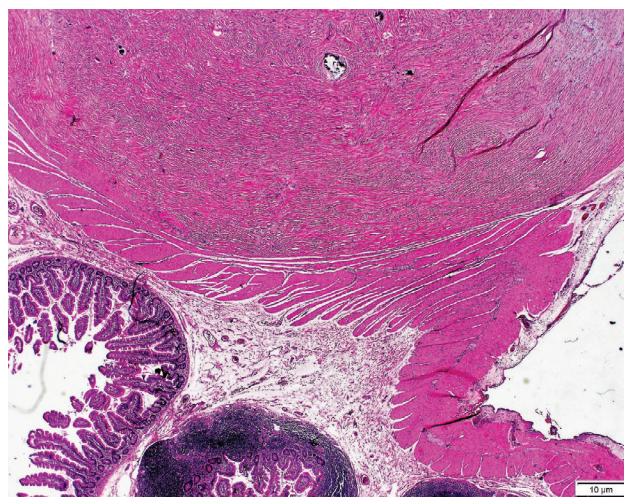


Figure 1. A well-demarcated, unencapsulated, hypocellular mass, composed of thick bundles of collagen and with scattered dystrophic calcifications, is seen distending the intestinal wall (H & E, 40X).

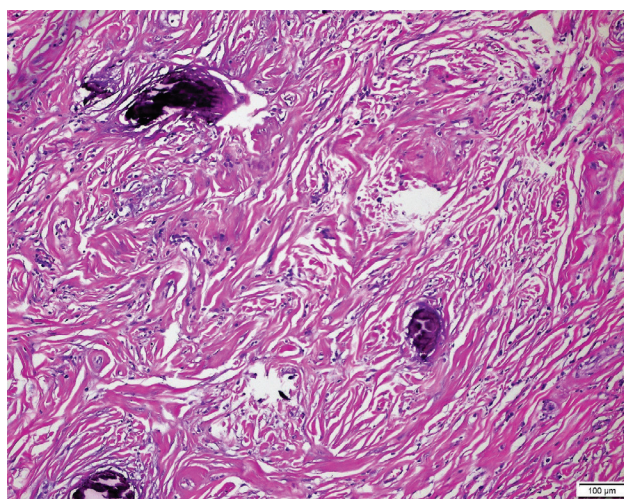


Figure 2. Dystrophic calcifications are a characteristic feature of the lesion (H & E, 100X).

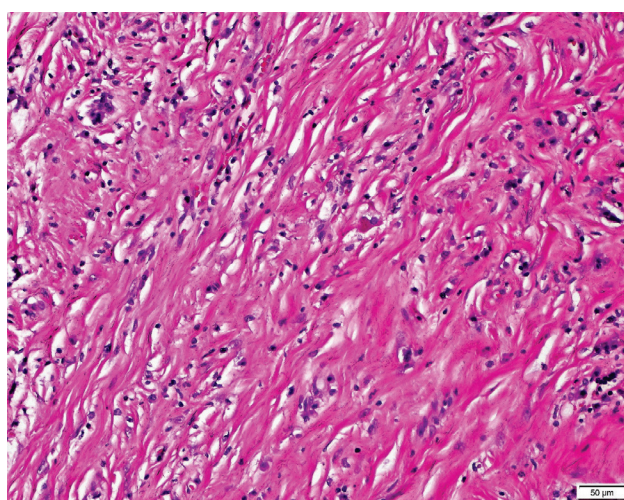


Figure 3. Hyalinized collagen are arranged in bundles, with bland, spindle cells and infiltrating inflammatory cells, composed mostly of lymphocytes and plasma cells (H & E, 400X).

Immunohistochemical stains for desmin, CD117, and DOG-1 were done (Figure 4). Both DOG-1 and desmin are negative in the spindle cells. The spindle cells are also negative for CD117, with only sporadic mast cells taking up the stain; thus, the initial considerations of GIST and leiomyoma are ruled out.

Given these microscopic findings, in correlation with the patient's unremarkable clinical and obstetric history, the case was signed out as calcifying fibrous tumor (CFT) of the jejunum.

DISCUSSION

The vast majority of soft tissue tumors in the digestive system (95%) are either GISTs or tumors derived from smooth muscle, i.e. leiomyoma or leiomyosarcoma. The usual dilemma presented by the more uncommon mesenchymal neoplasms is that they may be easily confused with GIST.⁴ Calcifying fibrous tumor (CFT) is one of the other tumor types that may be encountered in the gastrointestinal tract, albeit occurring at a lower incidence. It has a predilection for children and young adults, with a mean age of 34 years for patients with abdominal CFTs.^{5,6}

Also known by the term “childhood fibrous tumor with psammoma bodies” and “calcifying fibrous pseudotumor,” CFTs were initially considered to represent a reactive process secondary to abnormal healing. In the consensus classification document by the World Health Organization in 2002, this entity was given the name calcifying fibrous tumor. CFTs have been reported in various anatomic sites, including the peritoneum, mediastinum, lungs, adrenal glands, etc.⁴ In the review by Chorti et al., less than 50 CFTs occurring in the gastrointestinal tract have been reported in the English literature, and are more common in the stomach than in the intestines.⁷

Clinically, most CFTs of the gastrointestinal tract are incidental findings, as seen in this case. If symptoms are present, they are usually non-specific, such as abdominal discomfort and bowel obstruction. CFTs may also result in complications that require more aggressive surgical management, e.g. ileocolic intussusception.^{7,8} Radiologic studies are non-specific and may reveal a well-defined lesion with microcalcifications on both ultrasound and CT scan.^{6,7}

Pathologic examination remains the most essential tool in the diagnosis of CFT. Grossly, CFTs present as a solitary, well-circumscribed, unencapsulated mass that has a wide range of sizes (up to 25 cm in some case reports). In the gastrointestinal tract, CFTs are reported to arise in the submucosal, intramural, or subserosal layers. Microscopic features include the presence of myofibroblastic spindle cells; paucicellular, hyalinized collagen in lamellar bundles and whorls; psammomatous or dystrophic calcifications; and mononuclear inflammatory infiltrates, which include lymphocytes, plasma cells, mast cells, and polymorphonuclear leukocytes.⁷

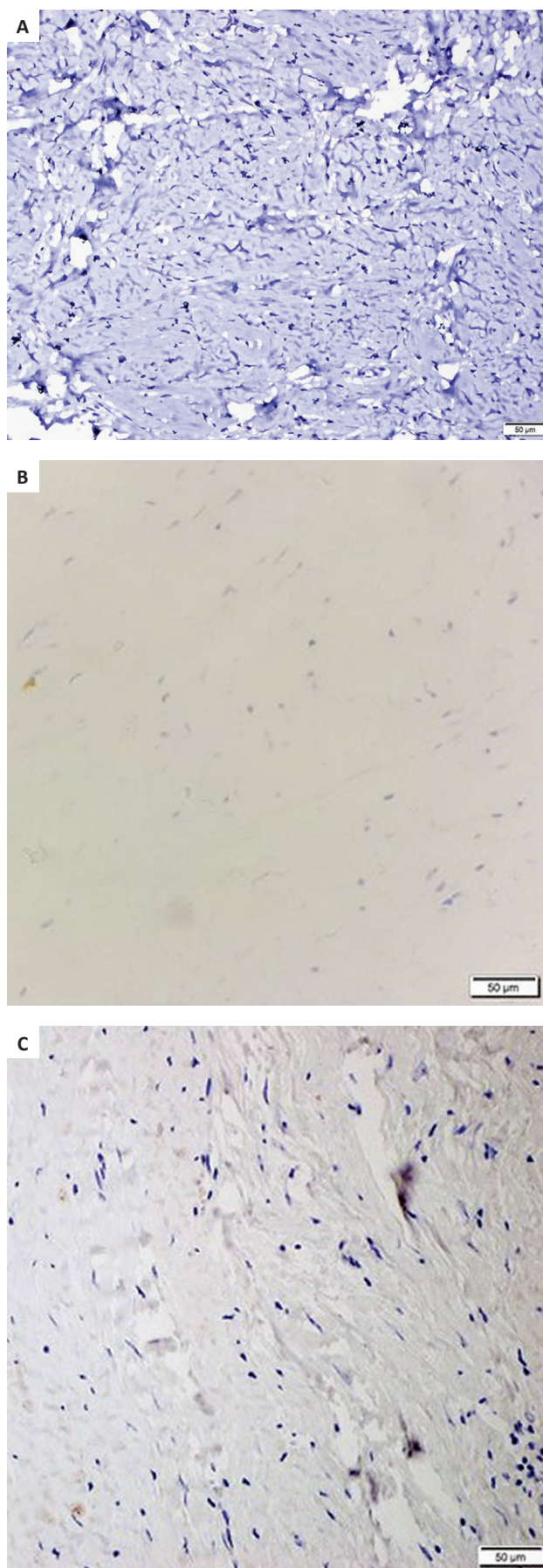


Figure 4. The lesion is negative for DOG-1 (A), Desmin (B), and CD117 (C) (IHC, 100X).

The differential diagnoses for CFT include GISTs, leiomyoma, and other soft tissue tumors such as schwannomas and desmoid tumors. Due to its highly collagenized nature, other entities that may also be considered include inflammatory myofibroblastic tumor, desmoid fibromatosis, and solitary fibrous tumor. In particular, inflammatory myofibroblastic tumor (IMT) shares several histopathologic features with CFT, including bland spindle cells, hyalinized stroma, whorling architecture, fibrosis, calcifications, and an inflammatory infiltrate. However, unlike CFT, there may be some moderate pleomorphism in IMT, with myoid cells showing prominent nucleoli. The spindle cells in IMT are also plump, in contrast to the spindle cells of CFT which have scant, pale cytoplasm. IMT also has a more prominent lymphoplasmacytic infiltrate, and appears much more cellular than CFT. One study hypothesized that CFT might be the late regressive stage of IMT due to the similar histologic features and overlapping methylation patterns of the two entities; however, ALK rearrangement, which is a hallmark of IMT, is not seen in CFT.⁹ Differentiating CFT from IMT is important because the former is benign, while the latter can persist locally, invade adjacent structures and, rarely, metastasize.¹⁰

Desmoid fibromatosis, another tumor that presents with zones of hyalinization and a myxoid background, must also be ruled out. This lesion arises more commonly in the mesentery, and is characterized microscopically by the presence of long sweeping fascicles of slender spindle or stellate cells and prominent, small vessels. Unlike CFT, desmoid fibromatosis is an infiltrative lesion that has a minimal inflammatory component. On immunohistochemistry, it is positive for actin, and at least 80% of tumors present with nuclear staining of β -catenin.^{1,10} Desmoid fibromatosis is known to recur, and infrequently may undergo spontaneous regression.¹

Solitary fibrous tumor (SFT), which is more common in adults, may present with striking hyalinization of its stroma and some degree of myxoid change, therefore mimicking CFT. However, SFTs have prominent thin-walled, dilated, and branching staghorn-shaped blood vessels, which may also present with perivascular hyalinization. CFTs, as demonstrated in this case, do not present with a prominent vascular network.¹

Therefore, routine evaluation of microscopic features on hematoxylin and eosin (H and E) slides may suffice to establish the diagnosis of CFT; however, immunochemical stains may prove helpful in resolving some cases. CFTs express vimentin, Factor XIIIa, and occasionally, CD34 and CD68. These tumors are negative for other commonly used markers such as CD117, desmin, S100, ALK-1, CD31, CD99, Bcl-2, β -catenin, and STAT6.⁷

Local excision is curative for CFTs, and the prognosis is excellent. CFTs do not have any metastatic potential, and, specifically for CFTs of the gastrointestinal tract, no cases of recurrence have been reported.^{4,7}

CONCLUSION

Calcifying fibrous tumors are solitary, non-encapsulated, well-demarcated masses that are characterized microscopically by bundles of hyalinized collagen with microcalcifications and lymphoplasmacytic infiltrates. Although rare, they should be considered in the differential diagnoses of gastrointestinal masses, as the surgical management is more conservative and the prognosis is excellent.

ACKNOWLEDGMENTS

The authors would like to thank Dr. Jenny Maureen L. Atun for her assistance in signing out the case.

ETHICAL CONSIDERATION

Patient consent was obtained before submission of the manuscript.

STATEMENT OF AUTHORSHIP

All authors certified fulfillment of ICMJE authorship criteria.

AUTHOR DISCLOSURE

The authors declared no conflict of interest.

FUNDING SOURCE

None.

REFERENCES

1. WHO Classification of Tumours Editorial Board. Digestive system tumours, 5th ed. Lyon France: International Agency for Research on Cancer; 2019.
2. Fletcher CDM, Bridge JA, Hogendoorn PCW, Mertens F. WHO Classification of tumours of soft tissue and bone, 4th ed. Lyon, France: International Agency for Research on Cancer; 2013.
3. Kim J, Ryu S, Kim YJ. Endoscopic submucosal dissection of a colonic calcifying fibrous tumor. *Clin Endosc*. 2020. PMID: 31958942. <https://doi.org/10.5946/ce.2019.138>.
4. Rodríguez-Zarco E, Vallejo-Benítez A, de Soto-Cardenal B, Mora-Cabezas M, Pereira-Gallardo S. Calcifying fibrous tumor of the small bowel [Tumor fibroso calcificante de intestino delgado]. *Cir Esp*. 2016; 94(4):245–7. <https://doi.org/10.1016/j.cireng.2016.03.001>
5. Emanuel P, Qin L, Harpaz N. Calcifying fibrous tumor of small intestine. *Ann Diagn Pathol*. 2008;12(2): 138-41. PMID: 18325476. <https://doi.org/10.1016/j.anndiagnpath.2006.08.006>.
6. Wesecki M, Radziuk D, Niemiec S, Waniczek D, Lorenc Z. Calcifying fibrous tumor of the small bowel mesentery in a 27-year old male patient – a case report. *Pol Przegl Chir*. 2014;86(9):436-9. PMID: 25527808. <https://doi.org/10.2478/pjs-2014-0078>.

7. Chorti A, Papavramidis TS, Michalopoulos A. Calcifying fibrous tumor: review of 157 patients reported in international literature. *Medicine (Baltimore)*. 2016;95(20): e3690. PMID: 27196478. PMID: PMC4902420. <https://doi.org/10.1097/MD.0000000000003690>.
8. Sotiriou S, Papavramidis T, Hytioglou P. Calcifying fibrous tumor of small bowel causing intussusception. *Clin Gastroenterol Hepatol*. 2019; 17(8):e95. <https://doi.org/10.1016/j.cgh.2018.06.039>.
9. Tomassen T, Koelsche C, de Leng WWJ, et al. Calcifying fibrous tumor and inflammatory myofibroblastic tumor are epigenetically related: a comparative genome-wide methylation study. *Ann Diagn Pathol*. 2019; 41: 102-5. <https://doi.org/10.1016/j.anndiagpath.2019.05.013>.
10. Voltaggio L, Montgomery EA. Gastrointestinal tract spindle cell lesions—just like real estate, it's all about location. *Mod Pathol*. 2015;28 (Suppl 1): S47–66. PMID: 25560599. <https://doi.org/10.1038/modpathol.2014.126>.

Disclaimer: This journal is **OPEN ACCESS**, providing immediate access to its content on the principle that making research freely available to the public supports a greater global exchange of knowledge. As a requirement for submission to the PJP, all authors have accomplished an **AUTHOR FORM**, which declares that the ICMJE criteria for authorship have been met by each author listed, that the article represents original material, has not been published, accepted for publication in other journals, or concurrently submitted to other journals, and that all funding and conflicts of interest have been declared. Consent forms have been secured for the publication of information about patients or cases; otherwise, authors have declared that all means have been exhausted for securing consent.

*Publish in the new PJP.
Visit our website:
<http://philippinejournalofpathology.org>*