

CASE REPORT

Occult primary breast carcinoma presented as an axillary mass: A Diagnostic Challenge

Yin Ping WONG¹, Geok Chin TAN¹, Rohaizak MUHAMMAD², Pathmanathan RAJADURAI³

Department of ¹Pathology and ²Surgery, Faculty of Medicine, Universiti Kebangsaan Malaysia Medical Centre, Jalan Yaacob Latiff, Bandar Tun Razak, 56000 Cheras, Kuala Lumpur, Malaysia, and ³Department of Pathology, Subang Jaya Medical Centre, Subang Jaya, Selangor, Malaysia.

Abstract

Introduction: Occult primary breast carcinoma (OBC) manifesting as axillary nodal metastasis without an identifiable breast primary is exceptionally rare. It continues to pose a diagnostic challenge to pathologists. Here, we report a case of OBC with emphasis on the usefulness of immunohistochemistry to determine the primary site of tumour. **Case Report:** A 58-year-old female presented with a 3-cm painless right axillary mass. Extensive radiological investigations that include mammography, ultrasonography of the breasts and positron emission tomography (PET) scan failed to conclude the primary site of the tumour. Histological examination of the lymph node revealed loosely cohesive sheets of poorly differentiated malignant cells, without discernible glandular or squamous differentiation. Immunohistochemically, the malignant cells exhibited diffuse immunoreactivity toward pan-cytokeratin and CK7, while leukocyte common antigen, S100 and CK20 were negative. A second panel of immunomarkers was carried out. The malignant cells expressed breast-specific markers (GATA-3, GCDFP-15 and mammaglobin), and were negative for ER, PR and TTF-1 immunohistochemistry. A diagnosis of OBC was rendered. **Discussion:** Breast primary must always be considered in the differential diagnosis in patients with sole presentation of axillary lymphadenopathy. The breast-specific immunomarkers play a pivotal role in the diagnosis of ER, PR-negative occult breast cancer.

Keywords: Occult breast cancer, axillary metastasis, diagnostic challenge, immunohistochemistry

INTRODUCTION

Occult primary breast carcinoma (OBC) is defined as carcinoma of unknown primary (CUP), consistent with metastatic carcinoma of breast origin without clinical or radiological evidence of a definitive breast primary. OBC is exceedingly rare, accounts for less than 1.0% of all newly diagnosed breast carcinoma with axillary lymph node being the most common site of involvement.¹ With the emerging advances in imaging modalities including magnetic resonance imaging (MRI), positron emission tomography (PET) and nuclear medicine techniques, the incidence of these hidden “occult” primary breast lesions are gradually decline.

Breast primary must always be considered in the differential diagnosis in patients with sole presentation of axillary lymphadenopathy. The other possibilities include lymphoma, melanoma

and carcinomas of the lung, gastrointestinal tract, as well as head and neck tumours.² A judicious use of immunohistochemistry panel is essential in the workup of this occult malignancy. Here, we report a case of OBC with emphasis on the usefulness of immunohistochemistry to determine the primary site of tumour.

CASE REPORT

The patient is a 58-year-old female presented to our hospital with an incidental finding of a right axillary mass lesion. Otherwise, there were no associated constitutional symptoms such as fever, night sweats or significant weight loss. Physical examination revealed a firm, painless mass lesion in the right axillary region measuring 30 mm in diameter. No lymphadenopathy was detected in the left axilla nor there was mass lesion found in the breasts.

Address for correspondence: Yin Ping Wong, Department of Pathology, Faculty of Medicine, Universiti Kebangsaan Malaysia Medical Centre, Jalan Yaacob Latif, Bandar Tun Razak, 56000 Cheras, Kuala Lumpur, Malaysia. Tel: +603-9145 5364. Fax: +603-9145 6676. Email: ypwong@ppukm.ukm.edu.my

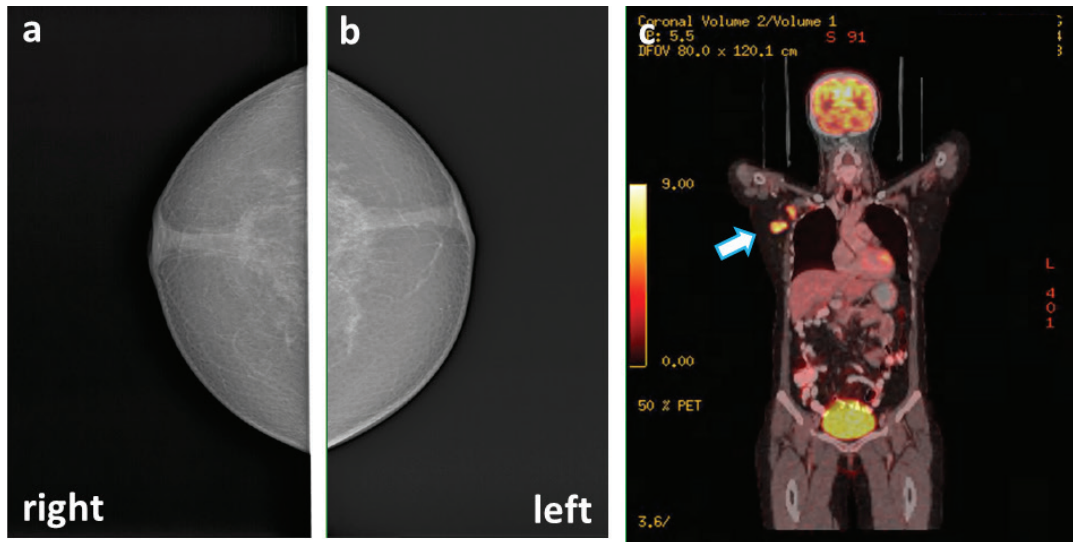


FIG. 1 **Radiological features of OBC.** (a & b) Mammogram of both breasts shows no perceivable lesion. (c) PET scan revealed multiple hypermetabolic lymph nodes (arrow). No active lesion is detected elsewhere.

No discernible mass was appreciated elsewhere. Ultrasound evaluation of the right axilla identified an enlarged lymph node exhibiting thickened cortex with mixed vascularity (hilar and peripheral vascularity), suspicious of metastatic disease. Comprehensive radiological investigations which include mammogram, ultrasonography of the breast and positron emission tomography (PET) scan failed to determine the primary site of the tumour (Fig. 1). A core biopsy of the right axillary lymph node was subsequently performed.

Histological examination of the right axillary lymph node revealed partial effacement of nodal architecture infiltrated by loose cohesive sheets

of malignant cells, without discernible glandular or squamous differentiation. The malignant cells were large and pleomorphic, exhibited vesicular nuclei and prominent nucleoli with basophilic cytoplasm. Mitoses were readily seen (Fig. 2). Immunohistochemically, the malignant cells demonstrated pan-cytokeratin (CK) and CK7 diffuse immunopositivity. Leukocyte common antigen (LCA), CK20 and S100 were negative, excluding the possibility of malignant lymphoma or metastatic melanoma. The CK7+/CK20- immunostaining pattern of the malignant cells triggered a second panel of immunomarkers performed including breast specific immunomarkers (GATA-3, gross cystic

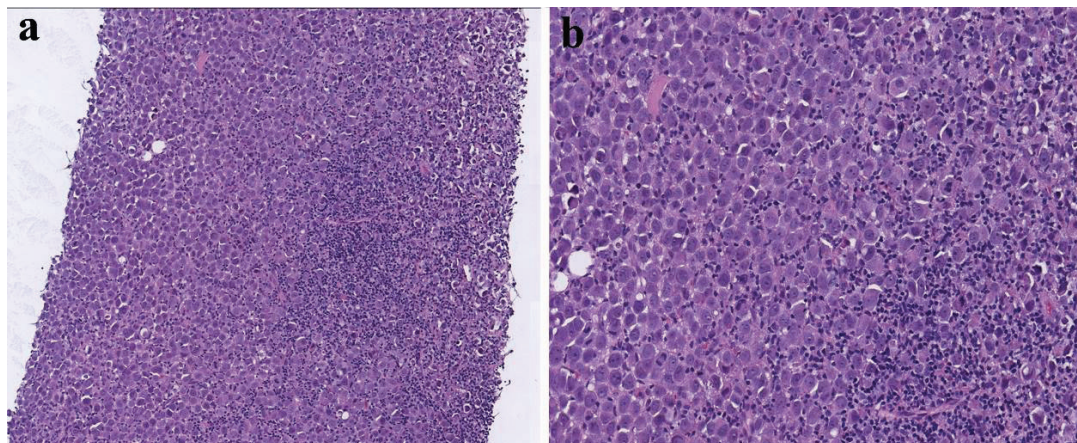


FIG. 2 **Histological features of OBC.** (a) Partial effacement of nodal architecture replaced by sheets of malignant cells (H&E x100). (b) The malignant cells exhibit large pleomorphic vesicular nuclei and some with prominent nucleoli (H&E, x200).

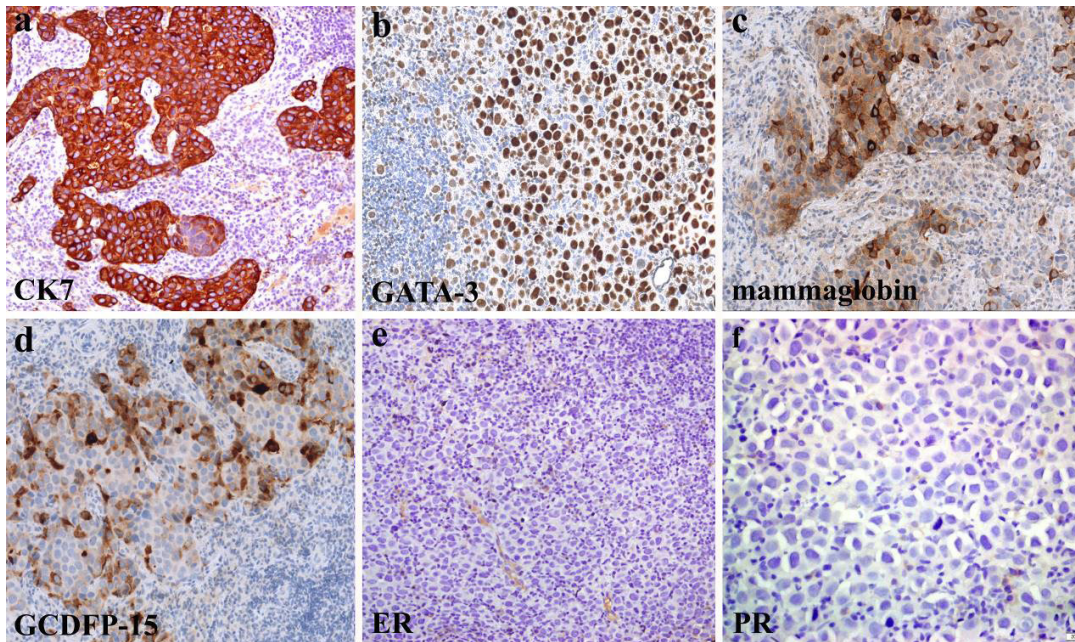


FIG. 3 **Immunohistochemical features of OBC.** The malignant cells are immunoreactive for (a) CK7 (x200) and breast-specific immunomarkers including (b) GATA-3 (x200), (c) mammaglobin (x200) and (d) GCDFP-15 (x200). They are negative for (e) oestrogen receptor (x200) and (f) progesterone receptor (x400).

disease fluid protein-15 (GCDFP-15) and mammaglobin), thyroid transcription factor-1 (TTF-1), oestrogen (ER) and progesterone receptors (PR). The malignant cells expressed GATA-3, GCDFP-15 and mammaglobin, and were negative for TTF-1, ER and PR immunohistochemistry (Fig. 3). A diagnosis of OBC was rendered. Neoadjuvant chemotherapy prior to axillary lymph node clearance and whole breast radiotherapy were offered to reduce the risk of locoregional relapse/recurrence.

DISCUSSION

Breast malignancy presenting as axillary nodal metastasis without clinical and routine imaging discernible primary breast masses is uncommon. It is categorised as $T_0N_{1-2}M_0$ stage II-III according to the 8th edition of American Joint Committee on Cancer (AJCC) staging system. OBC was first reported by Halsted *et al.* (1970), describing three patients who presented initially with cancerous axillary masses that became clinically noticeable in the breast years later.³ The actual time interval between the initial clinical presentations of an OBC and the discovery of a primary in the breast remains unclear due to lack of data; however, it was estimated to be up to five years duration.⁴

Axillary nodal metastasis without a clinical

discernible primary lesion is diagnostically challenging. Malignancies that notoriously metastasize to axillary lymph node other than breast carcinomas include lymphomas, melanomas, carcinomas of lung, thyroid, gastrointestinal tract and ovaries.⁵ Adenocarcinoma or poorly differentiated carcinoma accounts for more than 90% of isolated axillary nodal metastasis cases, with breast cancer being the most frequent culprit which warrants a detailed investigation.⁶ A thorough clinical history and systematic physical examination are fundamental first steps in these patients to determine possible primary sites, with particular attention directed to examination of the breast, skin, thyroid, lung, abdomen and pelvis.⁵

Further diagnostic imaging such as chest x-ray, mammography, breast ultrasonography, computed tomography of thorax, abdomen and pelvis as well as appropriate screening blood workup may usually be sufficient to locate primary sites of cancer.⁵ Exhaustive invasive procedures; however, are not indicated. Adversely, a few published data revealed that extensive investigations could potentially yielded high false positive results leading to unnecessary treatment.⁵

Breast MRI with paramagnetic contrast has demonstrated to have a higher sensitivity in

locating breast lesions. Surveillance with breast MRI nonetheless is not recommended in routine breast cancer diagnosis due to its low diagnostic specificity. Breast MRI has been shown to be highly efficient in discovering “hidden” breast tumours that are failed to be revealed by conventional imaging,⁷ and hence may be indicated in diagnostically difficult cases.

Excision or core needle biopsy examination is usually performed to facilitate accurate diagnosis in patients with persistent isolated axillary lymphadenopathy suspicious for metastatic disease. Notably, carcinoma arising from accessory breast tissue needs to be first excluded before considering the diagnosis of a lymph node metastasis, to avoid unnecessary surgery. The demonstration of aberrant normal breast ducts and acini lying adjacent to cancerous tissue in the absence of background lymphoid tissue is a helpful distinguishing feature.⁸

Immunohistochemistry has become an indispensable tool in aiding classification of solid tumours and determining sites of origin for metastatic lesions. Histologically, OBC frequently exhibit morphology resembling to an adenocarcinoma or undifferentiated carcinoma, characterised by infiltrating malignant epithelial cells with variable glandular, tubular and solid architectures. As a rule of thumb, in undifferentiated neoplasms with no clear lineage as in the present case, broad spectrum antibodies against epithelial (pan-CKs), lymphoid (CD45, CD3, CD20), mesenchymal (vimentin) and melanocyte-differentiation (S100, melan-A) antigens should be performed as first line screening.⁹

Upon confirming the epithelial lineage of the metastatic lesion, a combination of CK7 and CK20 immunoreexpression profiling is hitherto a useful tool to predict the primary site of tumour. For instance, tumours with CK7+/CK20- phenotype are associated with carcinomas of the lung, breast, thyroid, kidney, pancreas and female genital tract; while a CK7-/CK20+ tumour phenotype favour a colorectal in origin. Urothelial, bladder, pancreas and gastric adenocarcinoma frequently have a CK7+/CK20+ phenotype. In the event that the malignant epithelial tumour reveals CK7-/CK20- profile, primary prostate, renal, liver or adrenal origins should be excluded.⁹ Subsequently, organ-specific immunomarkers such as breast (ER, PR), thyroid (TTF-1, thyroglobulin, PAX8), lung (TTF-1, napsin A) and ovary (WT-1, PAX8) can be used to determine the site of primary tumour.⁹

When dealing with metastatic carcinomas in the axillary lymph node, one should be aware that almost 90% of the primary lesions originate from the breast, and warrant further investigation for confirmation. As a corollary, breast-specific markers (ER, PR, GATA-3, mammaglobin and GCDFP15) should always be considered in such cases. Notably, there is a tendency to ER/PR-negative disease among OBC.¹⁰ Therefore, ER/PR immunonegativity does not preclude a probable breast origin.

GATA-binding protein-3 (GATA-3), an important transcriptional factor involved in cell proliferation and differentiation, is recently recognised as promising marker for breast carcinoma. Ni *et al.* (2018) concluded that GATA-3 showed higher sensitivity (82.5%) than mammaglobin (46.6%) and GCDFP15 (23.9%) in detecting metastatic breast cancer, with good concordance with primary tumours.¹¹ Although a positive correlation was observed between GATA-3 and ER immunoreexpression, a small subset of ER-negative cases did show GATA-3 positivity¹² hence a combination of biomarkers may be necessary to prevent misdiagnosis.

Recently, other immunomarkers have been investigated. Androgen receptor was found positive in 31% of triple negative breast cancer,¹³ while IGFBP-rP1 was expressed in 33.3% of breast cancer patients with type II diabetes mellitus.¹⁴ In addition, Kumcu *et al.* (2018) described the expression of D2-40 (Podoplanin) in cancer associated fibroblasts in 65.3% of breast cancer.¹⁵ However, due to their low percentage of expression in breast cancer, they are not suitable as breast cancer biomarkers.

CONCLUSION

Breast primary must be considered in the differential diagnosis in patients with sole presentation of axillary lymphadenopathy. The breast-specific immunomarkers play a pivotal role in the diagnosis of ER, PR-negative occult breast cancer.

Funding: None

Acknowledgement: The work was presented as poster in “Minggu Penyelidikan Perubatan dan Kesihatan ke-21” in Kuala Lumpur, Malaysia. We would like to thank all the laboratory staffs of Universiti Kebangsaan Malaysia Medical Centre for their excellent technical support.

Conflict of interest: None to declare

REFERENCES

1. Wang X. Presentation of axillary metastases from occult breast carcinoma. *Chin J Clin Oncol*. 2007; 4: 1-5.
2. Zhu YH, Luo MY, Jia Z, Guo JF. Diagnoses and therapy of occult breast cancer: A systematic review. *J Mol Biomark Diagn*. 2017; 8.
3. Halsted WS. I. The results of radical operations for the cure of carcinoma of the breast. *Ann Surg*. 1907; 46(1): 1-19.
4. Blanchard D, Farley D. Retrospective study of women presenting with axillary metastases from occult breast carcinoma. *World J Surg*. 2004; 28: 535-9.
5. Pentheroudakis G, Lazaridis G, Pavlidis N. Axillary nodal metastases from carcinoma of unknown primary (CUPAx): a systematic review of published evidence. *Breast Cancer Res Treat*. 2010; 119(1): 111.
6. Anderson SR, Scarborough CS. Axillary node metastatic carcinoma without definitive primary: a case report. *Int J Surg Case Rep*. 2016; 25: 196-8.
7. Douvetzemis SE. Management of Occult Breast Cancer with Axillary Involvement. *Hellenic Journal of Surgery*. 2018; 90(1): 33-5.
8. Fizazi K, Greco FA, Pavlidis N, *et al*. Cancers of unknown primary site: ESMO Clinical Practice Guidelines for diagnosis, treatment and follow-up. *Ann Oncol*. 2011; 22(Suppl 6): vi64-8.
9. Selves J, Long-Mira E, Mathieu MC, Rochaix P, Ilie M. Immunohistochemistry for diagnosis of metastatic carcinomas of unknown primary site. *Cancers*. 2018; 10(4): 108.
10. Ge LP, Liu XY, Xiao Y, *et al*. Clinicopathological characteristics and treatment outcomes of occult breast cancer: a SEER population-based study. *Cancer Manag Res*. 2018; 10: 4381-91.
11. Ni YB, Tsang JYS, Shao MM, *et al*. GATA-3 is superior to GCDFP-15 and mammaglobin to identify primary and metastatic breast cancer. *Breast Cancer Res Treat*. 2018; 169(1): 25-32.
12. Voduc D, Cheang M, Nielsen T. GATA-3 expression in breast cancer has a strong association with estrogen receptor but lacks independent prognostic value. *Cancer Epidemiol Biomarkers Prev*. 2008; 17(2): 365-73.
13. Teoh PY, Tan GC, Mahsin H, Wong YP. Androgen receptor expression in triple negative breast carcinoma and its association with the clinicopathological parameters. *Malays J Pathol*. 2019; 41(2): 125-132.
14. Mohd Nafi SN, Siti Azrin AH, Mat Zin AA, Othman NH, Che Jalil NA. Expression of IGFBP-rP1 in ovarian and breast cancers in association with diabetes mellitus status. *Malays J Pathol*. 2019; 41(1): 339.
15. Kumcu E, Unverdi H, Kaymaz E, Oral O, Turkbey D, Hucmenoglu S. Stromal podoplanin expression and its clinicopathological role in breast carcinoma. *Malays J Pathol*. 2018; 40(2): 137-142.