

# Clinical and Histopathologic Features of Acquired Perforating Collagenosis: A Case Report

Guillan Antonio Isidro C. Catolico, MD and Charlene Ang-Tiu, MD

*Rizal Medical Center*

## ABSTRACT

A 51-year-old hypertensive and diabetic male patient, admitted due to acute kidney injury on top of chronic kidney disease, was referred to the dermatology service. He presented with a 3-month history of multiple discrete pruritic papules with keratotic plugs over the extensor aspects of the bilateral upper and lower extremities, initially managed as a case of scabies infestation but medications given provided no relief. Histopathologic analysis of a skin biopsy revealed findings of acquired perforating collagenosis. Resolution of lesions and pruritus were noted after starting on a topical corticosteroid ointment on the lesions, as well as hemodialysis to address the renal failure. Subsequent consults showed no recurrences and only a minor sequela of post-inflammatory hyperpigmentation.

*Keywords: acquired perforating dermatoses, acquired perforating collagenosis*

## INTRODUCTION

Acquired perforating dermatosis (APD) is an uncommon cutaneous perforating disorder characterized by hyperkeratotic papules and nodules with a central keratotic core. The diagnosis is clinical but histopathological findings may aid in identifying the correct subtype: elastosis perforans serpiginosa (EPS), acquired perforating collagenosis (APC), perforating folliculitis (PF) or Kyrle's disease (KD).<sup>1</sup> The disease usually occurs in association with diabetes mellitus and/or renal failure.<sup>2</sup> Its exact etiology is unknown but a complex interaction between epithelium, connective tissue, and inflammatory mediators is most likely involved. The lesions of acquired perforating dermatosis may resolve with the use of topical retinoids, topical steroids, intralesional steroids, and phototherapy.<sup>3</sup> However, prognosis is heavily linked to the presence of underlying diseases as some cases have shown to improve with successful control of the comorbid status. After effective therapy, the skin lesions may regress completely, leaving atrophic scars and pigmentation. Spontaneous resolution rarely occurs and most cases of APD continue for years if left untreated.<sup>4</sup> This case report describes the clinical and histopathologic features of a rare case of APC in a Filipino patient with both diabetes mellitus and chronic kidney disease. Knowledge of the cutaneous findings, symptoms, histopathologic image, differential diagnoses, as well as the associated medical conditions, will allow timely initiation of appropriate treatment.

## CASE PRESENTATION

A 51-year-old male who is a known case of hypertension, type 2 diabetes mellitus, and chronic kidney disease,



eISSN 2094-9278 (Online)  
Published: August 29, 2023  
<https://doi.org/10.47895/amp.vi0.4837>

Corresponding author: Guillan Antonio Isidro C. Catolico, MD  
Rizal Medical Center  
Pasig Blvd., Pasig City 1600, Philippines  
Email: [guillancatolico@gmail.com](mailto:guillancatolico@gmail.com)  
ORCID: <https://orcid.org/0009-0009-7496-6477>

presented with a three-month history of multiple discrete papules over the extensor aspect of the bilateral upper and lower extremities associated with intense pruritus (10/10). The lesions have been increasing in number over the three-month period and the pruritus was noted to occur in paroxysms but has been noted to be more frequent. Initially, no consultation was sought but in the interim, he noted hemorrhagic crusting, keratotic plugs, and excoriations, as well as the appearance of similar lesions on the trunk. This prompted consult from a family physician where the patient was treated as a case of scabies with secondary bacterial infection. The patient was given oral antibiotics and a scabicide topical medication which provided temporary improvement of both the lesions and the pruritus. However, the patient still reported appearance of new lesions on previously unaffected skin and the pruritus recurred. On physical examination, there were multiple erythematous to hyperpigmented papules with excoriations and keratotic plugs, over the trunk and bilateral upper and lower extremities, extensor aspect (Figures 1A-D).

A 4 mm skin punch biopsy was performed on an excoriated papule on the left thigh. Histopathology revealed a cup-shaped invagination of orthokeratosis and parakeratosis, crusts, and marked neutrophilic infiltrates (Figure 2A). Other findings include perforation in the epidermis with neutrophils, trans-epidermal elimination of collagen, lichenoid infiltrate of lymphocytes in dermis, and moderate to dense infiltration of lymphocytes and eosinophils in papillary dermis (Figures 2B and 2C).

At the time of hospital admission, the patient's fasting blood glucose was: 9.1 mmol/L, creatinine: 894.4 mmol/L, CRP: 47.3 mg/L. The patient was then started on emergency hemodialysis by the main referring service. He was also started on clobetasol propionate ointment, 500mcg/g applied twice daily for 2 weeks, as well as mild fragrance-free emollients four times a day to the affected areas. Further therapeutic plans include initiation of narrowband UVB phototherapy. In the course of 2 weeks, the patient was noted to have marked improvement of the lesions using topical steroids and emollients, as well as initiation of hemodialysis. Subsequent consultations at the out-patient department revealed no recurrence of lesions, resolution of the lesions with post-inflammatory hyperpigmentation, and an overall improvement in quality of life based on the Dermatology Life Quality Index (DLQI) administered during the first consult prior to treatment compared with that of the first out-patient follow up. Pertinent laboratory findings three months after discharge were as follows: fasting blood glucose: 6.2 mmol/L and creatinine: 120.8 mmol/L. No recurrences have been noted as of this writing and the patient has been in regular hemodialysis treatment as well.

## DISCUSSION

This is a case of a 51-year-old male with a rare case of Acquired Perforating Dermatitis and on histopathology,

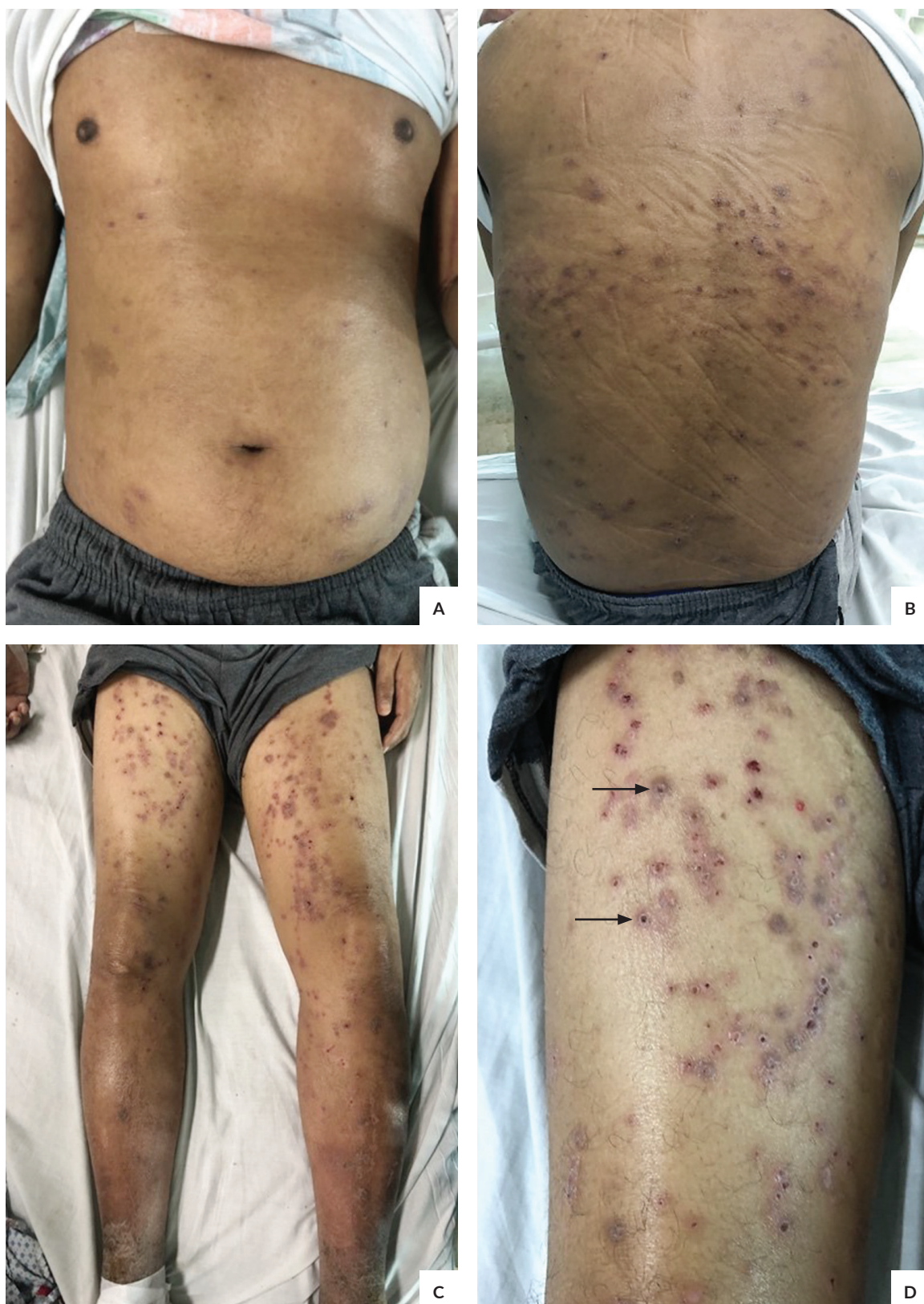
discovered to be an even more rare subtype of Acquired Perforating Collagenosis. The prevalence and incidence of APC are unknown, although scattered cases have been reported: 10 cases of APC out of 5,202 hospitalized patients in Bremerhaven Hospital, Germany were reported between 2007 and 2011.<sup>5</sup> According to the Philippine Dermatological Society Health Information System, in 2011 to 2022, out of the 746,869 total number of patients of all diseases logged in the registry, there have only been 45 new cases (0.006%) of Acquired Perforating Dermatitis and 18 new cases (0.002%) of Acquired Perforating Collagenosis.<sup>6</sup>

Although histopathology will confirm the diagnosis, APD can be identified clinically with a high index of suspicion but differential diagnoses are important to rule out. These include prurigo nodularis, arthropod bites, folliculitis, scabies, and lichen planus. Among all the differential diagnoses, APD may be most difficult to differentiate from prurigo nodularis as they share common features of round shape, firm, erythematous to hyperpigmented, and appears in extensor aspects of the extremities. However, the central keratotic core is the most specific clinical finding of APD and this feature is rarely seen in prurigo nodularis.<sup>7</sup>

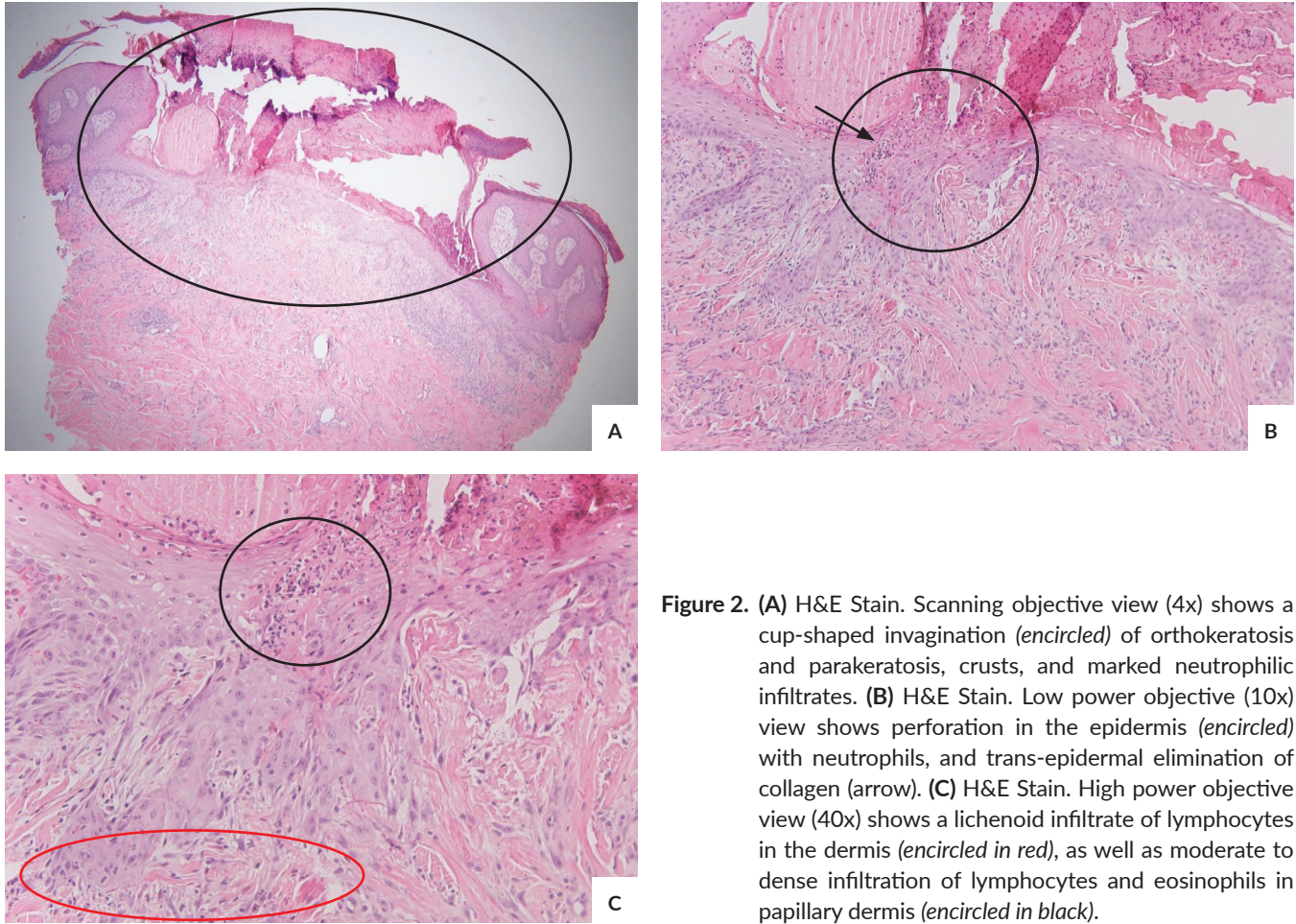
This case shares common features with that of three other patients with APC in a study conducted in 2021 and 2022.<sup>8,9</sup> In all cases, patients were elderly males 51-71 years old (average of 62 years old), with common co-morbid condition of type 2 diabetes mellitus, whether controlled or poorly controlled. In two out of the other cases reported, similar with that of the patient in this case report, fasting blood sugar and creatinine were elevated (FBS 8.8 mmol/L and 6.9 mmol/L; Creatinine 121 mmol/L and 679.07 mmol/L). In all cases, the patients shared common features of intense pruritus, typical skin lesions and sites of predilection, and common histopathologic features. In addition, all patients noted resolution of lesions with treatment of the underlying cause, although two patients were also started on dupilumab, a IL-4 and IL-13 monoclonal antibody.

## CONCLUSION

Acquired Perforating Dermatitis is an uncommon disorder but should be suspected in a patient who presents with characteristic skin lesions and sites of predilection, as described in this case. In addition, the presence of co-morbid conditions of diabetes and chronic kidney disease may clinch the diagnosis better. APD appears similar to prurigo nodularis which should always be ruled out due to its more benign course, in contrast to APD which is associated with co-morbid conditions that may cause mortality. The specific diagnosis of the rare subtype Acquired Perforating Collagenosis may be confirmed in its characteristic histopathologic finding of trans-epidermal elimination of collagen. However, treatment is similar and one recommendation is a multi-disciplinary approach which focuses on treating the underlying cause while also addressing symptoms of pruritus.



**Figure 1.** Multiple discrete and coalescing erythematous to hyperpigmented papules with excoriations and hemorrhagic crusts on the trunk (A), predominantly on the back (B) as well as on the bilateral lower extremities (C), predominantly on the flexural aspect of the thighs (D) (arrows).



**Figure 2.** (A) H&E Stain. Scanning objective view (4x) shows a cup-shaped invagination (*encircled*) of orthokeratosis and parakeratosis, crusts, and marked neutrophilic infiltrates. (B) H&E Stain. Low power objective (10x) view shows perforation in the epidermis (*encircled*) with neutrophils, and trans-epidermal elimination of collagen (arrow). (C) H&E Stain. High power objective view (40x) shows a lichenoid infiltrate of lymphocytes in the dermis (*encircled in red*), as well as moderate to dense infiltration of lymphocytes and eosinophils in papillary dermis (*encircled in black*).

### Statement of Authorship

GAICC contributed in the conceptualization of work, acquisition and analysis of data, and drafting of the manuscript. CAT contributed in the conceptualization of work, revising the manuscript draft, and final approval of the version to be published.

### Author Disclosure

Both authors declared no conflicts of interest.

### Funding Source

The study was funded by the authors.

### REFERENCES

- Rapini RP. Perforating disorders. In: Arndt KA, Le Boit PE, Robinson JK, Wintroub BU, eds. *Cutaneous Medicine and Surgery*, 1st ed. Philadelphia: W.B. Saunders Company; 1996. pp. 407–411.
- Kurban MS, Boueiz A, Kibbi AG. Cutaneous manifestations of chronic kidney disease. *Clin Dermatol*. 2008 May-Jun;26(3):255-64. doi: 10.1016/j.clindermatol.2007.10.017.
- Morton CA, Henderson IS, Jones MC, Lowe JG. Acquired perforating dermatosis in a British dialysis population. *Br J Dermatol*. 1996 Nov;135(5):671-7.
- Lukács J, Schliemann S, Elsner P. Treatment of acquired reactive perforating dermatosis – a systematic review. *J Dtsch Dermatol Ges*. 2018 Jul;16(7):825-842. doi: 10.1111/ddg.13561.
- Zhang X, Yang Y, Shao S. Acquired reactive perforating collagenosis: A case report and review of the literature. *Medicine (Baltimore)*. 2020 May 29;99(22):e20391. doi: 10.1097/MD.00000000000020391.
- Philippine Dermatological Society Health Information Systems. Philippine Dermatological Society [Internet]. c2011 updated August 2022 [cited 2022 Sep]. Available by request from: pdshis@outlook.com
- Kang S, Amagai M, Bruckner AL, Enk AH, Margolis DJ, McMichael AJ, Orringer JS. eds. *Fitzpatrick's Dermatology*, 9e. McGraw Hill; 2019.
- Akagun T, Oguz ID, Usta S, Kabaday HO. Acquired Reactive Perforating Collagenosis in Patient with Diabetic Chronic Kidney Disease: A Case Report. *Clin Case Rep Int*. 2022; 6:1312.
- Ying Y, Shuang C, Zhen-Ying Z. Dupilumab may be an alternative option in the treatment of acquired reactive perforating collagenosis combined with AD. *Immun Inflamm Dis*. 2022 Mar;10(3):e574. doi: 10.1002/iid3.574.