

Bohn's Nodule: A Rare Case in a 7-month-old Male Infant

Ali Taqwim, DDS,¹ Sukeksi Dyah Intanningrum, DDS,² Eva Nuryanti, DDS,¹
Marsha Anindya Abigail Pantouw, DDS¹ and Tania Saskianti, DDS, PhD¹

¹Department of Pediatric Dentistry, Faculty of Dental Medicine, Universitas Airlangga, Surabaya Indonesia

²Pediatric Dental Clinic, Dr. Saiful Anwar Hospital, Malang, Indonesia

ABSTRACT

Bohn's nodule is a soft white cyst filled with keratin and is often found in a newborn's oral cavity. This case has a high prevalence in newborns and is rarely seen in infants after three months.

In this case, we report our observation and evaluation of a Bohn's nodule case in a seven-month-old male infant. Clinical diagnosis of the conditions is vital to avoid unnecessary therapeutic procedures and provide timely information for parents to manage the lesion.

Keywords: Bohn's nodule, gingival cyst, inclusion cyst, infant, oral lesion

INTRODUCTION

Many features of the oral cavity are unique and peculiar during the developmental period of birth. Some benign oral mucosal conditions are frequently found in newborns, which are transient in characteristic.¹ Among these conditions, we highlight the emergence of inclusion cysts, which develop during the embryonic period. Inclusion cysts or developmental nodules of the oral mucosa are intraoral swellings located in the palate or alveolar ridges.²

Three different types of cysts have been identified: Bohn's nodules, Epstein's pearls, and dental laminar cysts. These terms are often used as synonyms because all cysts similarly present as white or translucent roundish solitary or multiple papules, localized in the palate or gums' mucosa.³ The pathology has common features, while its nomenclature is dependent on the location of the cyst.

Bohn's nodules are cysts located in the gingival region on the buccal or lingual surface of the alveolar ridge (not the crest) or the hard palate, away from the midline. When cysts are found in the midline of the palatine bone, they are referred to as Epstein's pearls or palatal cyst of the newborn. Dental laminar cysts are located on the crest of the alveolar ridges. These cysts are presumably derived from remnants of the ectodermal component of the tooth bud.^{2,3} The inclusion cysts are persistent oral abnormalities among newborns and rarely occur after three months of age.^{4,5}

Bohn's nodules, described by Heinrich Bohn in 1886 as "mucous gland cysts," were derived from minor salivary glands. They were found at the hard and soft palate's junction, along with lingual and buccal parts of the alveolar ridges, away from the midline. These nodules are 1–3 mm in size and

Corresponding author: Tania Saskianti, DDS, PhD
Department of Pediatric Dentistry
Faculty of Dental Medicine
Universitas Airlangga
Surabaya Indonesia
Email: taniapedo@yahoo.com

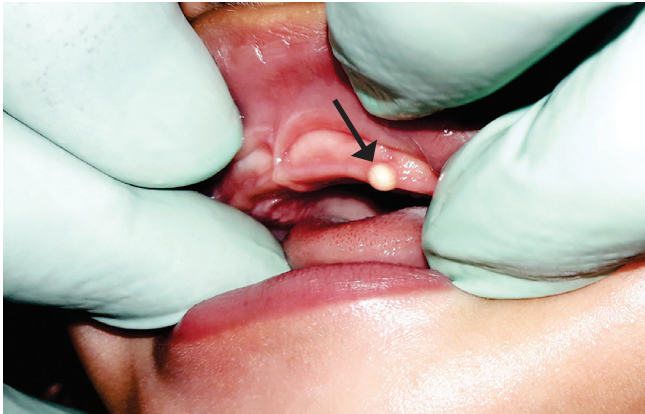

Figure 1. Clinical appearance of the nodule.

filled with keratin. Bohn also classified cysts in the alveolar ridges as mucous gland cysts. However, a century later, it was shown that these cysts were microkeratocysts.⁶

The existence of Bohn's nodules is often not realized by parents and is even considered a normal condition. Parents rarely seek treatment for this lesion.

Bohn's nodule is common among newborns until three months but has been found in this 7-month-old infant case. Because of its unlikelihood occurrence in the said age group, proper diagnosis is necessary to avoid unnecessary treatment.

CASE REPORT

A 7 month-old male infant was brought to the pediatric dental clinic of the Dr. Syaiful Anwar Hospital – Malang due to a small nodule and round-shaped protuberances on the maxillary gingival surface (Figure 1) assumed to be dental edges by the parents.

The nodule was solitary, 2 mm in size, white-colored, firm, and not tender on palpation. There was no erythema around it; the deciduous teeth have not erupted yet, no other abnormality was seen in any other site in the oral cavity. Physical examination was unremarkable.

Based on the anamnesis, the baby was born at 40 weeks gestational age, weighing 3100 grams. The baby consumed breast milk for two months and then followed with formula milk. The mother routinely consumed folic acid during the pregnancy. The parents denied any medical history, but the father was known to be a smoker.

CASE MANAGEMENT

Based on the anamnesis, clinical examination (texture, consistency, and location), evaluation of nodule development, and compared with the differential diagnosis of other oral mucosal disorders, the diagnosis for this case was Bohn's nodules.

This case's management is instructive for parents to maintain their infant's oral hygiene. Regular monthly follow-up and observation were chosen to evaluate the nodule development. The clinical follow-up after one month showed no significant clinical improvement. The white nodule was still attached to the maxillary gingival surface, and there was no increase in size. Three months later, the nodule spontaneously resolved (Figure 2B).

DISCUSSION

Bohn's nodules are scattered over the hard and soft palate's junction and are derived from the minor salivary gland. A histopathologic evaluation may reveal a cystic lumen filled with desquamated keratin and lined by stratified squamous epithelium occasionally with inflammatory cells

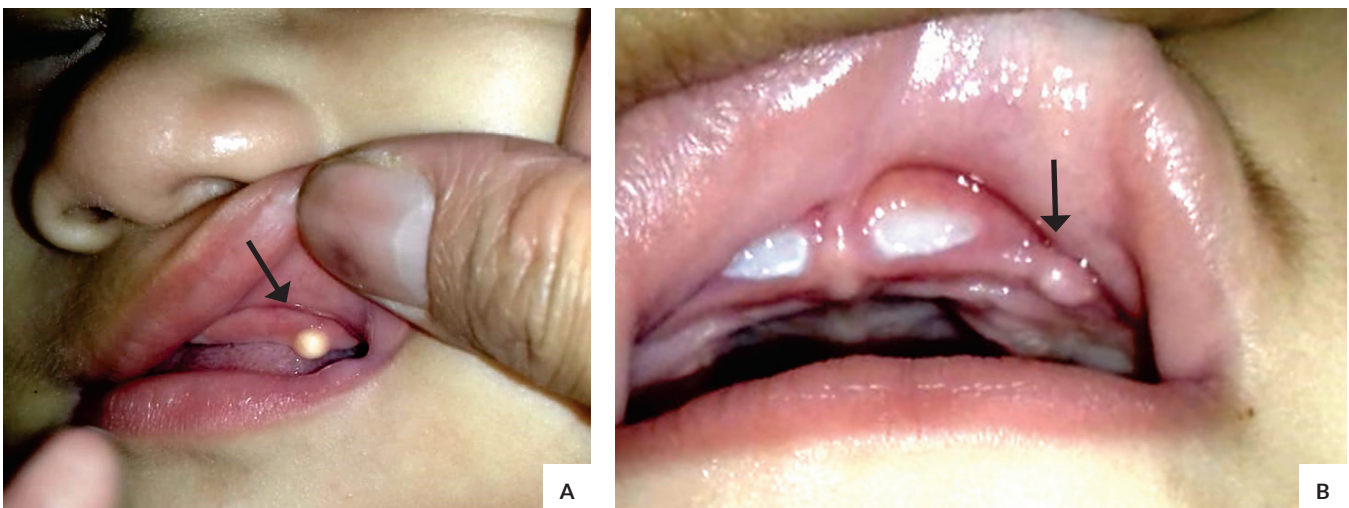






Figure 2. Regular follow-up and check-up by parents at home; (A) after one month; (B) after 3 months, Bohn's nodule spontaneously resolved.

Table 1. Differential diagnosis of Bohn's nodule¹⁶⁻¹⁹

	Bohn's nodule	Epstein pearls	Dental laminar cyst	Natal teeth
Appearance	Keratin-filled cysts, remnants of salivary glands	Small cystic, keratin-filled nodules	Ingrowth ectodermal laminal surfaces of the oral cavity	Small and conical, but can assume the sizes and shapes of normal teeth. They may be yellowish or brownish and are usually immature, with enamel hypomineralisation and small roots
Region	The junction of the hard and soft palate and along buccal and lingual parts of the alveolar ridges away from the midline	The roof of the palate, along the midline of the palate	Mandibular anterior region	Mandibular primary incisors
Characteristic	Self-limiting	Self-limiting	Self-limiting	Required aggressive treatment
Figure				

in the connective tissue. Sometimes these "true cysts" demonstrate communication with the mucosal surface. Due to the pressure from the cyst, the epithelium can atrophy.^{7,8}

Bohn's nodules are found in newborns and usually disappear spontaneously in the early months of life. They are more frequently observed in full-term babies or those with a weight at birth of more than 2500 grams and associated with the male sex.^{9,10} This correlates with our case since our patient was a full-term male baby with a weight of 3100 grams at birth.

In a study by Perez-Aguirre et al. in 2018, it was found that the consumption of folic acid during pregnancy significantly increased the prevalence of Bohn's nodule, and so did tobacco used during pregnancy.¹¹ However, this case's specific etiology is still unknown; there are no known references or clinical reports in babies after three-months-old.

Although this condition is congenital, Bohn's nodules cause no symptoms and may go unnoticed. The nodules occur mainly in the gingiva's vestibular portion and more frequently on the maxillary arch than the mandibular arch.¹² Concerned parents who notice the nodules can mistake them as natal teeth and lead them to seek medical attention.

Bohn's nodule must be differentiated with other developmental inclusion cysts, including Epstein's pearl, dental laminar cyst, natal/neonatal teeth, and gingival cysts.

Epstein's pearl is a small, firm, white, keratin-filled cyst located on the mid palatine raphe. A dental laminar cyst is a yellow-white cystic lesion over the alveolar crest that arises from the degenerating dental lamina's epithelial remnants. Natal/neonatal teeth usually erupt in the center of the mandibular ridge as central incisors. They have little root structure and are attached to the end of the gum by soft tissue.¹³ Gingival cyst of a newborn is a true cyst as it is lined by thin epithelium and usually shows a lumen filled with desquamated keratin, occasionally containing inflammatory cells.

These structures originate from the dental lamina remnants and are located in the corium below the surface epithelium. The nodes result from cystic degeneration of epithelial rests of the dental lamina (rests of Serres). After invagination of the dental lamina to form the dental organ, the epithelial pedicle that connects the dental organ to the surface epithelium is broken down, giving rise to the rest of Serres. Occasionally they may become large enough to be clinically noticeable as discrete white swellings on the ridges.^{7,14}

Bohn's nodule are present in neonates, rarely seen after three months.^{4,5} In this case, Bohn's nodule was found in a seven-month-old infant, and there was no history of nodule before. Seven-months old is the typical period for the eruption of the first deciduous incisive teeth. This condition can be misdiagnosed with the first erupted tooth by parents. Education for parents is critical so that they do not panic and unnecessary treatment can be avoided. Furthermore, research showed that the existence of Bohn's nodule could serve as a site of *Streptococcus mutans* colonization at an early age, increasing the risk of caries later. Maintaining oral hygiene is mandatory.¹⁰

A dentist should recognize these lesions and reassure them to avoid unnecessary medical or surgical intervention.^{15,16} Treatment is unnecessary since Bohn's nodules are innocuous and disappear within a few weeks to a few months. The small cysts are thought to rupture spontaneously as they grow, their walls merging with the gums' epithelial surface. Some authors suggest easing their resolution by a gentle digital massage on the affected area, while others find any treatment useless or even noxious.^{2,12}

CONCLUSION

Bohn's nodule is a common occurrence among newborns up until three months. Although rarely seen, this condition

can be found in 7-months-old infants, in which the typical age range for the eruption of first deciduous teeth may be misdiagnosed and overtreated. Recognition of the lesion is essential to avoid unnecessary treatment since it is a condition that is self-limiting.

Statement of Authorship

All authors participated in data collection and analysis and approved the final version submitted.

Author Disclosure

All authors declared no conflicts of interest.

Funding Source

No funding support.

REFERENCES

1. Madathil J, Negi BS, Kumar NR. Gingival cyst of new born: a case report. *Int J Contemp Pediatr*. 2016 Aug; 3(3):1129-31.
2. Cambiaghi S, Gelmetti C. Bohn's nodules. *Int J Dermatol*. 2005 Sep; 44(9):753-4.
3. Moda A. Gingival cyst of newborn. *Int J Clin Pediatr Dent*. 2011 Jan-Apr; 4(1):83-4.
4. Donley CL, Nelson LP. Comparison of palatal and alveolar cysts of the newborn in premature and full-term infants. *Pediatr Dent*. 2000 Jul; 22(4):321-4.
5. Philipone E, Yoon AJ. Gingival/Alveolar Cysts of the Newborn. In: Philipone E, Yoon AJ, eds. *Oral Pathology in the Pediatric Patient: A Clinical Guide to the Diagnosis and Treatment of Mucosal Lesions*, 1st ed. Switzerland: Springer International Publishing; 2017. pp. 92-3.
6. Moreillon MC, Schroeder HE. Numerical frequency of epithelial abnormalities, particularly microkeratocysts, in the developing human oral mucosa. *Oral Surg Oral Med Oral Pathol*. 1982 Jan; 53(1):44-55.
7. Regezi JA, Sciubba JJ, Jordan RCK. Gingival Cysts of the Newborn. In: Regezi JA, Sciubba JJ, Jordan RCK, eds. *Oral Pathology Clinical Pathologic Correlations*, 6th ed. Missouri: Elsevier Saunders; 2012. pp. 251.
8. Revathy V, Bharath KP. Alveolar cyst of the newborn: a case report. *Arch Orofac Sci*. 2012 Mar; 7(2):85-7.
9. Marini R, Chipaila N, Monaco A, Vitolo D, Sfasciotti GL. Unusual symptomatic inclusion cysts in a newborn: a case report. *J Med Case Rep*. 2014 Sep; 8:314.
10. Chandler CL, Azevedo ID, Silva Junior MF, Lopes JM, Gordon-Nunez MA, Pereira SA. Intraoral findings in newborns: prevalence and associated factors. *Braz J Oral Sci*. 2018 Dec; 17: 1-11.
11. Perez-Aguirre B, Soto-Barreras U, Loyola-Rodriguez JP, Reyes-Macias JF, Santos-Diaz MA, Loyola-Leyva A, et al. Oral findings and its association with prenatal and perinatal factors in newborns. *Korean J Pediatr*. 2018 Sep; 61(9):279-84.
12. Bezerra S, Costa I. Oral conditions in children from birth to 5 years: the findings of a children's dental program. *J Clin Pediatr Dent*. 2000; 25(1):79-81.
13. Mecarini F, Fanos V, Crisponi G. Anomalies of the oral cavity in newborns. *J Perinatol*. 2020 Mar; 40(3):359-68.
14. Flinck A, Paludan A, Matsson L, Holm AK, Axelsson I. Oral findings in a group of newborn Swedish children. *Int J Paediatr Dent*. 1994 Jun; 4(2):67-73.
15. Gupta N, Ramji S. Bohn's nodules: an under-recognised entity. *Arch Dis Child Fetal Neonatal Ed*. 2013 Sep; 98(5):F464.
16. Cizmeci MN, Kanburoglu MK, Kara S, Tatli MM. Bohn's nodules: peculiar neonatal intraoral lesions mistaken for natal teeth. *Eur J Pediatr*. 2014 Oct; 173(3):403.
17. Singh RK, Kumar R, Pandey RK, Singh K. Dental lamina cysts in a newborn infant. *BMJ Case Rep*. 2012 Oct; 2012:bcr2012007061.
18. George D, Bhat SS, Hegde SK. Oral Findings in Newborn Children in and around Mangalore, Karnataka State, India. *Med Princ Pract*. 2008; 17(5):385-9.
19. Jamani NA, Ardini YD, Harun NA. Neonatal tooth with Riga-Fede disease affecting breastfeeding: a case report. *Int Breastfeed J*. 2018 Jul; 13:35.