

Recurrent Desmoid Fibromatosis of the Thyroid Gland: A Diagnostic Challenge

Brijesh Kumar Singh,¹ Sunil Chumber,¹ Yashwant Singh Rathore,¹
Shipra Agarwal,² Sameer Rastogi,³ Vyas Surabhi⁴

¹Department of Surgical Disciplines, All India Institute of Medical Sciences, New Delhi, India

²Department of Pathology, All India Institute of Medical Sciences, New Delhi, India

³Department of Medical Oncology, All India Institute of Medical Sciences, New Delhi, India

⁴Department of Radiodiagnosis, All India Institute of Medical Sciences, New Delhi, India

Abstract

A 31-year-old Indian female with a history of near-total thyroidectomy 2.5 years prior presented with recurrent neck swelling. Magnetic resonance imaging (MRI) of the neck revealed an infiltrating mass involving the thyroid bed. Biopsy from the mass and review of slides from the previous thyroidectomy revealed a spindle cell tumour with interspersed areas of fibrosis and infiltrative edges entrapping thyroid follicles. Beta-catenin immunopositivity and CTNNB1 mutation confirmed the diagnosis of fibromatosis. The case is being reported for its rarity and the discussion of its differential diagnoses.

Key words: thyroid, fibromatosis, immunohistochemistry, molecular, thyroid nodule

INTRODUCTION

A thyroid nodule in a middle-aged euthyroid female is commonly due to colloid nodule, adenoma, nontoxic multinodular goiter or differentiated thyroid cancer. Recurrent thyroid swelling following surgery, size >4 cm, firm consistency, fixation to adjacent tissues, cervical lymphadenopathy and vocal cord paralysis indicate a probable malignant pathology.¹ We discuss a case of recurrent thyroid bed swelling in a 31-year-old Indian female with clinical symptoms suggestive of malignancy. However, histopathological and molecular examination revealed a diagnosis of desmoid fibromatosis involving the thyroid gland. The tumor is rare and a great imitator in this location which posed a unique diagnostic challenge.

CASE

A 31-year-old Indian female presented with left-sided neck swelling, rapidly increasing in size from 2 cm to 8 cm over six months. There were no associated symptoms of pain, anorexia, weight loss, difficulty in breathing or swallowing, or any features suggestive of hypo- or hyperthyroidism. Examination of the neck revealed an 8 cm x 7 cm, irregular, indurated, non-tender mass with ill-defined margins on the left anterior aspect of the neck and is fixed to the underlying structures.

The patient had a history of near-total thyroidectomy done 2.5 years ago for a left thyroid tumor. Neck enlargement

had been present for one year before surgery. Ultrasound examination done at that time revealed a heterogeneous mass involving the left thyroid lobe, having significant vascularity but lacking calcifications. A near-total thyroidectomy was performed due to the presence of adhesions with underlying structures. Histopathologic examination was suggestive of Riedel's thyroiditis.

Magnetic resonance imaging of the neck done at the time of recurrence revealed an infiltrating soft tissue mass measuring 7.4 cm x 6.9 cm involving the left side of the neck extending into paravertebral space, encasing the left carotid artery and compressing the left jugular vein (Figure 1). The differential diagnoses of anaplastic thyroid carcinoma and thyroid lymphoma were also considered due to the clinical presentation. Fine needle cytology was hypocellular. Few hypo- and moderately cellular dense collagenous stromal fragments were noted. The cells were oval to spindle-shaped and had fine nuclear chromatin. The material was considered inadequately representative. A core needle biopsy showed a hypocellular spindle cell lesion. Images, sections and paraffin blocks of the previous thyroidectomy specimen were reviewed.

Grossly, the specimen was distorted, replaced entirely by the tumor, and measured 8 cm x 7 cm x 6.5 cm (Figure 2). Microscopic examination revealed a tumour composed of fibroblasts with intervening collagen deposition. The cells lacked atypia and mitotic activity. Few thin and thick-walled focally ectatic blood vessels were interspersed. The

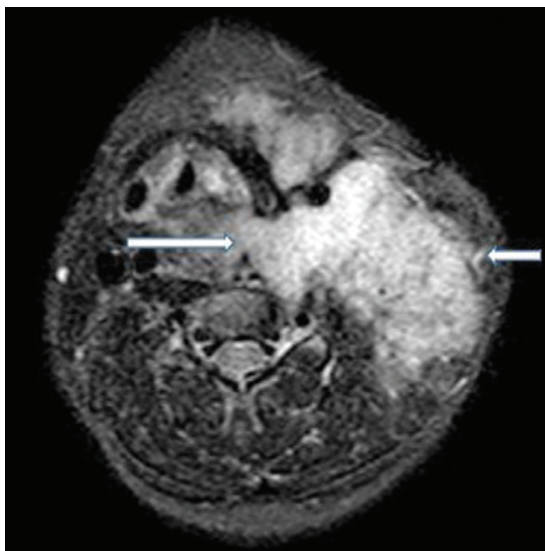
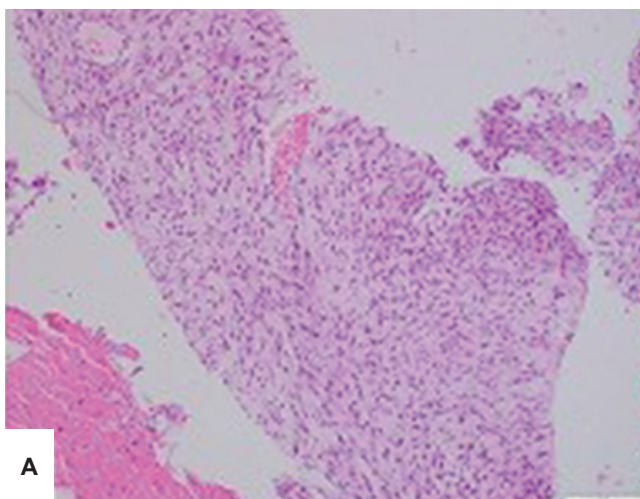


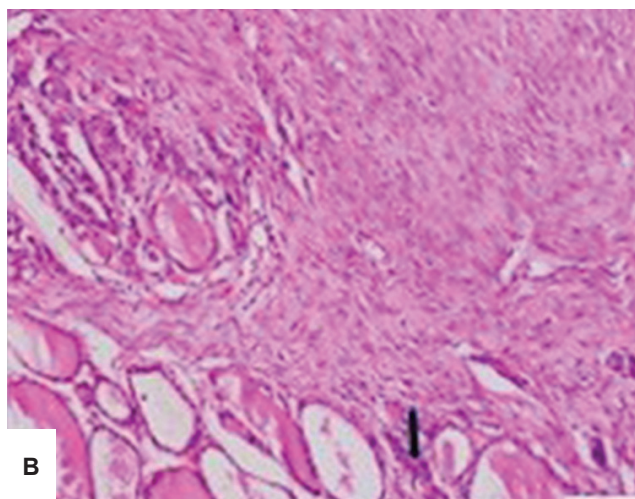
Figure 1. T2-weighted magnetic resonance image of the neck in axial view showed a hyperintense mass on the left side of the neck, extending to pre-laryngeal and prevertebral spaces (*arrows*).

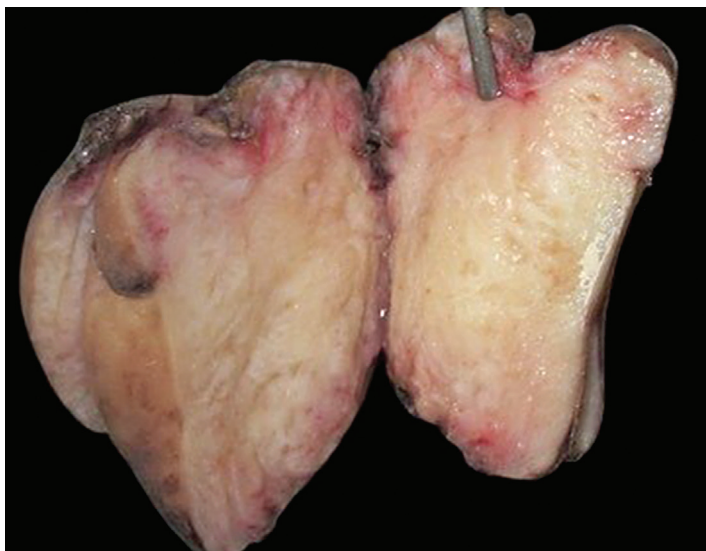

Figure 2. Gross examination of the thyroidectomy specimen showed a tumor measuring 8 cm x 7 cm x 6.5 cm, replacing the entire gland. No normal thyroid parenchyma was discernible. The cut surface appeared fleshy, grey-white in color with whorls and myxoid foci.



A



B

Figure 3. Microscopic examination of core biopsy (*H&E, 100x*). **(A)** revealed a low-grade spindle cell tumour having areas of fibrosis. Examination of the thyroidectomy specimen (*H&E, 200x*). **(B)** showed that the tumor infiltrated the normal thyroid parenchyma at the periphery (*black arrow*).

tumour infiltrated the residual thyroid, which was within normal histological limits, and neck skeletal muscle bundles (Figure 3). Minimal focal lymphoplasmacytic infiltrate was noted within and at the advancing edge of the lesion. There was no evidence of malignancy or obliterative vasculitis. Immunohistochemical studies demonstrated that the cells were positive for smooth muscle actin (Scytek, 1A4, A00002) and desmin (Scytek, D33, A00007), and showed nuclear and cytoplasmic staining with β -catenin (BD Biosciences, 14/Beta-Catenin, 610154), but were negative for pan-cytokeratin (Bio SB, AE1 & AE3, BSB 5433), CD34 (Spring Bioscience, QBEnd/10, E1281), and S-100 (Bio SB, 4C4.9, BSB 5919) (Figure 4). Ki-67 (Invitrogen, SP6, MA5-14520) labelling index was 7 to 8% in areas of highest proliferation. Bi-directional Sanger sequencing performed on DNA extracted from the tumor block revealed a

mutation involving the beta-catenin (*CTNNB1*) gene (c.134C>T; p.S45F) (Figure 5). A final diagnosis of desmoid fibromatosis involving the thyroid gland was rendered.

Surgery was not attempted as the mass was encasing vital neck structures. The patient was placed on Sorafenib, a tyrosine kinase inhibitor. On a follow-up magnetic resonance imaging (MRI) at two months, there has been no change in the extent of the tumor suggesting stable disease.

DISCUSSION

Desmoid fibromatosis is a locally aggressive deep-seated proliferation of fibroblastic/ myofibroblastic cells. It has a high propensity for local recurrence but lacks metastatic potential. Extremities are the most common sites for this

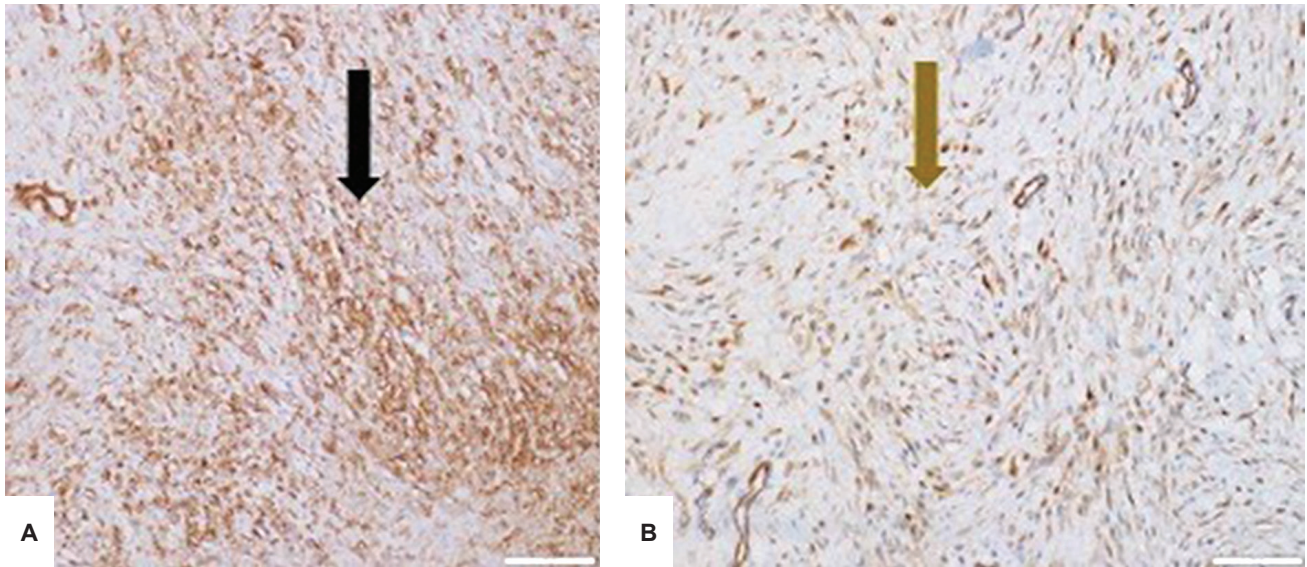


Figure 4. Immunohistochemical staining of the tumor cells showed (A) positivity for smooth muscle actin (black arrow; IHC, 200x) and (B) nuclear and cytoplasmic expression of β -catenin (brown arrow; IHC, 200x).

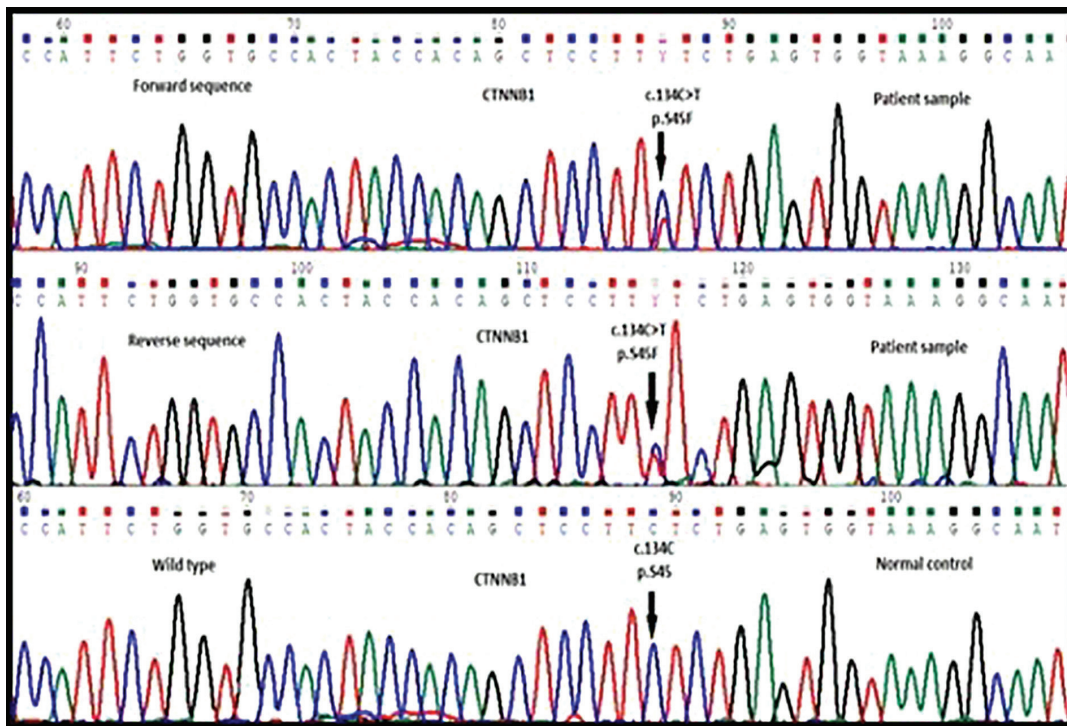


Figure 5. Bi-directional Sanger sequencing performed on DNA extracted from the tumor block revealed a mutation at codon 45 of exon 3 (c.134C>T; p.S45F) of the β -catenin (CTNNB1) gene (arrows).

condition, accounting for 30 to 40% of cases. Head and neck involvement is rare, occurring in 7 to 15%.² Thyroid disease is even rarer, with only six cases described in five reports.³⁻⁷ The Department of Pathology of the All India Institute of Medical Sciences, New Delhi, receives an average of about 250 thyroidectomy specimens per year. The patient is the first documented case since 2014. As highlighted in the present report, the atypical site of involvement and differential diagnoses with other more common primary lesions posed a diagnostic challenge leading to a delay in appropriate therapy.

Table 1 summarizes the details of all the cases reported to date.³⁻⁷ The disease shows a female predilection. The age at presentation has ranged from the third to the seventh decade.³⁻⁷ The patients may present with thyroid swelling, associated with compression symptoms like dysphonia, dyspnea and dysphagia.^{4,5} History of injury with a wire was reported in one of the two cases reported by Schwarzlmüller.³ The preoperative diagnoses were varied, including thyroid carcinoma, follicular neoplasm, multinodular goitre³ or spindle cell lesion.³⁻⁷ Management was surgical in all. In one patient, owing to the fixation of the mass to the trachea

Table 1. Summary of cases with thyroid fibromatosis reported in literature

| Author, year | No. of cases | Age/Sex | FNAC | Molecular analysis | Management | Follow-up |
|-----------------------------------|--------------|---------|-----------------------------------|------------------------|--|--|
| Current case | 1 | 31/F | Few collagenous stromal fragments | CTNNB1 p.S45F c.134C>T | Total thyroidectomy (at first presentation), TKI (at recurrence) | Recurrence 2.5 years after first surgery |
| Sinha, 1998 ⁴ | 1 | 26/F | ND | ND | Limited surgery to relieve tracheal compression | Not mentioned |
| Samsi, 1992 ⁵ | 1 | 60/M | Spindle cell tumor | ND | Near total thyroidectomy | No recurrence after 1 year of follow-up |
| Schwarzlmüller, 1978 ³ | 2 | 38/F | ND | ND | Extent of resection not detailed | Recurrence 2 and 4 years after first surgery |
| | | 68/F | ND | ND | The extent of resection is not detailed | Not mentioned |
| Simões-Pereira, 2016 ⁶ | 1 | 63/F | Colloid goiter | ND | Total thyroidectomy | Developed vocal cord paralysis after surgery; no recurrence till 11 years of follow-up |
| Mehdizadeh, 2020 ⁷ | 1 | 37/M | Follicular neoplasm | ND | Near total thyroidectomy | No recurrence after 2 years of follow-up |

Abbreviations: FNAC, fine needle aspiration cytology; F, female; M, male; ND, not done; TKI, tyrosine kinase inhibitor

and encasement of the major vessels, only a limited surgery to relieve tracheal compression could be performed.⁴ Of the remaining patients with available follow-up, one developed recurrence twice, 2 and 4 years after initial surgery; and one had a recurrence-free follow-up of 11 years.^{3,7}

Desmoid-type fibromatosis commonly harbors sporadic activating mutations of the *CTNNB1* gene involving the codons 41 and 45 of exon 3. Inherited cases arising in the setting of Gardner syndrome have germline *APC* gene mutations. In both situations, there is nuclear accumulation of β -catenin protein detectable by immunohistochemistry.² Other etiologies include an estrogen-rich environment and previous trauma such as prior surgery.²

A recent review by Zhang et al. discusses the therapeutic modalities for fibromatosis.⁸ The treatment strategies include a watch-and-wait strategy, surgery, radiotherapy, chemotherapy, hormonal therapy, non-steroidal anti-inflammatory drugs, high-intensity focused ultrasound, and ablation techniques.⁸ However, none of these modalities is superior in preventing local recurrences.⁸

Watch-and-wait strategy is preferred for asymptomatic patients with head and neck fibromatosis, as 20 to 30% undergo spontaneous regression.⁹ Patients with progressive disease should initially be managed with anti-estrogenic hormonal therapy.⁹ It is, however, slow to act and higher doses are usually poorly tolerated by young females.⁹ Chemotherapy is considered for patients failing hormonal therapy. Surgery is recommended for patients not responding to hormonal and chemotherapeutic agents, but only if resection is possible.^{9,10} Younger patient age and tumor properties, including extra-abdominal location, larger size, and *CTNNB1* p.Ser45Phe mutation, have been associated with local recurrence after surgery.² Exclusive radiotherapy or surgery followed by radiotherapy should be considered when it is not feasible to perform R0 resection in critical areas like the head and neck.⁹ All the cases reported in literature have been managed surgically.

In our case, surgery was performed at the time of initial presentation. The patient had recurrence 2.5 years post-

surgery with rapid disease progression. Extensive local invasion precluded surgery; hence, sorafenib, a tyrosine kinase inhibitor was started. The patient is on regular clinical and radiologic follow-up. A phase III trial evaluating sorafenib in 87 patients with progressive, symptomatic or recurrent fibromatosis revealed a 2-year progression-free survival rate of 81% compared to 36% in patients given a placebo.¹¹

The cornerstone for the diagnosis of desmoids is histopathology. They show an infiltrative proliferation of fibroblasts lacking atypia. Other primary thyroid lesions which are more common and show prominent fibroblast proliferation include Riedel's thyroiditis, the fibrous variant of Hashimoto thyroiditis; papillary thyroid carcinoma (PTC) with fibromatosis/fasciitis-like stroma; and post-radiation fibrosis.

Both Riedel's thyroiditis and fibromatosis clinically mimic malignancy. Awareness, a high index of suspicion and careful pathological evaluation including immunohistochemistry and molecular analysis, help in resolving the diagnostic dilemma. Both Riedel's thyroiditis and fibromatosis clinically and morphologically show extensive fibrosis of thyroid parenchyma extending into adjoining neck structures. The presence of prominent IgG4-positive plasma cell infiltrates, obliterative phlebitis and lack of nuclear expression of β -catenin favor a diagnosis of Riedel's thyroiditis.¹² The fibroinflammatory process in Hashimoto's thyroiditis is limited to but affects the entire thyroid gland, in contrast to Riedel's thyroiditis. Additional features in the former include the presence of oncocytic metaplasia and lymphoid germinal centres. Another important differential diagnosis is PTC with fibromatosis/fasciitis-like stroma, which is also a rare pathology, comprising up to 0.5% of all cases of PTC. Histologically, it is a biphasic tumor. Myofibroblastic proliferation morphologically similar to fibromatosis or nodular fasciitis is noted along with a variable proportion of PTC. Like fibromatosis, the mesenchymal component shows *CTNNB1* mutation while the epithelial component commonly harbors *BRAF* V600E mutation.¹³ As the carcinoma may form only a minor component of the entire tumor, it may be absent on preoperative cytology

evaluation. An extensive sampling of the resected specimen is essential to identify the PTC component.

CONCLUSION

Fibromatosis involving the thyroid gland is a rare disease and poses a diagnostic challenge for the treating clinician and the pathologist. It presents as a locally invasive thyroid mass and depending upon the extent of the disease may be misdiagnosed as multinodular goiter, thyroid malignancy or Riedel's thyroiditis. A high index of suspicion and multi-departmental coordination are essential to reach a correct diagnosis at the time of initial presentation and workup.

Acknowledgments

The authors would like to thank Lilac Insights Private Limited, Navi Mumbai, India for performing the molecular analysis of the case.

Ethical Consideration

Patient consent was obtained before the submission of the manuscript.

Statement of Authorship

The authors certified fulfillment of the ICMJE authorship criteria.

CRedit Author Statement

BKS: Conceptualization, Investigation, Writing – original draft preparation. **SC:** Conceptualization, Writing – original draft preparation. **YSR:** Conceptualization, Writing – review and editing. **SA:** Conceptualization, Writing – review and editing. **SR:** Conceptualization, Writing – review and editing. **VS:** Conceptualization, Writing – review and editing, Supervision.

Author Disclosure

The authors declared no conflict of interest.

Funding Source

None.

References

- Haugen BR, Alexander EK, Bible KC, et al. 2015 American Thyroid Association management guidelines for adult patients with thyroid nodules and differentiated thyroid cancer: The American Thyroid Association Guidelines Task Force on thyroid nodules and differentiated thyroid cancer. *Thyroid*. 2016;26(1):1-133. PMID: 26462967. PMCID: PMC4739132. <https://doi.org/10.1089/thy.2015.0020>
- WHO Classification of Tumors Editorial Board. Soft tissue and bone tumors. WHO Classification of Tumours, 5th ed. Lyon, France: International Agency for Research on Cancer (IARC), 2020.
- Schwarzlmüller B, Hofstädter F. Fibromatosis of the thyroid gland region. An electron-microscopic and enzyme-histochemical study. *Virchows Arch A Pathol Anat Histol*. 1978;377(2):145-55. PMID: 147558. <https://doi.org/10.1007/bf00427002>
- Sinha AN, Rao AS, Sinha A, Arora R. Fibromatosis of thyroid gland – A case report. *Indian J Otolaryngol Head Neck Surg*. 1998;50(4):385-6. PMID: 23119466. PMCID: PMC3451430. <https://doi.org/10.1007/bf03000695>
- Samsi AB, Shah HK, Vaidya A, Pai PR, Deshmane U, Sane SY. Fibromatosis of thyroid gland (a case report). *J Postgrad Med*. 1992;38(1):36-7. PMID: 1512725.
- Simões-Pereira J, Cabrera RA, Leite V. A case of thyroid fibromatosis, a rare lesion of this gland. *Endocrinol Diabetes Metab Case Rep*. 2016;2016:16-0019. PMID: 27855230. PMCID: PMC5093403. <https://doi.org/10.1530/edm-16-0019>
- Mehdizadeh B, Gharib M. Thyroid fibromatosis: A case report. *Endocr Regul*. 2020;54(2):133-6. PMID: 32597156. <https://doi.org/10.2478/enr-2020-0016>
- Zhang Z, Shi J, Yang T, Liu T, Zhang K. Management of aggressive fibromatosis. *Oncol Lett*. 2021;21(1):43. PMID: 33262835. PMCID: PMC7693298. <https://doi.org/10.3892/ol.2020.12304>
- Gronchi A, Colombo C, Le Péchoux C, et al; ISG and FSG. Sporadic desmoid-type fibromatosis: A stepwise approach to a non-metastasising neoplasm – A position paper from the Italian and the French Sarcoma Group. *Ann Oncol*. 2014;25(3):578-83. PMID: 24325833. PMCID: PMC4433504. <https://doi.org/10.1093/annonc/mdt485>
- de Bree E, Zoras O, Hunt JL, et al. Desmoid tumors of the head and neck: A therapeutic challenge. *Head Neck*. 2014;36(10):1517-26. PMID: 24421052. <https://doi.org/10.1002/hed.23496>
- Gounder MM, Mahoney MR, Van Tine BA, et al. Sorafenib for advanced and refractory desmoid tumors. *N Engl J Med*. 2018;379(25):2417-28. PMID: 30575484. PMCID: PMC6447029. <https://doi.org/10.1056/NEJMoa1805052>
- Papi G, Corrado S, Carapezzi C, De Gaetani C, Carani C. Riedel's thyroiditis and fibrous variant of Hashimoto's thyroiditis: A clinicopathological and immunohistochemical study. PMID: 12906372. *J Endocrinol Invest*. 2003;26(5):444-9. <https://doi.org/10.1007/BF03345200>
- Rebecchini C, Nobile A, Piana S, et al. Papillary thyroid carcinoma with nodular fasciitis-like stroma and β -catenin mutations should be renamed papillary thyroid carcinoma with desmoid-type fibromatosis. *Mod Pathol*. 2017;30(2):236-45. PMID: 27713418. <https://doi.org/10.1038/modpathol.2016.173>

Authors are required to accomplish, sign and submit scanned copies of the JAFES Author Form consisting of: (1) Authorship Certification, that authors contributed substantially to the work, that the manuscript has been read and approved by all authors, and that the requirements for authorship have been met by each author; (2) the Author Declaration, that the article represents original material that is not being considered for publication or has not been published or accepted for publication elsewhere, that the article does not infringe or violate any copyrights or intellectual property rights, and that no references have been made to predatory/suspected predatory journals; (3) the Author Contribution Disclosure, which lists the specific contributions of authors; (4) the Author Publishing Agreement which retains author copyright, grants publishing and distribution rights to JAFES, and allows JAFES to apply and enforce an Attribution-Non-Commercial Creative Commons user license; and (5) the Conversion to Visual Abstracts (*optional for original articles only) to improve dissemination to practitioners and lay readers. Authors are also required to accomplish, sign, and submit the signed ICMJE form for Disclosure of Potential Conflicts of Interest. For original articles, authors are required to submit a scanned copy of the Ethics Review Approval of their research as well as registration in trial registries as appropriate. For manuscripts reporting data from studies involving animals, authors are required to submit a scanned copy of the Institutional Animal Care and Use Committee approval. For Case Reports or Series, and Images in Endocrinology, consent forms, are required for the publication of information about patients; otherwise, appropriate ethical clearance has been obtained from the institutional review board. Articles and any other material published in the JAFES represent the work of the author(s) and should not be construed to reflect the opinions of the Editors or the Publisher.