

Cecal Perforation in an Adolescent as a Paradoxical Response to Anti-tuberculosis Treatment: A Case Report

Pilarica I. Caguiat-Jo, MD and Germana Emerita V. Gregorio, MD, PhD

Division of Pediatric Gastroenterology, Hepatology and Nutrition, Department of Pediatrics, College of Medicine and Philippine General Hospital, University of the Philippines Manila

ABSTRACT

Paradoxical response to anti-tuberculosis treatment, defined as clinical or radiologic worsening of pre-existing lesions or the development of new lesions while ongoing treatment, poses diagnostic dilemma. Intestinal perforation as a paradoxical response is rare. We report a 10-year-old female who presented with recurrent abdominal pain, anorexia, and bloody diarrhea, and was diagnosed with disseminated tuberculosis. She had marked improvement after one month of anti-tuberculosis treatment but developed a recurrence of initial symptoms on the third month of therapy and was treated for cecal perforation. Histopathology of cecum revealed chronic granulomatous inflammation. The patient improved after the surgery and the resumption of anti-tuberculosis medications. Recognition of paradoxical reactions and differentiating it from drug resistance of other pathology is important as these necessitates different management strategies.

Keywords: paradoxical reaction, intestinal tuberculosis, intestinal perforation, case report

INTRODUCTION

Tuberculosis (TB) remains a global health problem worldwide. According to WHO report 2022, the estimated annual incidence of TB globally was 10.6 million. In our country, the incidence of tuberculosis in 2021 was 650 per 100,000 population.¹

Tuberculosis primarily affects the lungs but can affect any part of the body such as the abdomen. Abdominal tuberculosis accounts for 1 to 3% of TB cases.² It is classified in four forms: peritoneal, hepatic, intestinal, and visceral tuberculosis, the latter involving the liver, spleen, pancreas and genitourinary; however, a combination of these forms can be in any individual patient.³ If two or more organs are involved, it is considered a disseminated tuberculosis.

The Philippine Pediatric Society registry of disease from January 2006 to January 2024, listed 719 of 5,319,463 cases (0.013%) to have tuberculosis involving the intestines, peritoneum, and mesenteric glands (ICD A18.3).⁴

The clinical manifestations of abdominal tuberculosis are varied and generally depend on the form of the disease; and these may include fever, weight loss, abdominal pain and/or distension, ascites, hepatomegaly, diarrhea, bowel obstruction, and abdominal mass.⁵ Once a patient is diagnosed, standard quadruple anti-TB treatment is initiated and given for at least six months. Response to treatment usually occurs after two months manifested as improvement in the reported

Paper presentation – Philippine Society of Pediatric Gastroenterology, Hepatology and Nutrition (PSPGHAN) Fellow's Forum via Zoom, February 14, 2024.

Corresponding author: Pilarica I. Caguiat-Jo, MD
Division of Pediatric Gastroenterology, Hepatology and Nutrition
Department of Pediatrics
Philippine General Hospital
University of the Philippines Manila
Taft Avenue, Ermita, Manila 1000, Philippines
Email: picaguiat@up.edu.ph
ORCID: <https://orcid.org/0009-0009-3542-7526>

symptoms, weight gain, and regression of lymphadenopathy and effusion.⁶

We present a 10-year-old immunocompetent child with disseminated TB who had clinical and radiologic improvement while ongoing treatment but developed cecal perforation on the third month of treatment. This rare phenomenon is considered as a paradoxical reaction to anti-TB treatment.

CASE PRESENTATION

A 10-year-old female was admitted for the second time in our institution with the chief complaint of abdominal pain. Her history started eight months prior with recurrent bloody diarrhea, anorexia, abdominal pain, weight loss, vomiting, and fever with various diagnoses of intestinal amoebiasis, parasitism, and acute appendicitis. She was first admitted in the institution four months before the current admission with the initial impression of lower gastrointestinal bleeding with considerations of either infectious colitis, Meckel's diverticulum, or inflammatory bowel disease. She had complete immunization including BCG. She had an exposure to her grandmother who had pulmonary tuberculosis.

She was eventually diagnosed as disseminated tuberculosis involving the lungs, abdomen (peritoneal, intraabdominal lymph node, liver, spleen, intestinal), and bone based on the chest x-ray and abdominal CT scan findings (Figure 1).

Microbiologic studies confirmed the diagnosis with a positive stool and gastric AFB, and gastric aspirate GeneXpert with no Rifampicin resistance detected. HIV screening tested negative. She was started on Prednisone (2 mg/kg) for miliary TB and quadruple anti-TB medications (Isoniazid 10 mg/kg, Rifampicin 15 mg/kg, Pyrazinamide 30 mg/kg, and Ethambutol 15 mg/kg) but developed drug-induced liver injury with cholestatic jaundice (TB: 3.2 mg/dL; DB: 2.45 mg/dL) and elevated liver enzymes (AST 138 U/L, ALT 92U/L, ALP 141 U/L) 12 days after initiation of treatment. When the jaundice resolved and with decreasing bilirubin (TB: 1.95 mg/dL, DB 1.57 mg/dL) and liver enzymes

(AST 76 U/L, ALT 52 U/L), oral re-challenge to the TB medications were started with serial re-introduction with two-day intervals first with Ethambutol then Isoniazid and Pyrazinamide. She was discharged after one month of hospitalization with marked improvement of her symptoms including the resolution of bloody diarrhea, anorexia, and abdominal pain, and noted weight gain from BMI of 13 kg/m² (wasting) to normal BMI of 15 kg/m². Her home medications included daily doses of Isoniazid (8 mg/kg), Pyrazinamide (30 mg/kg), Ethambutol (16 mg/kg), Vitamin B complex, and Prednisone (2 mg/kg). She was on regular follow-up at the out-patient department, where re-initiation of the four anti-TB treatment was successfully done after five weeks of interruption of anti-TB treatment, which was later progressed to maintenance phase (Isoniazid and Rifampicin). Prednisone was also tapered for four weeks.

The patient was on her third month of anti-TB medications when there was recurrence of non-bloody, non-mucoid diarrhea occurring more than five times per day associated with anorexia. She was initially managed as a case of infectious diarrhea and was given oral Ciprofloxacin for three days. However, there was persistence of the diarrhea with associated pain on defecation and hematochezia later followed by severe, stabbing right lower quadrant pain, aggravated by movement. The persistence of the abdominal pain prompted readmission.

On readmission, she was awake but in pain (pain analogue scale of 9-10/10) not in distress and with normal nutritional status. Pertinent physical examination findings showed soft non-distended abdomen and hypoactive bowel sounds. There was no guarding but with direct and rebound tenderness and positive Rovsing's and obturator signs. Rectal examination was unremarkable.

Diagnostics showed leukocytosis (WBC 11.2) with neutrophilia (89%) but lymphopenia with absolute lymphocyte count of 896. C-reactive protein (192 mg/L) was elevated. Baseline serum albumin was increased (42 g/dL) and urinalysis showed pyuria of +1, WBC 66/HPF, nitrite negative, and

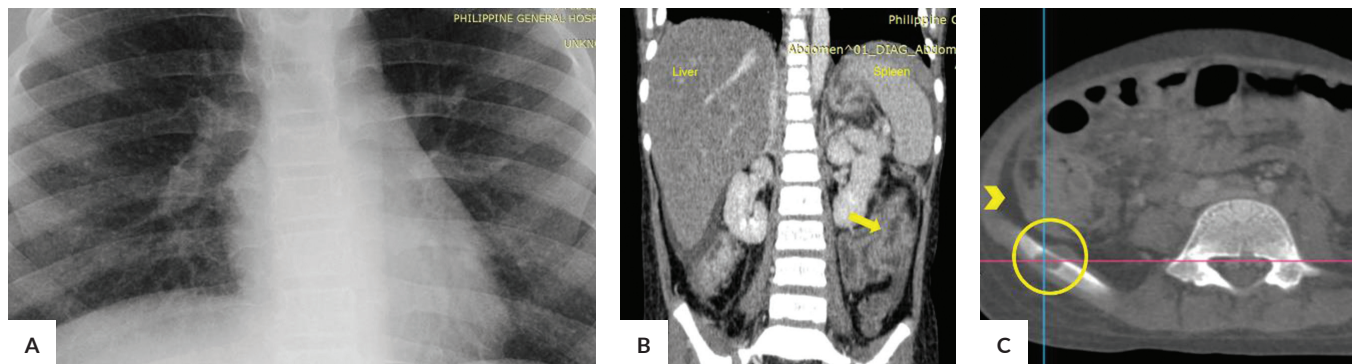


Figure 1. Imaging findings showing disseminated tuberculosis prior to initiation of anti-tuberculosis treatment. (A) Innumerable tiny nodular densities seen scattered throughout both lungs consistent with miliary tuberculosis. (B) Bowel wall thickening (yellow arrow) and hepatosplenomegaly. (C) Ascites (yellow arrowhead) and right iliac tuberculoma (yellow circle).

bacteriuria of 233. Initial abdominal x-ray showed ileus and an ultrasound of the right lower quadrant was suggestive of acute appendicitis with no evidence of rupture. The admitting diagnosis was acute appendicitis and urinary tract infection. Urine culture study and repeat urinalysis done on sixth hospital day yielded negative results. She was referred to the Division of Pediatric Surgery whose assessment was Acute appendicitis, reactive from gastrointestinal tuberculosis with the initial plan of medical management due to high risk of fistula formation among patients with gastrointestinal tuberculosis. She was treated with Ceftriaxone and Metronidazole but developed an adverse drug reaction to both antibiotics with the development of urticaria; and hence these were shifted to Piperacillin-Tazobactam. The abdominal pain decreased in severity and Piperacillin-Tazobactam was continued. The plan was to complete the antibiotics for seven days with plan to repeat CBC, CRP, and abdominal ultrasound.

To further visualize the extent of intraabdominal inflammation, an abdominal CT scan was performed on the patient's third hospital day which revealed acute appendicitis with abscess formation in the perihepatic, perisplenic, paracolic, and pelvic regions; with concomitant findings of ascites and regressing disseminated tuberculosis on imaging (Figure 2).

On her sixth hospital day (on fifth day of antibiotics), feeding was attempted with clear liquids however, there was noted vomiting and bilious output per nasogastric tube, associated with abdominal distension and marked abdominal tenderness. The impression was partial gut obstruction secondary to peritoneal adhesions. She underwent exploratory laparotomy and adhesiolysis. Intraoperatively, 500 ml purulent fluid was drained in the abdominal cavity. There was thickened, edematous ileum with interloop abscesses and fibrin as well as matted omentum and dense adhesions on the ascending colon, cecum, and terminal ileum (Figure 3A).

The appendix was not identified during the operation but within the cecum, a circular 1 cm perforation was observed for which a cecorrhaphy was done (Figure 3B).

Peritoneal abscess culture and sensitivity had moderate growth of *Enterococcus faecium*. Tissue samples taken intraoperatively from the omentum and cecum was read as chronic granulomatous inflammation (Figure 4). No tissue sample was sent for AFB studies, but peritoneal fluid TB culture showed no growth after six weeks of incubation. Post-operatively, Vancomycin was given for the abscess and completed for 14 days while the Piperacillin-Tazobactam was completed for 21 days. Repeat TB workups (stool, urine, and gastric AFB, and chest x-ray) all showed negative results. She was discharged improved after feeding progression was done and the anti-tuberculosis medications (Isoniazid and Rifampicin) were resumed.

DISCUSSION

We present a 10-year-old immunocompetent female with a rare paradoxical response to anti-tuberculosis treatment presenting as recurrence of the initial gastrointestinal symptoms of abdominal pain and bloody diarrhea on the third month of medications. She was eventually diagnosed to have cecal perforation. To date, there are only four cases of intestinal perforation as a paradoxical response to anti-TB treatment; reported from Hongkong,⁷ Nepal,⁸ Pakistan,⁹ and Maryland, USA,¹⁰ which was a migrant from Saudi Arabia (Table 1) and no such case has been reported locally.

Abdominal tuberculosis accounts for only 1% to 3% of tuberculosis cases and among these, 18 to 20% involves the intestine.¹¹ Complications of intestinal TB include obstruction, fistula formation and rarely, intestinal perforation which is seen in 4 to 7%;¹² with the associated mortality rate as high as 30%.¹³ Intestinal perforation secondary to

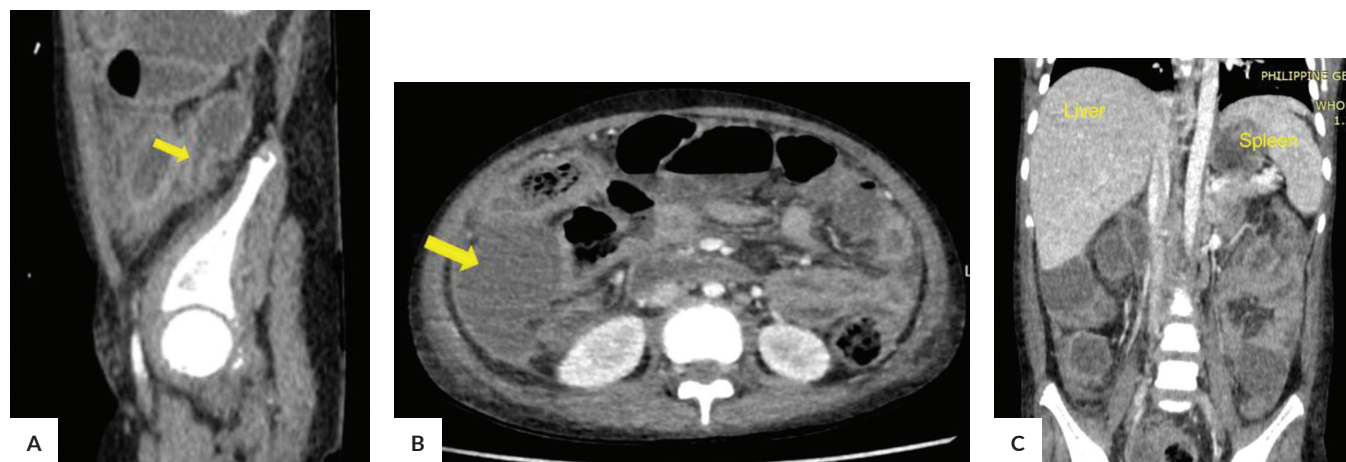


Figure 2. Abdominal CT scan findings taken on the third month of anti-TB treatment showing (A) Dilated appendix (yellow arrow), (B) Peripherally enhancing intraperitoneal fluid collection, suggestive of abscess formation (yellow arrow), (C) Signs of improvement such as regressing peritonitis, regressing liver, spleen, and lymph node sizes.

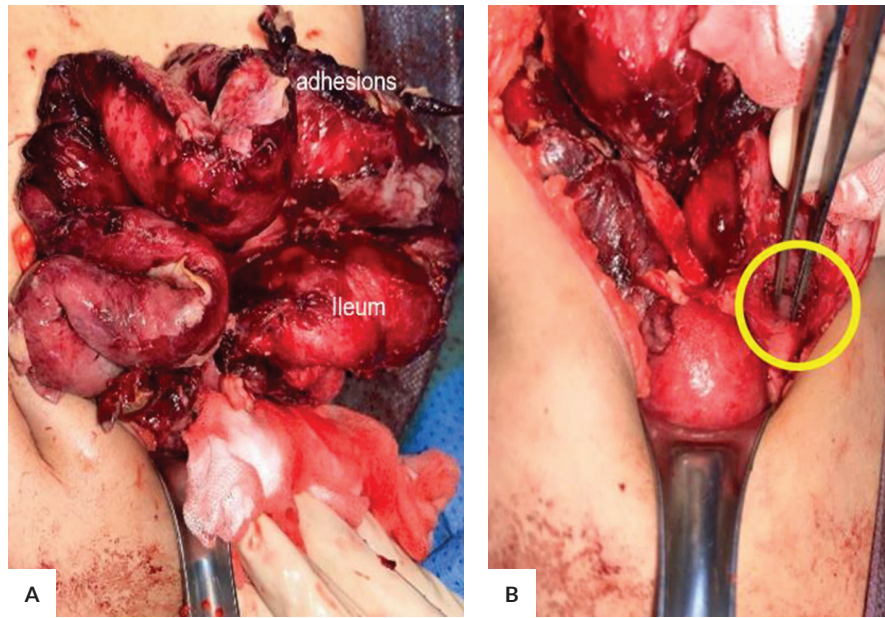


Figure 3. Intraoperative findings of (A) thickened edematous ileum, and (B) cecal perforation (yellow circle).

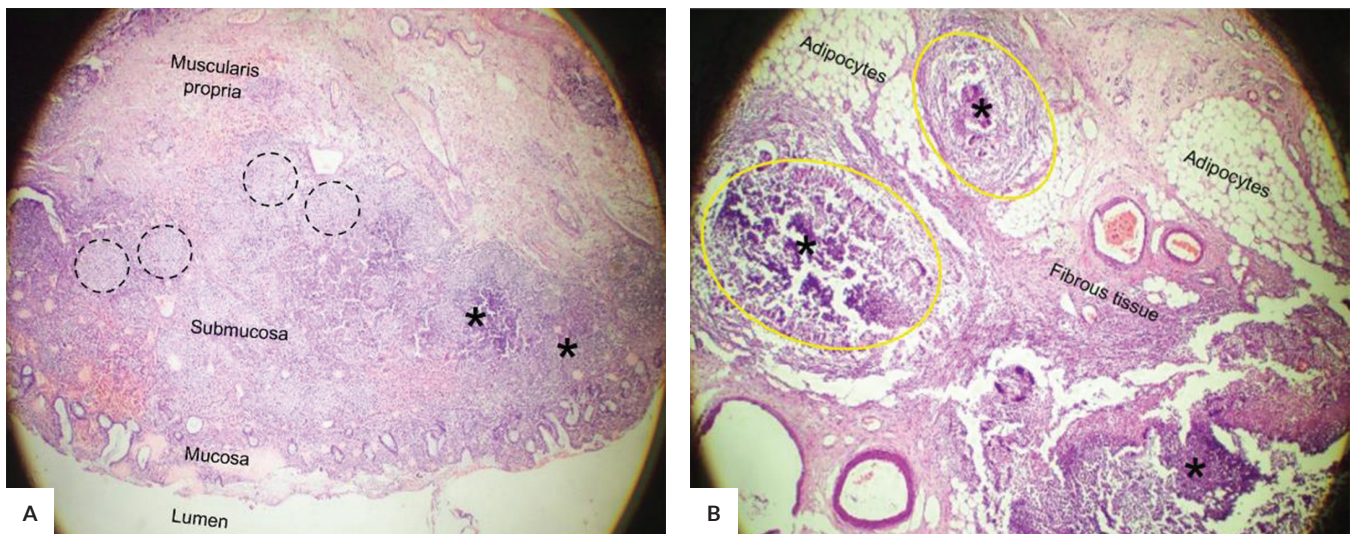


Figure 4. Histopathology of the (A) Cecum. The submucosa has been effaced by discrete nodules of histiocytes (dashed circles) with darker areas suggestive of caseation necrosis (asterisks) (H/E stain; 20x magnification). (B) Omentum. There are discrete nodules (yellow circles) with more distinct areas of necrosis expanding the fibrous areas of the omentum, which can be compatible with chronic granulomatous inflammation (H/E stain; 20x magnification).

TB usually occurs before initiation or at the beginning of anti-TB treatment¹⁴ and this may represent natural progression of the disease. However, a paradoxical reaction is suspected if the intestinal perforation occurs during or after treatment in those with initial improvement before the occurrence of perforation¹¹ as observed in our patient.

Paradoxical reactions are characterized by clinical or radiological worsening of pre-existing tuberculous lesions or the development of new lesions in a patient who initially

improves with anti-tuberculosis treatment.^{12,15,16} These reactions were previously believed to be only in patients with HIV co-infection but were also noted to occur in HIV-negative patients as well.

The pathogenesis of paradoxical reactions is not yet fully elucidated. One possible mechanism is the strengthened delayed hypersensitivity of the host due to increased exposure to mycobacterial antigens released from the bacilli that were killed due to effective TB treatment.¹⁷ Another theory

is the role of tumor necrosis factor-alpha which have been associated with cases of paradoxical responses to anti-tuberculosis treatment among Crohn's disease patients with active tuberculosis infection upon discontinuation of tumor necrosis factor-alpha treatment.¹⁸

In a review of 120 episodes of paradoxical reactions in adults, 75% of patients had worsening of their primary lesions, and approximately 25% developed new lesions at other sites.¹⁴ Our patient initially had clinical improvement after initiating anti-TB medication then later showed recurrence of bloody diarrhea and abdominal pain with noted development of abscess formation and intestinal perforation.

Paradoxical reactions in children are mostly reported in isolated cases. The incidence of paradoxical reactions in children range from 3.3% (33 of 1000) as reported in India¹⁹ to 14% (15 of 110) in Canada.²⁰ In these studies, the timing of onset of paradoxical reactions was a mean of 3.5 (2-11) months¹⁹ in India and median of 39 to 80 days from studies²⁰⁻²² in Canada, Belgium, and Spain. Our patient had a recurrence of symptoms after three months. There is no local published study on paradoxical reactions to anti-tuberculosis treatment, but this might be underreported.

Two studies^{20,21} in children identified gastrointestinal manifestations as paradoxical responses. In a report of 110 children from Canada, 15 had paradoxical reaction and three had gastrointestinal manifestations: two developed abdominal masses and stricture, one of whom required ileocolic resection due to stricture formation and bowel obstruction. The other had abdominal pain and satiety and found to have new abdominal lymphadenopathy and thickened large bowel on CT scan. In another study of 115 children from Belgium, one of 12 patients with paradoxical reactions had developed

new lesions at the intraabdominal area but the details were not discussed. Intestinal perforation as seen in our case has been described in four case reports (Table 1) and the sites included the terminal ileum,⁷ duodenum, cecum,⁹ and an unspecified area of the small bowel,¹⁰ occurring between 3 weeks and 7 months after treatment. Of the four, two also had disseminated tuberculosis, akin to our patient.

For paradoxical reactions, there is no single diagnostic test, and the diagnosis relies primarily on recognition of the sequential relationship between initiation of anti-TB therapy and clinical deterioration.²³ A diagnosis of paradoxical reactions occurs within three months of anti-TB initiation while that occurring four months or more after intake of anti-TB medications may be attributable to treatment failure or multi-drug resistance.²⁴ For ancillary tests, elevated CRP as well as worsening of imaging findings can be suggestive as seen in our patient.²³

The differential diagnoses of paradoxical reactions include incorrect diagnosis, treatment failure due to drug resistance, poor drug compliance, or presence of other disease conditions⁸ that can explain the patients' clinical deterioration. Our patient's clinical timeline, showing the sequential relation between TB treatment initiation and clinical worsening, as well as the ancillary diagnostics, were most compatible with paradoxical response to anti-TB therapy.

In three of four pediatric studies of paradoxical reactions, noted risk factors were multiple sites of disease at diagnosis,^{20,21} weight-for-age ≤ 25 percentile,²⁰ age < 3 years,²¹ and male sex¹⁸ (Table 2). Two of these risk factors, namely multiple sites of disease at diagnosis and an initial weight-for-age ≤ 25 percentiles were both seen in our patient.

Table 1. Reported Cases of Intestinal Perforation as Paradoxical Reactions to Anti-tuberculosis Treatment

Patient	1 ⁷	2 ⁸	3 ⁹	4 ¹⁰	Case
Age	13 years	14 years	18 years	18 months	10 years
Gender	Female	Male	Female	Male	Female
HIV status	Negative	Negative	Negative	Negative	Negative
TB site	Disseminated (pulmonary, intestinal, urinary tract)	Abdominal	Abdominal	Disseminated (lymph node, intestinal)	Disseminated (pulmonary, intestinal, lymph node, bone)
Comorbidities	IL-12 deficiency	None	None	None	None
Anti-TB treatment	Isoniazid, Pyrazinamide, Ethambutol, Rifampicin	Unknown	Unknown	Isoniazid, Pyrazinamide, Ethambutol, Rifampicin	Isoniazid, Pyrazinamide, Ethambutol, Rifampicin
Given steroids	No	No	No	No	No
Time from treatment to perforation	4 months	4 months	7 months	4 weeks	3 months
Perforation site	Terminal ileum	Duodenum	Cecum	Small bowel (site not specified)	Cecum
Surgery	Right hemicolectomy with ileostomy and colostomy	Tube duodenostomy	Right hemicolectomy with side-to-side anastomosis	Repair of perforation	Repair of perforation
Outcome	Recovered	Death	Recovered	Recovered	Recovered

Table 2. Comparison of the Studies of Paradoxical Reactions to Anti-tuberculosis Treatment in Children

Study	Thampi ²⁰ (2012)	Olive ²¹ (2013)	Shah ¹⁹ (2016)	Gallego ²² (2016)
Country	Canada	Belgium	India	Spain
Number of patients	110	115	1000	51
# of PR (%)	15 (14%)	12 (10.3%)	33 (3.3%)	5 (9.8%)
Median age (range)	13 years (2.4 months-17 years)	26 months (5 months -5 years)	-	2.6 years (1.6-7.2)
Male: Female	8:7	5:7	21:12	3:2
Initial TB diagnosis, PTB: EPTB	9:6	9:3	16:17	4:2
Median age of onset of PR (range)	80 days (10-181 days)	39 days (15-75 days)	-	42 days (23-53 days)
Mean age of onset of PR (range)	-	-	3.5 months (2-11 months)	-
Identified risk factors for PR	Weight-for-age <25 th percentile (p=0.03); >1 site of involvement (p=0.02)	Age <3 years old (p=0.026); Involvement of multiple sites (p=0.05)	Male sex	None identified
Most common PR manifestation (%)	Respiratory signs and symptoms such as cough, wheezing, dyspnea, stridor (40%)	Respiratory signs and symptoms such as cough, stridor, wheezing, adenopathy, dullness (50%)	Mediastinal lymphadenopathy (36.4%) Tuberculoma (24.2%) Serositis (15.2%)	Fever and cough (40%)
Gastrointestinal manifestation as PR	Bowel obstruction (13.3%); Increased intraabdominal lymphadenopathy (20%)	Worsening of intraabdominal lesions (8.3%)	None identified	None identified
Steroid use for PR management (%)	9 (60%)	6 (50%)	26 (79%)	5 (100%)

PR – paradoxical reactions, PTB – pulmonary tuberculosis, EPTB – extra-pulmonary tuberculosis

Patients with multiple sites of disease at presentation has four times increased risk to deteriorate during treatment than those with localized disease. This may be related to the severe inflammatory response following effective therapy because of higher antigen load.²⁰ The association of low weight-for-age and occurrence of paradoxical reactions is not yet fully understood though this might be related to immune reconstitution after improvement in the patient's well-being during the initiation of treatment.¹⁶ Other risk factors observed in adults included young age (19.2 ± 3.4), high serum albumin (3.7 ± 0.4g/dL), peripheral lymphadenopathies, absolute lymphocyte count less than 1000/mm³, and a hemoglobin concentration less than 10.5g/dL.^{17,25} Our patient also had an elevated albumin (42g/dL) and lymphopenia (with absolute lymphocyte count of 896).

There is no standard management for paradoxical reactions. Clinical observation is indicated, resuming the same anti-TB regimen, and initiating corticosteroid therapy, if warranted.²¹ In case series, steroid therapy (0.5-2 mg/kg/day for 2 weeks, then tapered in 4 to 6 weeks) was initiated in 50-100% of the cases of paradoxical reactions. Indications for steroid use included severe clinical deteriorations such as airway compression from thoracic lymphadenopathy, new abdominal masses or strictures, worsening pleural/abdominal disease, pericardial effusion, and CNS tuberculoma.²⁰

The management of tuberculosis-associated intestinal perforations is mainly surgical with resection of the involved segment followed by end-to-end anastomosis. Primary closure of the intestinal perforation was not recommended

because of the high rate of leaks and fistula formation.¹⁵ In a case series of 11 adult patients with intestinal perforation as paradoxical reaction to anti-tubercular therapy, majority underwent segmental intestinal resection and right hemicolectomy.¹² In the four pediatric case reports of intestinal perforation as paradoxical responses, all underwent surgery, the anti-TB medications were resumed and none received steroids. Three of the four patients recovered but one died of respiratory complications.

Our patient had cecorrhaphy and she tolerated the procedure well with no post-operative complications. The anti-tuberculosis medications were continued eight days post-operatively and she was discharged after completing intravenous antibiotics. Currently, she has completed twelve months of anti-tuberculosis treatment, with complete resolution of symptoms. She regained her pre-morbid weight and she is back in school, living a normal adolescent life. Her family members were screened negative for tuberculosis.

CONCLUSION

We described a rare case of a Filipino adolescent who developed cecal perforation as a paradoxical response to anti-TB medications. She improved after cecorrhaphy and resumption of her anti-TB treatment. Paradoxical reactions should be suspected in patients who develop reappearance of symptoms after initial improvement within the first three months after anti-TB treatment.

Acknowledgments

The authors would like to thank the Department of Laboratories for the photomicrographs of the histopathology slides, Department of Radiology, and the Division of Pediatric Surgery for the pictures of imaging studies. The authors would also like to thank the Philippine Society of Pediatric Gastroenterology, Hepatology and Nutrition (PSPGHAN) for allowing this case to be presented in the PSPGHAN Fellows' Forum, and Dr. Maria Liza Antoinette M. Gonzales and Dr. Esther A. Saguil for being the reactors in the forum.

Informed Consent and Patient Perspective

Consent from the patient was secured prior to the reporting of this case. The patient and her mother both expressed gratitude to Philippine General Hospital for her good clinical outcome.

Statement of Authorship

Both authors certified fulfillment of ICMJE authorship criteria.

Author Disclosure

Both authors declared no conflicts of interest.

Funding Source

None.

REFERENCES

- World Health Organization, Global tuberculosis report 2022 [Internet]. 2013 [cited 2023 Jul]. Available from: <https://www.who.int/teams/global-tuberculosis-programme/tb-reports/global-tuberculosis-report-2022>.
- Sheer TA, Coyle WJ. Gastrointestinal tuberculosis. *Curr Gastroenterol Rep.* 2003;5(4):273-8. doi: 10.1007/s11894-003-0063-1. PMID: 12864956.
- Debi U, Ravisankar V, Prasad KK, Sinha SK, Sharma AK. Abdominal tuberculosis of the gastrointestinal tract: Revisited. *World J Gastroenterol.* 2014; 20(40):14831-40. doi: 10.3748/wjg.v20.i40.14831. PMID: 25356043.
- Philippine Pediatric Society, Inc. ICD 10 Registry [Internet]. 2024 [cited 2024 Feb 5]. Available from: <https://pps.org.ph/icd-10-registry/>
- UpToDate, Abdominal tuberculosis. [Internet]. 2023 [cited 2023 Jul]. Available from: https://www.uptodate.com/contents/abdominal-tuberculosis?search=abdominal%20tuberculosis&topicRef=8007&source=see_link#H7875348
- Jorstad MD, Dyrhol-Riise A, Abmus J, Marijani M, Sviland L, Mustafa T. Evaluation of treatment response in extrapulmonary tuberculosis in a low-resource setting. *BMC Infect Dis.* 2019;19:426. doi: 10.1186/s12879-019-4034-z. PMID: 31096926; PMID: PMC6524265.
- Law S, Chiu S, Li K. Intestinal tuberculosis complicated with perforation during anti-tuberculous treatment in a 13-year-old girl with defective mitogen-induced IL-12 production. *J Microbiol Immunol Infect.* 2014;47:441-46. doi: 10.1016/j.jmii.2012.06.004. PMID: 22841619.
- Qureshi A, Khan H, Gondal K. Duodenal perforation in a 14-year-old boy with abdominal tuberculosis despite being on antituberculous treatment. *Indian J Surg.* 2010;72:69-70. doi: 10.1007/s12262-010-0015-6. PMID: 23133210; PMID: PMC3452556.
- Prasai P, Joshi A, Poudel S, Sarjan KC, Pahari, R. Cecal perforation following intraperitoneal abscess after antitubercular therapy: a case report. *J Nepal Med Assoc.* 2023;61(258):175-78. doi: 10.31729/jnma.8042. PMID: PMC10088985; PMID: 37203965.
- Troch R, Kochis S, Milstone A, Jain S, Lederman H, Sick-Samuels AC. Fever and an abdominal mass in an 18-month-old boy. *Pediatr Rev.* 2020;41(Suppl 1):94-7. doi: 10.1542/pir.2018-0312. PMID: 33004595; PMID: PMC7670867.
- Rodenas-Sabico EG, Gregorio GE, Gonzales MA. Ten-year retrospective study on the clinical features and outcomes of pediatric intestinal tuberculosis admitted in UP-Philippine General Hospital. *Acta Med Philipp.* 2020;54(2):128-33. doi: 10.47895/amp.v54i2.1522.
- Golden M, Vikram H. Extrapulmonary tuberculosis: an overview. *Am Fam Physician.* 2005;72:1761-8. PMID: 16300038.
- Kang S, Moon H, Park J, Kim JS, Kang SH, Lee ES, et al. Intestinal perforation as a paradoxical reaction to antitubercular therapy: a case report. *Ann Coloproctol.* 2021;37(Suppl 1):S18-23. doi: 10.3393/ac.2020.03.16.1. PMID: 32674552; PMID: PMC8359699.
- Lee MJ, Cresswell FV, John L, Davidson RN. Diagnosis and treatment strategies of tuberculous intestinal perforations: a case series. *Eur J Gastroenterol Hepatol.* 2012;24:594-9. doi: 10.1097/MEG.0b013e328350fd4a. PMID: 22293329.
- Leung VK, Chu W, Lee VH, Chau TN, Law ST, Lam SH. Tuberculous intestinal perforation during anti-tuberculous treatment. *Hong Kong Med J.* 2006;12(4):313-5. PMID: 16912360.
- Cheng VC, Ho PL, Lee RA, Chan K, Woo P, Lau S, et al. Clinical spectrum of paradoxical deterioration during anti-tuberculosis therapy in non-HIV-infected patients. *Eur J Clin Microbiol Infect Dis.* 2002;21:803-9. doi: 10.1007/s10096-002-0821-2. PMID: 12461590.
- Jung JW, Shin JW, Kim JY, Park IW, Choi BW, Seo JS, et al. Risk factors for development of paradoxical response during anti-tuberculosis treatment in HIV-negative patients with pleural tuberculosis. *Tohoku J Exp Med.* 2011;223:199-204. doi: 10.1620/tjem.223.199. PMID: 21372521.
- Unlu M, Cimen P, Ayranci A, Akarca T, Karaman O, Dereli MS. Disseminated tuberculosis infection and paradoxical reaction during antimycobacterial treatment related to TNF-alpha blocker agent infliximab. *Respir Med Case Rep.* 2014;13:43-7. doi: 10.1016/j.rmcr.2014.09.005. PMID: PMC4246353; PMID: 26029559.
- Shah I, Bhaskar MV. Paradoxical reactions in children with tuberculosis. *Trop Doct.* 2016;0(0):1-5. doi: 10.1177/0049475516676388. PMID: 27838632.
- Thampi N, Stephens D, Rea E, Kitai I. Unexplained deterioration during antituberculous therapy in children and adolescents: clinical presentation and risk factors. *Pediatr Infect Dis J.* 2012;31:129-33. doi: 10.1097/INF.0b013e318239134c. PMID: 22016079.
- Olive C, Mouchet F, Toppet V, Haelterman E, Levy J. Paradoxical reaction during tuberculosis treatment in immunocompetent children: clinical spectrum and risk factors. *Pediatr Infect Dis J.* 2013;32:446-49. doi: 10.1097/INF.0b013e3182846c4e. PMID: 23271443.
- Gallego BC, Moreno-Perez D, Cuadros EN, Fernandez AM, Cantero MM, Pacheco PO, et al. Paradoxical reaction in immunocompetent children with tuberculosis. *Int J Infect Dis.* 2016;51:15-8. doi: 10.1016/j.ijid.2016.08.009. PMID: 27544714.
- Quinn C, Poplin V, Kasibante J, Yuquimpo K, Gakuru J, Cresswell FV, et al. Tuberculosis IRIS: pathogenesis, presentation, and management across the spectrum of disease. *Life.* 2020;10(0262):1-26. doi: 10.3390/life10110262. PMID: 33138069; PMID: PMC7693460.
- Blumberg HM, Burman WJ, Chaisson RE, Daley CL, Etkind SC, Friedman LN, et al. American Thoracic Society/Centers for Disease Control and Prevention/Infectious Diseases Society of America: Treatment of tuberculosis. *Am J Respir Crit Care Med.* 2003;167:603-62. doi: 10.1164/rccm.167.4.603. PMID: 12588714.
- Geri G, Passeron A, Heym B, Arlet JB, Capron L, Ranque B. Paradoxical reactions during treatment of tuberculosis with extrapulmonary manifestations in HIV-negative patients. *Infection.* 2013;41:537-43. doi: 10.1007/s15010-012-0376-9. PMID: 23203899.