

A Focal Form of Diazoxide-resistant Congenital Hyperinsulinism with Good Response to Long-acting Somatostatin

Suhaimi Hussain,¹ Nurshafinaz Salmah Mohd Fezal,¹ Sarah Flanagan²

¹Department of Pediatrics, Hospital Universiti Sains Malaysia, Kota Bharu Kelantan, Malaysia
²Exeter University United Kingdom

Abstract

A four-year-old female who was born term via spontaneous vaginal delivery (SVD) with a birth weight of 3.4 kg had an onset of persistent hypoglycaemia at the 6th hour of life. She was diagnosed with congenital hyperinsulinism based on high glucose load, negative ketone and a good response to glucagon. Genetic workup revealed the presence of ATP Binding Cassette Subfamily C Member 8 (ABCC8 genes) mutation which indicated a focal form of congenital hyperinsulinism. She was resistant to the standard dose of oral diazoxide but responded to subcutaneous somatostatin. At the age of 3 years and 6 months, multiple daily injections of somatostatin were replaced with a long-acting monthly somatostatin analogue. With the present treatment, she had better glycaemic control, normal growth and was able to stop tube feeding.

Key words: congenital hyperinsulinism, hyperinsulinaemic hypoglycaemia, focal congenital hyperinsulinism, somatostatin

INTRODUCTION

Congenital hyperinsulinism (CHI) is the leading cause of persistent or refractory hypoglycaemia in the neonatal period. It is due to mutation in the genes that regulate insulin secretion by the β -cells.¹ Fourteen (14) key genes are responsible for CHI. The most common genetic mutation is the mutation in K_{ATP} channel which is made up of 4 subunits encoded by Potassium Voltage-Gated Channel Subfamily J (KCNJ11) or ATP Binding Cassette Subfamily C Member 8 (ABCC8 genes).² However, only about 40-50% have known genetic mutations and majority of the putative genes have yet to be discovered. Histologically, CHI is classified into either diffuse pancreatic β -cell hyperplasia characterised by diffuse involvement of pancreatic β -cells or focal pancreatic β -cells hyperplasia with only focal β -cell hyperplasia. Familial forms of CHI can exhibit recessive or autosomal dominant patterns of inheritance while the sporadic form is very rare, accounting for about 1 in 30-50000 live births.³

Clinically, CHI can be classified according to treatment response to diazoxide which can be either diazoxide sensitive or resistant.⁴ Diazoxide is the gold standard of treatment for CHI which acts by binding to sulphonylurea receptor 1 (SUR1) on the K_{ATP} channel to suppress insulin release by β -cells. The initial dose is 5 mg/kg/day given in 3 divided doses up to 15-20 mg/kg/day. The most severe side effects are fluid retention, cardiac failure, and pulmonary hypertension.⁵ Hydrochlorothiazide at 7-10 mg/kg/day given in 2 divided doses, is usually added to diazoxide to

prevent fluid retention. Glucagon is recommended in the acute management of persistent hypoglycaemia, and it is used short-term as a key counterregulatory hormone to oppose the effect of excess insulin. Nifedipine is another first-line medication which acts as a calcium channel blocker to prevent calcium influx leading to insulin exocytosis. The recommended dose is 0.25-2.5 mg/kg/day divided into 2-3 doses, however, it is not a preferred choice because of associated hypotension with a dose that exceeds 0.5 mg/kg/day.⁵ Octreotide is used as a second-line medication which is reserved for patients who fail to respond to first-line pharmacological intervention. It is a polypeptide chain with eight amino acids that suppresses insulin release by binding predominantly to somatostatin receptors (SSTRs) 2 and 5. The recommended initial dose is 5 μ g/kg/day given by either subcutaneous injection every 6-8 hours or continuous infusion with a maximal dose of 30-35 μ g/kg/day. The first response to octreotide is hyperglycaemia followed by a blunted effect after 48 hours (tachyphylaxis).⁵ Other potential medications are sirolimus, exendin and glucagon analogue. Sirolimus is an immunosuppressive agent with an anti-proliferative ability which inhibits the mammalian target of rapamycin (mTOR). Its mechanism of action in CHI has not been fully elucidated. The reported side effects are mainly due to immunosuppression and more trials are needed to determine its safety and efficacy in CHI.⁶ Exendin is glucagon-like peptide receptor antagonist that works by reducing cyclic adenosine monophosphate (cAMP) to suppress insulin release. It is a potential medication to prevent fasting hypoglycaemia and protein-induced

hypoglycaemia, but future trials are needed to evaluate its safety and efficacy.⁷ Glucagon for long-term usage is hampered by its poor solubility and stability. A glucagon analogue has been developed in an animal model that may provide potential weekly treatment for CHI.⁸

The standard treatment for the focal form of CHI is surgical resection of the focal site in the pancreas that results in cure of CHI.⁹ Pancreatic surgery for CHI should only be performed in established CHI centres that could perform an 18-F DOPA PET scan to localise the lesion. Due to the complexity of the pancreatic surgery and logistic factors, most of the diazoxide-resistant CHI are treated with short-acting standard octreotide injection that requires multiple injections in a day. We share our experience in the transition of standard octreotide to monthly long-acting somatostatin in a patient with focal CHI.

CASE

This is a case of a 4-year-old female who is the youngest of 2 siblings from a non-consanguineous marriage. Her mother had no history of gestational diabetes. She was born via spontaneous vaginal delivery at 39 weeks age of gestation, with a birth weight of 3.4 kg. Her APGAR score was 9 at 5 minutes, and 10 at 15 minutes. At the 6th hour of life, she was found to be inactive, pale and feeding poorly. Capillary blood glucose was 1.6 mmol/L. An intravenous bolus of D10% 2 ml/kg was administered and the patient was admitted to the intensive care unit for further management. She required multiple dextrose D10% boluses in increasing frequency to maintain a blood sugar level of more than 2.6 mmol/L. No dysmorphism, cleft lip/palate or neurocutaneous signs were observed. Other systemic examinations were unremarkable. Her plasma glucose level was noted to be more stable at about 2.6-3.3 mmol/L only at a glucose infusion rate (GIR) of 15 mg/kg/min, glucagon infusion at 10 mcg/kg/min, and hydrocortisone given at 1mg/kg body weight thrice a day at about 48 hours of life.

During an episode of hypoglycaemia, her urine ketone was negative, c-peptide 0.5 nmol/L, lactate 1.0 mmol/L. The patient was also empirically started on intravenous crystalline penicillin/gentamicin to cover for neonatal sepsis. With the high GIR, negative ketone, good response to glucagon and presence of insulin during hypoglycaemia, she was treated as a case of persistent hypoglycaemia secondary to congenital hyperinsulinism (CHI) or persistent hypoglycaemic hyperinsulinaemia of infancy (PHHI). Oral diazoxide was started at an initial dose of 2 mg/kg/day in 3 divided doses and the dose was increased every 2 days guided by blood sugar trends. Despite being on a high dose of oral diazoxide at 20 mg/kg/day, the patient continued to have intermittent hypoglycaemia, which raised suspicion of the presence of a diazoxide resistance form of CHI. Octreotide at a dose of 8.8 mcg/kg/day was started, and the patient showed a remarkable improvement in the blood sugar pattern. DNA from the patient and both her parents were extracted and sent to Exeter Lab UK for DNA sequencing. She was discharged home at 62 days of life with subcutaneous octreotide injection (10 mcg/kg/day) in divided doses and was advised for home blood glucose monitoring. She was on-demand breastfeeding and infant formula via a feeding tube every 2 hours. Weaning was started at 6 months of life with porridge, biscuits, and bread. She was a picky eater and growth was observed to be at the 3rd- 25th percentile for length and weight in the first 6-7 months of life (Figure 1). In the first year of life, she had 3 hospital admissions for acute gastroenteritis, bronchopneumonia, and viral infection at the age of 3 months, 6 months, and 7 months, respectively. She had more hypoglycaemic episodes whenever she was unwell during hospital admissions. Her octreotide dose was increased to 12 mcg/kg/day to counteract hypoglycaemic episodes. In the first 2 years of life, HbA1C ranged from 3.8 to 5.0 % with an average of 4.5%. DNA sequencing revealed that she is heterozygous for a paternally inherited pathogenic *ABCC8* frameshift variant. Her father has the same mutation, but her mother was negative for the mutation. The genetic variant is

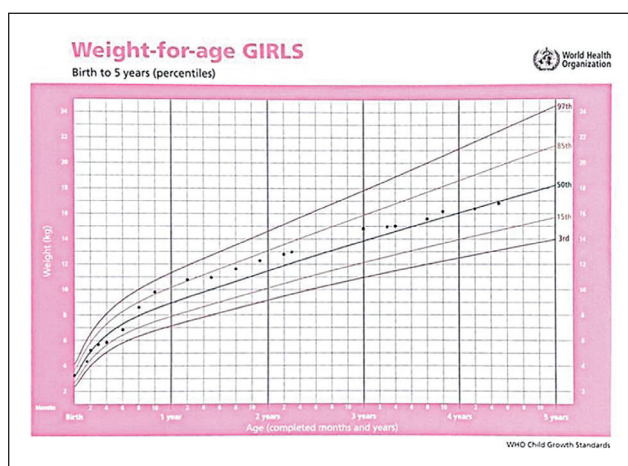


Figure 1. (A) Girls chart: weight-for-age GIRLS [birth to 5 years (percentile)].

https://cdn.who.int/media/docs/default-source/child-growth/child-growth-standards/indicators/weight-for-age/cht-wfa-girls-p-0-5.pdf?sfvrsn=d4a8e3bc_12.

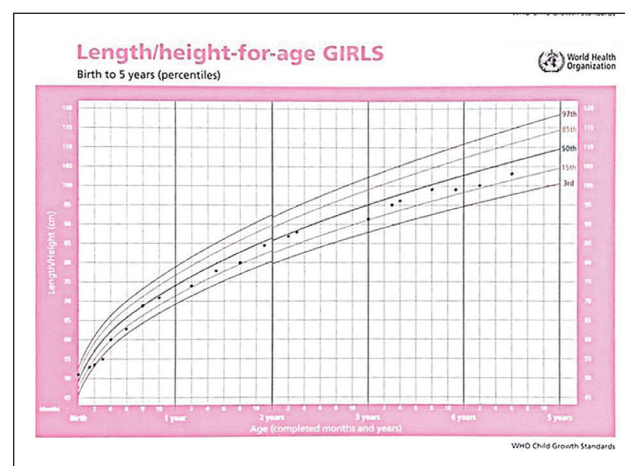


Figure 1. (B) Girls chart: length/height-for-age GIRLS [birth to 5 years (percentile)].

https://cdn.who.int/media/docs/default-source/child-growth/child-growth-standards/indicators/length-height-for-age/cht-lhfa-girls-p-0-5.pdf?sfvrsn=d15415dc_10.

highly correlated with a focal form of CHI. The pancreatic focal lesion should be confirmed with an 18F-DOPA PET scan and pancreatic surgery is recommended to remove the focal lesion and attain a cure of the disease.¹⁰ However, due to the unavailability of the 18-F Dopa and experienced surgeon in CHI, the diagnostic scan and surgery were not possible. Intensive medical therapy with regular tube feeding and somatostatin/octreotide were continued. Neurodevelopmental milestones were fairly on time, with a bit of speech delay. She was able to walk at the age of 12 months, drink with a cup at 11-12 months, and speak in 2-3 word sentences at the age of 3 years old. An intramuscular 10 mg long-acting octreotide/Sandostatin LAR was started monthly in place of subcutaneous short-acting octreotide at the age of 3 years and 6 months old. Subcutaneous octreotide was gradually withdrawn over a period of 3-4 weeks. The patient was able to tolerate monthly injection of Sandostatin. HbA1C was 4.8% with a range of 4.6 to 4.9%. She had no liver transaminitis, IGF-1 was normal for age and there was no gall bladder sludge detected on ultrasound. After about few months on long-acting somatostatin, her parents managed to stop tube feeding and she no longer had food aversion.

DISCUSSION

Somatostatin is a peptide/somatotroph release-inhibiting factor that acts primarily via five transmembrane G-protein coupled SST receptor (SSTR 1-5). SSTR5 is highly expressed in beta cells. SSTR share common signalling pathways such as the inhibition of adenylyl cyclase, activation of phosphotyrosine phosphatase and modulation of mitogen-activated protein kinase through a G-protein dependent mechanism. SSTR 2-5 are coupled to the inward rectifying K channel. The binding of SST to SSTR on the beta cells results in the inhibition of voltage-gated calcium channels and reduces cAMP levels thereby inhibiting insulin release.¹¹

There are two formulations of octreotide/Sandostatin, the regular form and octreotide LAR/long-acting form. Octreotide is an octapeptide with 4 amino acid sequences essential for biological activity. The incorporation of N-phenylalanine, L-terminal amino-alcohol, D-tryptophan and cysteine bridge make them more resistant to peptidase degradation compared to its natural form that has a very short half-life of 3-5 minutes.¹²

The prevalence of CHI is 1 in 50000 live births. Most individuals with CHI respond to first-line treatment with diazoxide and only about 40% are resistant. Eighty to ninety percent of diazoxide-resistant CHI have a mutation in the K_{ATP} channel. Pancreatic β -cells express K_{ATP} channels that are needed for normal insulin secretion and are targets for drugs that modulate insulin secretion. This is made up of 4 subunits encoded by *KCNJ11* or *ABCC8* genes. Inactivating mutations in the genes encoding the two subunits of the ATP-sensitive potassium cause diazoxide-resistant CHI.⁵ Long-acting SST has been used for the treatment of diazoxide-resistant CHI secondary to diffuse form since surgery for diffuse form carries more short-term and long-term complications such as persistent hypoglycaemia,

biliary tree injury, pancreatic fistula, bleeding, hepatic/splenic injury, diabetes, and pancreatic endocrine/exocrine dysfunction.¹³ There are many published studies on the use of long-acting SST in the diffuse form of CHI which showed that it is safe, effective and resulted in improved quality of life. Shah et al., reported an improvement in the quality of life for a patient who experienced severe side effects associated with diazoxide while Novokreshhennyx et al., reported that 67% achieved euglycaemia with a therapeutic dose of lanreotide given at 3.5-5.5 mg/kg/month, without any significant side effects.¹² Ivo van der Steen et al., reported 89 % improvement in blood glucose control without any life-threatening side effects while 37% experienced transient elevation of liver enzymes with the use of long-acting SST.⁵

There are not many publications on the use of long-acting somatostatin in the focal form of CHI. The efficacy of long-acting SST is believed to be related to the expression of SSTR2 in focal pancreatic tissues which would shut off the excessive insulin production after binding to SST.¹⁴ The use of long-acting somatostatin in the focal form has been demonstrated to be safe and effective in a very small number of patients from case reports since the focal form is very rare and a majority of patients were on standard octreotide treatment, and some underwent surgery.¹⁵ It was also used for patients who had failed pancreatic surgery with post-operative hypoglycaemia, and for patients who refused surgical intervention. There were no life-threatening side effects associated with the use of long-acting somatostatin in the focal form of CHI. Our patient is a confirmed case of a focal form of CHI secondary to *ABCC8* gene mutation. An 18F-DOPA PET scan is not available in many countries including Malaysia. To our knowledge, it is only available in certain European countries, the United States and Japan due to the short half-life of radioactive material used in PET scans to localise the focal lesion in CHI. Furthermore, pancreatic surgery for CHI should only be performed in a CHI centre with a high patient load. Our patient has been on long-acting SST for 13 months whereas the patient in the study of Pratik et al., was on the treatment for 7-27 months.¹⁶ We used a brand named Sandostatin since it is easier to obtain compared to lanreotide. Both are SST analogues that are reserved for the treatment of neuroendocrine tumour in adults but in the paediatric population, they are used as an off-label medication for CHI.

There are several complications secondary to SST treatment such as necrotising enterocolitis, abdominal distension, fat malabsorption, gall bladder sludge/stone, liver transaminitis, hypothyroidism and growth impairment. Transient transaminitis and asymptomatic gall bladder sludge are the most prevalent complications.¹⁷ Van der Steen et al., found that 13 out of 27 subjects (48%) had mainly mild to moderate side effects such as pain at the injection site, nausea, vomiting, and diarrhoea. Long-term treatment with SST has been associated with gall bladder stone formation, cholestatic jaundice, and elevated liver enzymes that are reversible after stopping treatment.¹⁸ It is recommended to regularly screen for the side effects secondary to long-term use of octreotide in children. For our patient, she had

a transient increase in liver enzymes with a high dose of SST at the age of about 1-2 years old. The side effects were dose-dependent and later on, the liver enzymes normalised with the reduction of SST doses, optimization of enteral feeding and transition to long-acting SST.

CONCLUSION

The case illustrates that focal CHI may be managed by administering monthly long-acting SST. The use of long-acting SST could result in avoidance of pancreatic surgery which may be associated with short- and long-term complications. It is a good alternative for countries without access to 18F-DOPA PET scans or a high-volume surgeon. This conservative approach seems to achieve acceptable glycaemic control and a better quality of life. It is less stressful to the patient and parents since the injection is only monthly. The side effects are less compared to oral diazoxide and subcutaneous octreotide that require multiple injections a day. This approach would also be more popular since CHI becomes less severe as the patient gets older due to the gradual increase in the rate of focal β -cell apoptosis.¹⁹

Ethical Consideration

Patient consent was obtained before submission of the manuscript.

Statement of Authorship

All authors certified fulfillment of ICMJE authorship criteria.

CRedit Author Statement

SH: Conceptualization, Methodology, Software, Validation, Formal analysis, Investigation, Resources, Data curation, Writing – original draft preparation, Writing – review and editing, Visualization, Supervision, Project Administration, Funding acquisition; **NSMF:** Resources; **SF:** Investigation

Author Disclosure

The authors declared no conflict of interest.

Data Availability Statement

Datasets generated and analyzed are included in the published article.

Funding Source

None.

References

- Senniappan S, Shanti B, Hussain K. Hyperinsulinaemic hypoglycaemia. Genetic mechanisms, diagnosis and management. *J Inher Metab Dis*. 2012;35(4):589–601. PMID: 22231386 DOI: 10.1007/s10545-011-9441-2.
- Galcheva S, Demirbilek H, Al-Khawaga S, Hussain K. The genetic and molecular mechanisms of congenital hyperinsulinism. *Front Endocrinol. (Lausanne)*. 2019;10:111. PMID: 30873120 PMID: PMC6401612 DOI: 10.3389/fendo.2019.00111.
- Mitrofanova, L, Perminova A, Ryzhkova D, Sukhotskaya A, Bairov V, Nikitina. Differential morphological diagnosis of various forms of congenital hyperinsulinism in children. *Front. Endocrinol. (Lausanne)*. 2021;12:710947. PMID: 34497584 PMID: PMC8419459 DOI:10.3389/fendo.2021.710947.
- Sharma R, Roy K, Satapathy A, et al. Molecular characterization and management of congenital hyperinsulinism: A tertiary centre experience. *Indian Pediatr*. 2022;59(2):105-9. PMID: 34992182 PMID: PMC8913199 DOI: 10.1007/s13312-022-2438-0.
- Hussain K, Aynsley-Green A, Stanley CA. Medications used in the treatment of hypoglycaemia due to congenital hyperinsulinism of infancy (HI). *Pediatr Endocrinol Rev*.2004;2(Suppl 1):163-7. PMID: 16456495
- Maria G, Antonia D, Michael A, et al. Sirolimus: Efficacy and complications in children with hyperinsulinemic hypoglycemia: a 5-year follow-up study. *J. Endocr. Soc.* 2019;3(4):699-713. PMID: 30882046 PMID: PMC6411415 DOI: 10.1210/ajs.2018-00417
- Ng CM, Tang F, Seeholzer SH, Zou Y, De León DD. Population pharmacokinetics of exendin-9-39 and clinical dose selection in patients with congenital hyperinsulinism. *Br J Clin Pharmacol*. 2018;84(3):520-32. PMID: 29077992 PMID: PMC5809353 DOI: 10.1111/bcp.13463
- Salomon-Estebanez M, Yau D, Dunne M, et al. Corrigendum: Efficacy of dose-titrated glucagon infusions in the management of congenital hyperinsulinism: A case series. *Front Endocrinol (Lausanne)*. 2020;11:441. PMID: 33013678 PMID: PMC7494759 DOI: 10.3389/fendo.2020.00441. Erratum in: *Front Endocrinol (Lausanne)*. 2020;11:614734. PMID: 33312164
- Dastamani A, Guemes M, Pitfield C, et al. Variation in glycemic outcomes in focal forms of congenital hyperinsulinism - The UK perspective. *J Endocr Soc*. 2022;6(6):bvac033. PMID: 35592516 PMID: PMC9113085 DOI: 10.1210/endso/bvac033.
- States LJ, Christopher Davis J, Hamel SM, Becker SA, Zhuang, H. 18F-6-Fluoro-L-Dopa PET/CT imaging of congenital hyperinsulinism. *J Nucl Med*. 2021;62(Suppl 2):51S-6. PMID: 34230074 DOI: 10.2967/jnumed.120.246033.
- Haris B, Saraswathi S, Hussain K. Somatostatin analogues for the treatment of hyperinsulinaemic hypoglycemia. *Ther Adv Endocrinol Metab*. 2020;11:2042018820965068. PMID: 33329885 PMID: PMC7720331 DOI: 10.1177/2042018820965068
- Novokreshhennyy EE, Gubaeva DN, Melikyan MA. The use of long-acting somatostatin analogs in congenital hyperinsulinism. *Probl Endokrinol (Mosk)*. 2024;66(5):70-8. PMID: 33369374 DOI: 10.14341/probl12654
- Cao B, Di W, Su C, et al. Efficacy and safety of octreotide treatment for diazoxide-unresponsive congenital hyperinsulinism in China. *Pediatr Investig*. 2020;4(1):29-36. PMID: 32851339 PMID: PMC7331369 DOI: 10.1002/ped4.12175
- Melikyan MA, Gubaeva DN, Kareva MA. Continuous subcutaneous infusion of somatostatin analogues in the treatment of congenital hyperinsulinism. *Probl Endokrinol (Mosk)*. 2020;66(3):81-7. PMID: 33351342 DOI: 10.14341/probl12421
- Gubaeva, DN, Melikyan M, Ryzhkova D, et al. Clinical, genetic, and radionuclide characteristics of the focal form of congenital hyperinsulinism. *Probl Endokrinol (Mosk)*. 2019;65(5):319-29. PMID: 32202736 DOI: 10.14341/probl10317
- Dastamani A, Güemes M, Pitfield C, et al. The use of a long-acting somatostatin analogue (Lanreotide) in three children with focal forms of congenital hyperinsulinaemic hypoglycaemia. *Horm Res Paediatr*. 2019;91(1):56–61. PMID: 30114684 DOI: 10.1159/000491101
- Sokolov Y, Melikyan M, Efremenkov A, Gubaeva D, Druzhinin V, Osmanov. Laparoscopic resections of the pancreas in children with hyperinsulinism. *Russ J Pediatr Surg*. 2020;24(6):363-9. <https://jps-nmp.ru/jour/article/view/4/4>.
- van Der Steen I, van Albada ME, Mohnike K, et al. A Multicenter experience with long-acting somatostatin analogues in patients with congenital hyperinsulinism. *Horm Res Paediatr*. 2018;89(2):82-9. PMID: 29241206 DOI: 10.1159/000485184
- Kassem SA, Ariel I, Thornton PS, Scheimberg I, Glaser B. Beta-cell proliferation and apoptosis in the developing normal human pancreas and in hyperinsulinism of infancy. *Diabetes*. 2000;49(8):1325-33. PMID: 10923633 DOI: 10.2337/diabetes.49.8.1325

Authors are required to accomplish, sign and submit scanned copies of the JAFES Author Form consisting of: (1) Authorship Certification, that authors contributed substantially to the work, that the manuscript has been read and approved by all authors, and that the requirements for authorship have been met by each author; (2) the Author Declaration, that the article represents original material that is not being considered for publication or has not been published or accepted for publication elsewhere, that the article does not infringe or violate any copyrights or intellectual property rights; that no references have been made to predatory/suspected predatory journals; and that use of artificial intelligence (AI) or AI-assisted technologies shall be declared to include the name of the AI tool or service used;(3) the Author Contribution Disclosure, which lists the specific contributions of authors; (4) the Author Publishing Agreement which retains author copyright, grants publishing and distribution rights to JAFES, and allows JAFES to apply and enforce an Attribution-Non-Commercial Creative Commons user license; and (5) the Conversion to Visual Abstracts (*optional for original articles only) to improve dissemination to practitioners and lay readers Authors are also required to accomplish, sign, and submit the signed ICMJE form for Disclosure of Potential Conflicts of Interest. For original articles, authors are required to submit a scanned copy of the Ethics Review Approval of their research as well as registration in trial registries as appropriate. For manuscripts reporting data from studies involving animals, authors are required to submit a scanned copy of the Institutional Animal Care and Use Committee approval. For Case Reports or Series, and Images in Endocrinology, consent forms, are required for the publication of information about patients; otherwise, appropriate ethical clearance has been obtained from the institutional review board. Articles and any other material published in the JAFES represent the work of the author(s) and should not be construed to reflect the opinions of the Editors or the Publisher.