

# Intraneural Lipoma of the Median Nerve Causing Carpal Tunnel Syndrome in a 57-year-old Filipino Female: A Case Report



Alfonso Pio P. Calimag, MD,<sup>1</sup> John Hubert C. Pua, MD<sup>1</sup>

## ABSTRACT

A 57-year-old female presented with a history of a progressively enlarging palmar mass over three years, with associated numbness over the median nerve distribution and difficulty in gripping due to dimensions of the mass. Physical examination revealed a 4 x 5 cm, movable, non-tender mass over the thenar eminence and a 2 x 1 cm movable, non-tender mass over the center of the palm. Tinel's sign was positive over the mass and the carpal tunnel.

Excision of the mass was performed under intravenous regional anesthesia. A curvilinear incision made from the thenar crease distally to the midline of the wrist overlying the carpal tunnel, proximally. Dissection was carried down to the transverse carpal ligament which was transected to allow visualization of the mass and its attachment to the median nerve.

The mass described in this present case report shares characteristics from cases in previously published literature. Its gross appearance was highly

indicative of a lipoma and its close relationship with the median nerve suggested an epineural origin. Magnetic resonance imaging revealed a well-defined lesion, suggesting a mass that was more likely to be excised, potentially leading to better neurologic outcomes.

Intraneural lipomas (within the epineurium) are rare soft-tissue tumors that predominantly occur in the hand and forearm. Most cases reported involve the median nerve, followed by the radial nerve, posterior interosseus nerve and more rarely the brachial plexus. Compression of peripheral nerves by benign adipose tumors is infrequently reported in literature, with most publications restricted to case reports or series of a few patients. To the author's knowledge, this is the first article describing an intraneural lipoma in the Filipino population.

**Keywords** Intraneural Lipoma, Carpel Tunnel Syndrome, Peripheral nerves

## INTRODUCTION

Adipose cells are normal components of a peripheral nerve. Excessive adipose tissue around these nerves, however, can result in lesions spanning from simple lipomas associated with the nerve (intraneural lipomas) to lipomatosis of the nerve (formerly known as lipofibromatous hamartomas).[1] Incidence of

Dr. Alfonso Pio P. Calimag  
calimagpio@gmail.com

<sup>1</sup> Department of Orthopaedics, University of Santo Tomas Hospital, Manila, Philippines

Academic editor: Leilani B. Mercado-Asis

Submitted date: February 25, 2024

Accepted date: October 6, 2024

tumors that develop adjacent to peripheral nerves are quite rare and account for 1.02% - 4.9% of all tumors affecting the upper extremity.[2]

Intraneural lipomas (fatty growths enclosed within the epineurium)[1] are rare soft tissue tumors that predominantly arise in the hand and forearm. The majority of reported cases involve the median nerve, with the radial nerve and the posterior interosseus nerve being less involved, and even rarer, the brachial plexus being affected in some cases.[3] Instances of intraneural lipomas compressing peripheral nerves are rarely documented, and have limited data.[2]

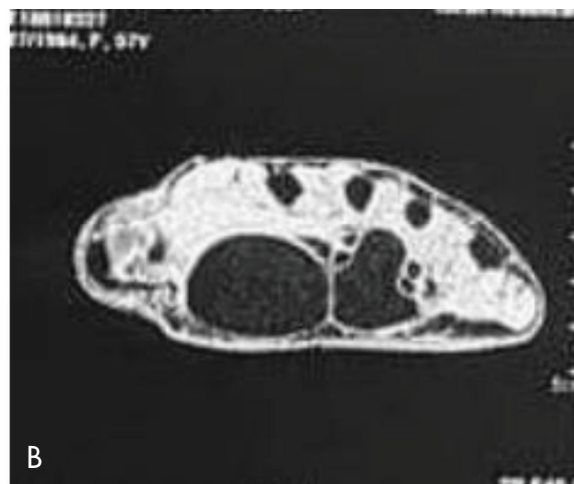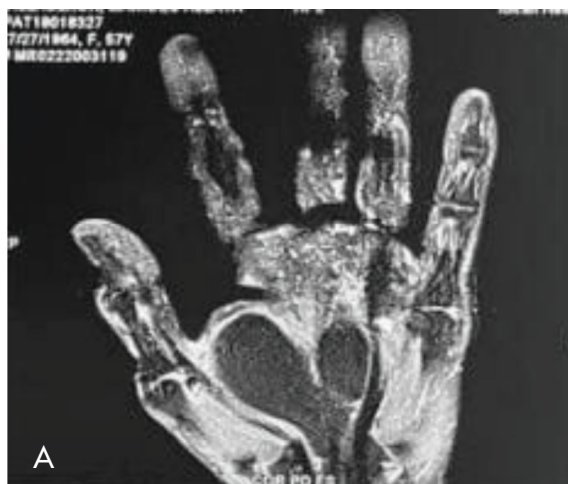It is important to differentiate intraneural lipomas from other adipose tumors that may arise from peripheral nerves, such as lipofibromatous hamartomas, as these tumors have a different relationship to the nerves which may entail excision of the entire segment of the affected nerve. [4]

The purpose of this case report is to present a case of a 57-year-old Filipino female with intraneural lipoma causing symptoms of median nerve compression and the subsequent treatment course.

## CASE REPORT

A 57-year-old female presented with a history of progressively enlarging palmar mass with no history of trauma. A gradual increase in size of the mass was noted over three years with associated numbness over the median nerve distribution and difficulty in gripping due to dimensions of the mass. On physical examination, there was a 4 x 5 cm, movable, non-tender mass over the thenar eminence and a 2 x 1 cm movable, non-tender mass over the center of the palm. She had full range of motion of her digits with a 30% deficit of light touch sensation over the median nerve distribution. Tinel's sign or presence of tingling sensation upon percussion of the volar aspect of the wrist was positive over the mass and carpal tunnel.

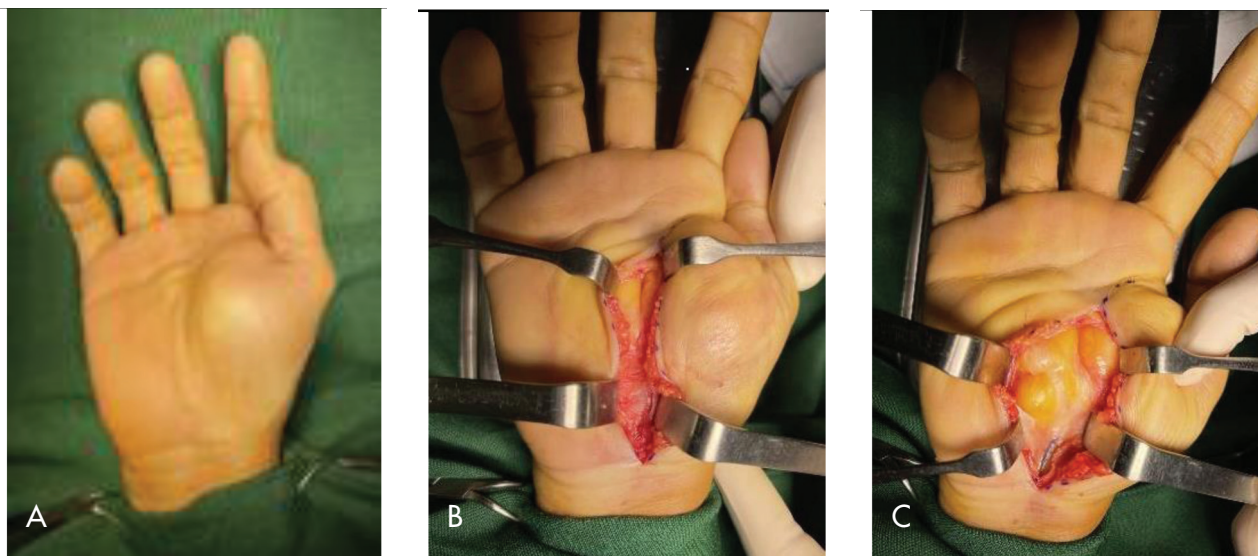
An ultrasound of the mass showed a lipomatous mass extending within the carpal tunnel and a plain MRI of the hand demonstrated a well-demarcated lobulated mass measuring 1.9 x 5.0 x 4.8 cm closely related to and insinuating between the flexor tendons as it extended to the area of the carpal tunnel.



A. (Coronal) T2 - weighted image; and B. (Axial) T2 - weighted image – Multilobulated mass with hypointense signals measuring at 1.9 x 5.0 x 4.8 cm closely related to and insinuating between the flexor tendons as it extended to the area of the carpal tunnel

Excision of the mass was performed under intravenous regional anesthesia. A curvilinear incision made from the thenar crease distally to the midline of the wrist overlying the carpal tunnel,

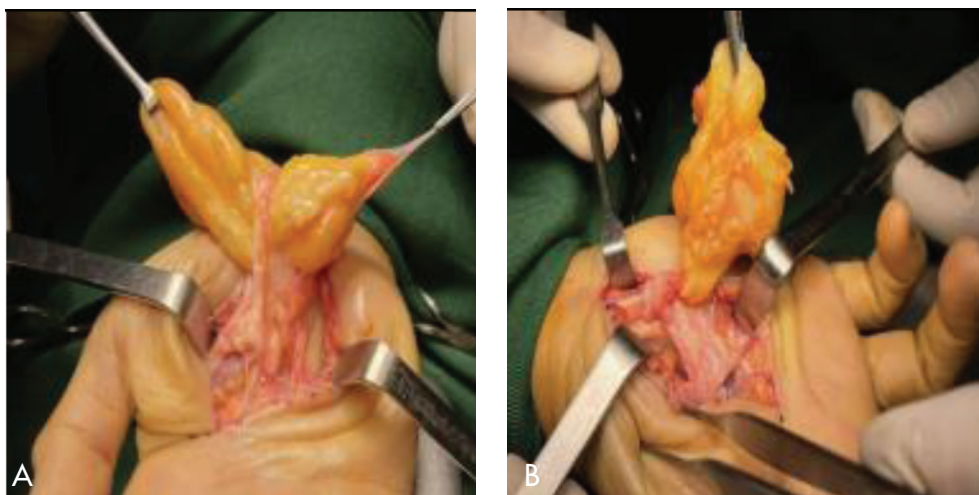
proximally. Dissection was carried down to the transverse carpal ligament, which was transected to allow visualization of the mass and its attachment to the median nerve.



A. Pre-operative gross picture; B Transection of Transverse Carpal Ligament; C. Visualization of Mass

The mass was noted to be intimately related to the epineurium of the median nerve. Careful dissection of the tumor from its median nerve attachments was carried out under microscopic magnification using

surgical loupes by the author and consultant hand surgeon. Identification and preservation of the digital nerve branches were done as well.

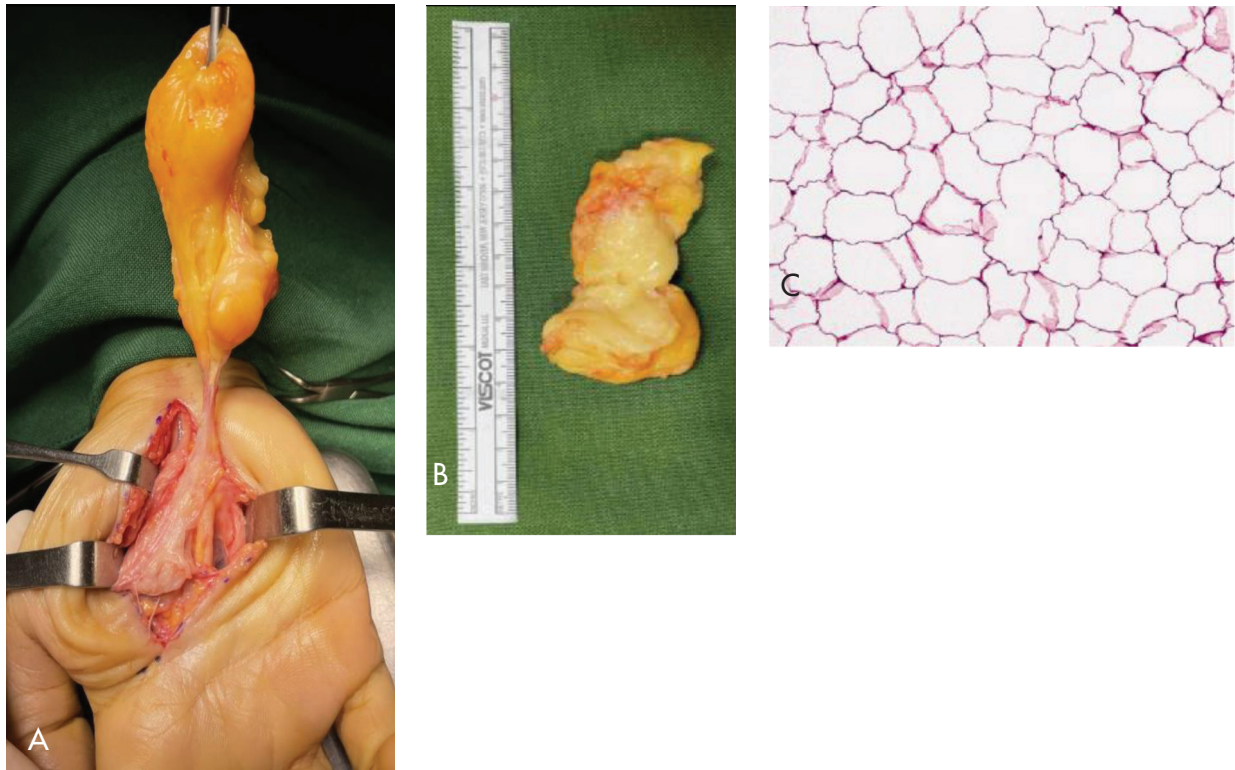

A. Median nerve branch attachments of the lipomatous mass; B. Attachment of the lipomatous mass to the median nerve

The mass was completely excised from the median nerve and sent for histopathologic studies.

Grossly, the mass was yellow, lobulated and fatty measuring 5.0 x 3.5 x 2.0 cm. Microscopic

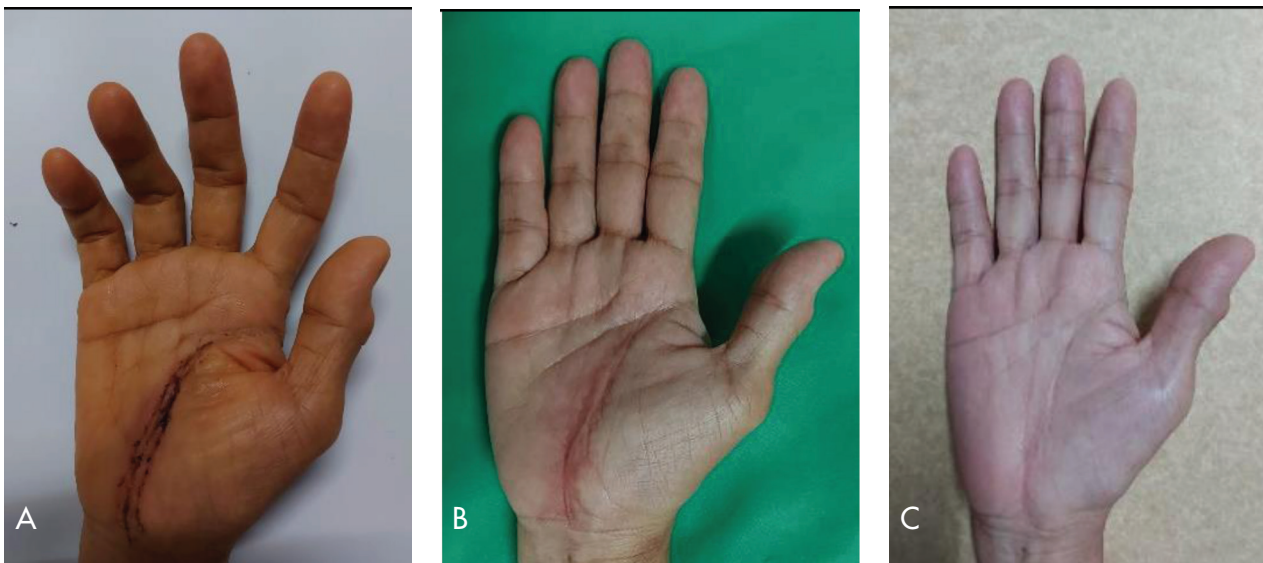
sections revealed proliferation of mature adipocytes separated by thin septae which was consistent with a lipoma.



A. Complete excision of the mass from its nerve attachments; B. Lipomatous mass measuring at 5.0 x 3.5 x 2.0 cm; C. Microscopic sections of lipomatous mass composed of mature adipocytes separated by thin septae

At 1-month post excision, the patient noted improvement of sensation over the median nerve distribution with better grip strength due to absence of the mass. At 6-month follow-up, the patient

reported no sensory or motor deficits and a negative Tinel sign on the carpal tunnel. No recurrence of the mass was noted.



A. 2 weeks post-surgery; B. 3 months post-surgery; C. 6 months post-surgery

## DISCUSSION

Adipose cells are normal parts of the peripheral nerve, found in the epineurium between nerve fascicles. [5] Excessive adipose tissue around these nerves, however, can result in a spectrum of tumors. Lipomas associated with peripheral nerves were classified by Guthikonda, et. al., in 1994. They divided benign lipomatous tumors into four distinct diagnoses: (1) **Soft Lipoma**, where a single lipoma is present either in the subcutaneous layer or in the deeper subfascial or muscular plane; (2) **Intraneural Lipoma**, a clearly defined tumor arising from the epineurium of a nerve; (3) **Lipofibromatous Hamartoma (LFH)**; characterized by extensive and diffuse swelling of the nerve due to fibrofatty tissue infiltration making excision difficult; (4) **Macro dystrophia Lipomatosa**, involves enlargement of digits caused by fatty infiltration or hypertrophy of all components of the digits, including the peripheral nerve in question. [5]

Morley reported the first case of an intraneural lipoma in 1964 with cases associated with peripheral nerves being extremely rare. Rusko and Larson described tumors that showed characteristics of a benign lipoma and could be separated from neural elements and termed them as "true intraneural lipomas".[3] Mason first described LFH in 1953, characterized by diffuse involvement of the nerve with a mixture of normal collagenous tissue and proliferative adipose tissue.[4]

Compressive symptoms can be caused by these lipomatous tumors, usually at areas of typical entrapment neuropathy (ie, carpal tunnel, Guyon canal, tarsal tunnel) with a preponderance to the upper extremity.[2] Physical examination findings such as sensory deficits around the nerve distribution and a positive Tinel sign are typical, and surgical release of the compressive sites during tumor excision is a prudent practice.

Magnetic resonance imaging plays a major role in visualizing the tumor's extent and local staging. [1,3-6] Intraneural lipomas show a markedly high intensity on both T1- and T2-weighted images,

different from that of LFH that show a characteristic "coaxial cable-like" appearance on cross-section or "spaghetti-like" appearance on longitudinal section with low-intensity signals embedded within excessive fatty tissues.[3,5,6] Ultrasonography has been described by some authors as a useful tool in the diagnostic and intraoperative management of peripheral nerve lesions.[6,7]

Peripheral nerve lipomas differ in management depending on the specific pathologic entity. Intraneural lipomas are encapsulated and well-delineated from the nerve lending themselves to be more amenable for total excision of the mass. Careful preservation of the nerve is vital and has been seen to have good outcomes.[3,5,6] Surgical excision of LFH on the other hand is not recommended; the effects of excision are devastating in terms of sensory and motor functions of the nerve in question, and LFH can involve the entire nerve to the plexus, making total resection impossible.[4]

The mass described in this present case report shares characteristics of intraneural lipomas. Its gross appearance is highly indicative of a lipoma and its close relationship with the median nerve suggests an epineural origin.

## CONCLUSION

Lipomas are the most common soft tissue tumors in the body. Despite their prevalence, however, they rarely affect peripheral nerves as seen in the case presented. A thorough history and physical examination was important to detect compressive symptoms that the mass caused to the adjacent median nerve. Imaging techniques such as MRI and ultrasonography demarcation of the tumor margins aided in preoperative planning. Magnetic resonance imaging findings indicative of a well-demarcated lesion point to a mass more amenable for complete excision of the tumor with improved neurologic symptoms. To the author's knowledge, there have been no published papers describing an intraneural lipoma in the Filipino population, making this case rare.

## REFERENCES

1. Marek T, Amrami KK, Mahan MA, Spinner RJ. Intraneural Lipomas: Institutional and literature review. *Acta Neurochirurgica*, 2018;160(11):2209–18. Available from: <https://doi.org/10.1007/s00701-018-3677-7>
2. Flores LP, Carneiro JZ. Peripheral nerve compression secondary to adjacent lipomas. *Surgical Neurology*, 2007;67(3):258–62. Available from: <https://doi.org/10.1016/j.surneu.2006.06.052>
3. Okubo T, Saito T, Mitomi H, Takagi T, Torigoe T, Suehara Y, Katagiri H, Murata H, Takahashi M, Ito I, Yao T, Kaneko K. Intraneural lipomatous tumor of the median nerve: Three case reports with a review of the literature. *International Journal of Surgery Case Reports*, 2012;3(9):407–11. Available from: <https://doi.org/10.1016/j.ijscr.2012.05.007>
4. Amadio PC, Reiman HM, Dobyms JH. Lipofibromatous hamartoma of nerve. *The Journal of Hand Surgery*, 1988;13(1):67–75. Available from: [https://doi.org/10.1016/0363-5023\(88\)90203-1](https://doi.org/10.1016/0363-5023(88)90203-1)
5. Teles AR, Finger G, Schuster MN, Gobbato PL. Peripheral nerve lipoma: Case report of an intraneural lipoma of the median nerve and literature review. *Asian J Neurosurg* [Internet]. 2016;11(4):458. Available from: <http://dx.doi.org/10.4103/1793-5482.181118>
6. Cribb GL, Cool WP, Ford DJ, Mangham DC. Giant lipomatous tumors of the hand and forearm. *Journal of Hand Surgery*, 2005;30(5):509–12. Available from: <https://doi.org/10.1016/j.jhsb.2005.05.002>
7. Ergun T, Lakadamyali H, Derincek A, Cagla Tarhan N, Ozturk A. Magnetic resonance imaging in the visualization of benign tumors and tumor like lesions of the hand and wrist. *Current Problems in Diagnostic Radiology*, 2010;39(1):1–16. Available from: <https://doi.org/10.1067/j.cpradiol.2009.01.002>



**Open Access** This article is licensed under a Creative Commons Attribution-NonCommercial-ShareAlike 4.0 International License, which permits use, share — copy and redistribute the material in any medium or format, adapt — remix, transform, and build upon the material, as long as you give appropriate credit, provide a link to the license, and indicate if changes were made. You may do so in any reasonable manner, but not in any way that suggests the licensor endorses you or your use. You may not use the material for commercial purposes. If you remix, transform, or build upon the material, you must distribute your contributions under the same license as the original. You may not apply legal terms or technological measures that legally restrict others from doing anything the license permits. The images or other third party material in this article are included in the article's Creative Commons license, unless indicated otherwise in a credit line to the material. If material is not included in the article's Creative Commons license and your intended use is not permitted by statutory regulation or exceeds the permitted use, you will need to obtain permission directly from the copyright holder. To view a copy of this license, visit <https://creativecommons.org/licenses/by-nc-sa/4.0/>.