

# 5% Simvastatin Ointment as Treatment for Congenital Hemidysplasia with Ichthyosiform Erythroderma and Limb Defects (CHILD) Syndrome in a 4-year-old Female: A Case Report

Denise Marie B. David, MD,<sup>1</sup> Koreen Blossom T. Chan, MD<sup>1</sup> and Carmela Augusta F. Dayrit-Castro, MD<sup>1,2</sup>

<sup>1</sup>Department of Dermatology, Philippine General Hospital, University of the Philippines Manila, Manila, Philippines

<sup>2</sup>Section of Dermatology, De La Salle University Medical Center, Dasmariñas, Cavite, Philippines

## ABSTRACT

A 4-year-old female with Congenital Hemidysplasia with Ichthyosiform erythroderma and Limb Defects (CHILD) syndrome, with a pathogenic variant of the NSDHL gene, c.130G>A (p.Gly44Ser), and unilateral right-sided erythematous verrucous plaques with scaling and ipsilateral limb defects, was started on 5% simvastatin ointment. It was applied twice daily for four months, with improvement already seen starting week 2. Monotherapy with 5% simvastatin ointment was able to decrease the thickness of the verrucous plaques seen in our patient, highlighting that the accumulation of toxic metabolites may play a more crucial role in its disease pathogenesis.

**Keywords:** Congenital Hemidysplasia with Ichthyosiform erythroderma and Limb Defects Syndrome, CHILD Syndrome, simvastatin ointment, case report

## INTRODUCTION

Congenital Hemidysplasia with Ichthyosiform erythroderma and Limb Defects (CHILD) syndrome is a rare X-linked dominant disorder, caused by mutations in the NADPH steroid dehydrogenase-like (NSDHL) gene (Figure 1).<sup>1</sup> Patients present with erythematous scaly plaques localized on one side of the body with a sharp midline demarcation, and limb hypoplasia or aplasia on the ipsilateral side.<sup>1</sup> However, minimal contralateral involvement is usually seen in some patients.

Currently, there are less than 100 reported cases, and two of which are male.<sup>2</sup> Locally, the Philippine Dermatological Society-Health Information System (PDS-HIS) was able to record one case in 2013, while our patient is the only documented case in our hospital.

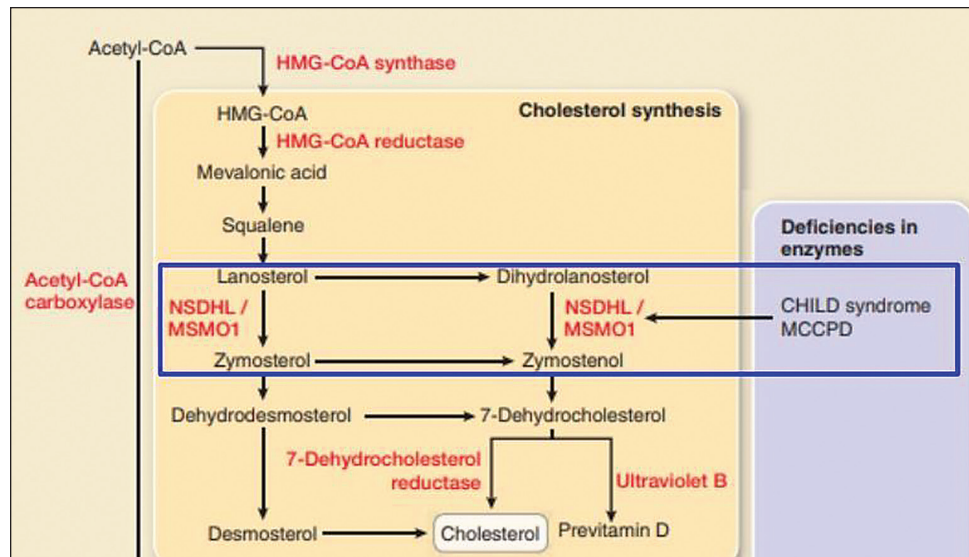
Symptomatic treatment with emollients, retinoids, and ketoconazole cream has been used.<sup>1</sup> At present, a pathogenesis-based treatment is being explored, with direct application of topical cholesterol to target cholesterol deficiency, and topical HMG-CoA reductase inhibitors, such as lovastatin or simvastatin, to address the accumulation of toxic metabolite precursors.<sup>3</sup> Monotherapy with a topical statin has shown promising results.<sup>4-6</sup>



Paper presentation – World Congress of Dermatology, July 3-7, 2023, Singapore.

eISSN 2094-9278 (Online)  
Published: September 30, 2024  
<https://doi.org/10.47895/amp.v58i17.9202>  
Copyright: The Author(s) 2024

Corresponding author: Denise Marie B. David, MD  
Department of Dermatology  
Philippine General Hospital  
University of the Philippines Manila  
Taft Avenue, Ermita, Manila 1000, Philippines  
Email: david.denise29@gmail.com  
ORCID: <https://orcid.org/0009-0003-5263-6166>



**Figure 1. Synthetic Pathways and Key Enzymes for Cholesterol Synthesis.** Highlighted in the blue box is the affected gene responsible for manifestations of CHILD syndrome.

*Image lifted from Fitzpatrick, 9<sup>th</sup> edition.<sup>1</sup>*

## CASE PRESENTATION

A 4-year-old female with CHILD syndrome, confirmed with a pathogenic variant of the NSDHL gene, c.130G>A (p.Gly44Ser), presenting at birth with the classic unilateral right-sided erythematous verrucous plaques without crossing the midline, and ipsilateral limb defects (syndactyly), consulted back in our institution via telemedicine. She is the youngest in a family of four, born to a healthy non-consanguineous couple of Filipino descent. This case was already published in BMJ last November 2018.<sup>7</sup>

In the interim, they continued to use mild soap for bathing, occasional application of petroleum jelly, and as needed intake of oral antihistamine. However, notable is the persistence of the right-sided multiple well-defined linear to irregularly-shaped erythematous verrucous plaques with yellowish crusts, located on the chest, trunk, upper and lower extremities, labia majora and inguinal area, following the lines of Blaschko in distribution, with a sharp midline demarcation and islands of normal skin, also minimally affecting the left arm and leg, involving approximately 20% body surface area, associated with the ipsilateral syndactyly of the 4<sup>th</sup> and 5<sup>th</sup> digits of the right hand and right foot. The patient's mother also reports irritability, frequent scratching, and occasional foul-smelling discharge from the right foot, along with recurrence of thick yellowish and hemorrhagic crusts and scaling, more prominent on the chest, abdomen, and foot. The patient was previously treated in 2018 with application of keratolytic agents, bland emollients, and ketoconazole cream, all providing only minimal and temporary relief.

A pathogenesis-based treatment is currently being used in patients diagnosed with CHILD syndrome, with

more recent studies citing good efficacy and safety with monotherapy with HMG-CoA reductase inhibitors (Figure 2). The Pharmacy Department of the Philippine General Hospital was able to compound 5% simvastatin ointment, from 20mg/tablet of simvastatin and petroleum jelly as base.

The 5% simvastatin ointment was applied directly on the plaques, twice daily for four months, except for the right inguinal area and labia majora where application started a month later, as per patient's mother request after expressing concern that the inguinal area may be more sensitive than the extremities and trunk. A total of 100g of 5% simvastatin ointment was applied to the patient every week. She came in for follow-up after the first two weeks, then every four weeks thereafter. The aim during each follow-up was to assess treatment response, to address any complications, and to refill medication. During every follow-up, serial photographs were taken per body region examined. A review of proper application of the ointment was also done. Monitoring of liver and kidney function tests, as well as serum cholesterol level were not done, similar to previously-published cases.

Starting at week 2, there was pronounced rapid improvement and decrease in the erythema, crusting, scaling, excoriations, and pruritus of the plaques, most evident on the palm. However, the verrucous plaques reappeared on the palms on week 12, which again almost cleared after four weeks. The most responsive sites were the arm, chest, abdomen, inguinal and labia majora, while the foot was the most resistant. At baseline, the entire foot was covered with erythematous scaly plaques with yellowish foul-smelling crusts. There was also note of bleeding on areas that the patient would usually scratch or rub. Starting week 10 onwards, there was resolution of the foul-smelling discharge,

pruritus, and improvement in the verrucous plaques. Some of the plaques appeared lighter in color, even appearing as pinkish atrophic scars particularly on the forearms and thighs. However, there was no significant change in the total body surface area involved, only improvement in the erythema, and thickness of the scales and crusts. The patient’s mother reports significant reduction in pruritus, resolution of foul-smelling discharge and bleeding enabling the patient to walk more comfortably, and improvement in the patient’s quality of sleep.

The patient completed a total of four months of treatment, similar to duration of application in some published cases. No adverse effects and other unanticipated events were documented. A month later, on follow-up via telemedicine, there was no recurrence of the very thick verrucous plaques with foul-smelling discharge, however still with occasionally pruritic erythematous plaques with scaling.

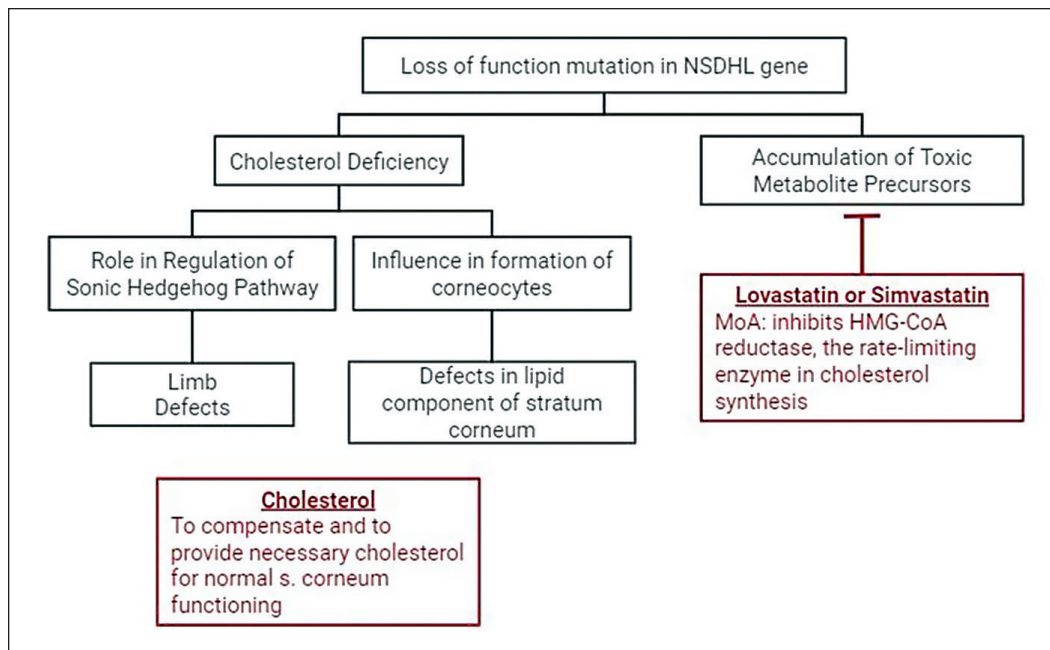
The patient was monitored for possible recurrence, however was lost to follow-up after three months. She came back a year and a half later, reporting occasional flares of yellowish verrucous plaques, aggravated by extremes of temperature. She was restarted on twice daily application of 5% simvastatin ointment, which gave immediate relief of pruritus as well as decrease in the verrucous plaques after a week. Close monitoring was advised to better ascertain most appropriate duration of application of medication. However, she was again lost to follow-up and was unable to continue medications due to financial constraints.

## DISCUSSION

The pathophysiology of CHILD syndrome begins with a loss of function mutation in the NSDHL gene.<sup>1</sup> This then leads to cholesterol deficiency and accumulation of toxic metabolite precursors. Cholesterol interacts with various proteins that control embryonic development via the sonic hedgehog pathway.<sup>3</sup> This explains the associated limb defects which range from hypoplasia to complete absence of limbs.<sup>3</sup> Ipsilateral anomalies involving the heart, brain, lungs, and reproductive tract may also be expected.<sup>3</sup> Cholesterol also influences formation of corneocytes. Therefore, its deficiency leads to defects in the lipid component of the stratum corneum, which will clinically present as ichthyosis.

A pathogenesis-based treatment is being explored as treatment in patients with CHILD syndrome (Figure 2). To target cholesterol deficiency, topical cholesterol may be applied directly on lesions to compensate and to provide necessary cholesterol for proper functioning of stratum corneum.<sup>3</sup> While lovastatin or simvastatin, known HMG-CoA reductase inhibitors, target the accumulation of toxic metabolite precursors.<sup>3</sup>

The use of 2% lovastatin + 2% cholesterol lotion (LC lotion) in a 33/F, applied once daily for eight weeks, maintained on every other day application, showed satisfactory results.<sup>3</sup> The same results were seen in a study with the LC lotion applied twice daily for eight weeks,<sup>8</sup> with a maintenance application of thrice weekly.<sup>9</sup> The 2% lovastatin + 2% cholesterol in cream form was given to an 11/F patient



**Figure 2. Targets of Pathogenesis-based Treatment in CHILD Syndrome.** Simplified presentation of the pathophysiology of CHILD syndrome and how each is addressed by proposed treatment strategies with topical cholesterol and HMG-CoA reductase inhibitors.

2x/week for six weeks.<sup>10</sup> However, she was lost to follow-up and returned after eight months after noting recurrence.<sup>10</sup> In 2020, Yu and colleagues tried various formulations namely: 2.5% simvastatin ointment for three months, followed by 5% simvastatin for one month in two patients, 2% simvastatin + 2% cholesterol lotion for eight months, then 3-month course of 2.5% simvastatin ointment, then 1-month course of 5% simvastatin ointment. Lastly, they tried monotherapy with 5% simvastatin ointment applied twice daily for a month. Their case series concluded that 2.5 and 5% simvastatin ointment is safe and effective, with 5% formulation showing better improvement at thicker areas.<sup>5</sup> Similar findings were replicated in a study where 5% simvastatin ointment was given to a 10-month female.<sup>6</sup> No laboratory parameters were monitored while the abovementioned patients were on treatment. The body surface area affected was not quantified as well.

The series of studies mentioned above, with patients' ages ranging from 10 months old to 33 years old, were used to create the regimen applied to our patient. Simvastatin was the statin selected due to its easy availability. Five percent formulation was chosen as more recent studies showed promising results, coupled with a good safety profile. Ointment was the selected vehicle as it can help better deliver the drug to the thick scales and crusts present in our patient.

Response to treatment was documented through serial photographs taken on Weeks 2, 4, 12 and 16. Patient was not able to follow-up on Week 8 as she contracted varicella. Rapid decrease in erythema, thickness of verrucous plaques, and scaling was evident by week 2, most prominent on the palm. However, notable is the occasional recurrence of the verrucous plaques several weeks later, which will again quickly improve upon reapplication of medication. Pruritus was significantly decreased as seen in resolution of excoriations and improvement in irritability as noted by the patient's caregiver. A numerical rating score for pruritus or the Dermatologic Life Quality Index (DLQI) could have been obtained to quantify improvement, however is not feasible in our pediatric patient. Figure 3 shows the patient's baseline photos, as well as the progress of every follow-up visit. Figure 4 shows patient teleconsultation follow-up, a month after discontinuation of application of ointment.

## CONCLUSION

Monotherapy with 5% simvastatin ointment was able to decrease the thickness of the verrucous plaques seen in our patient. This highlights that the accumulation of toxic metabolites may play a more crucial role in disease pathogenesis. Close patient monitoring is necessary to tailor needed duration of treatment, and possibility of a maintenance phase, along with observation for side effects. Our patient is continuously being managed by a multi-specialty group composed of the following: Dermatology, Rehabilitation Medicine, Orthopedics, Developmental Pediatrics, and Genetics. The patient's family is also part of the Philippine Society for Orphan Disorders support group.

## Acknowledgments

The authors would like to thank Dr. Ebner Bon Maceda, Dr. Lisa Kratz, Dr. Veronica Marie Ramos, and Dr. Mary Ann Abacan for their initial work-up for our patient which confirmed the diagnosis.

## Informed Consent

An informed consent which indicates that the subject agrees to participate in the trial of therapy with 5% simvastatin ointment has been read and signed by the patient's mother. The above mentioned document also includes a clause that the patient agrees that outcomes obtained may be used for publication, given that all personal identification will remain confidential. Both the researcher and patient have a copy of the document.

## Statement of Authorship

All authors certified fulfillment of ICMJE authorship criteria.

## Author Disclosure

All authors declared no conflicts of interest.

## Funding Source

None.



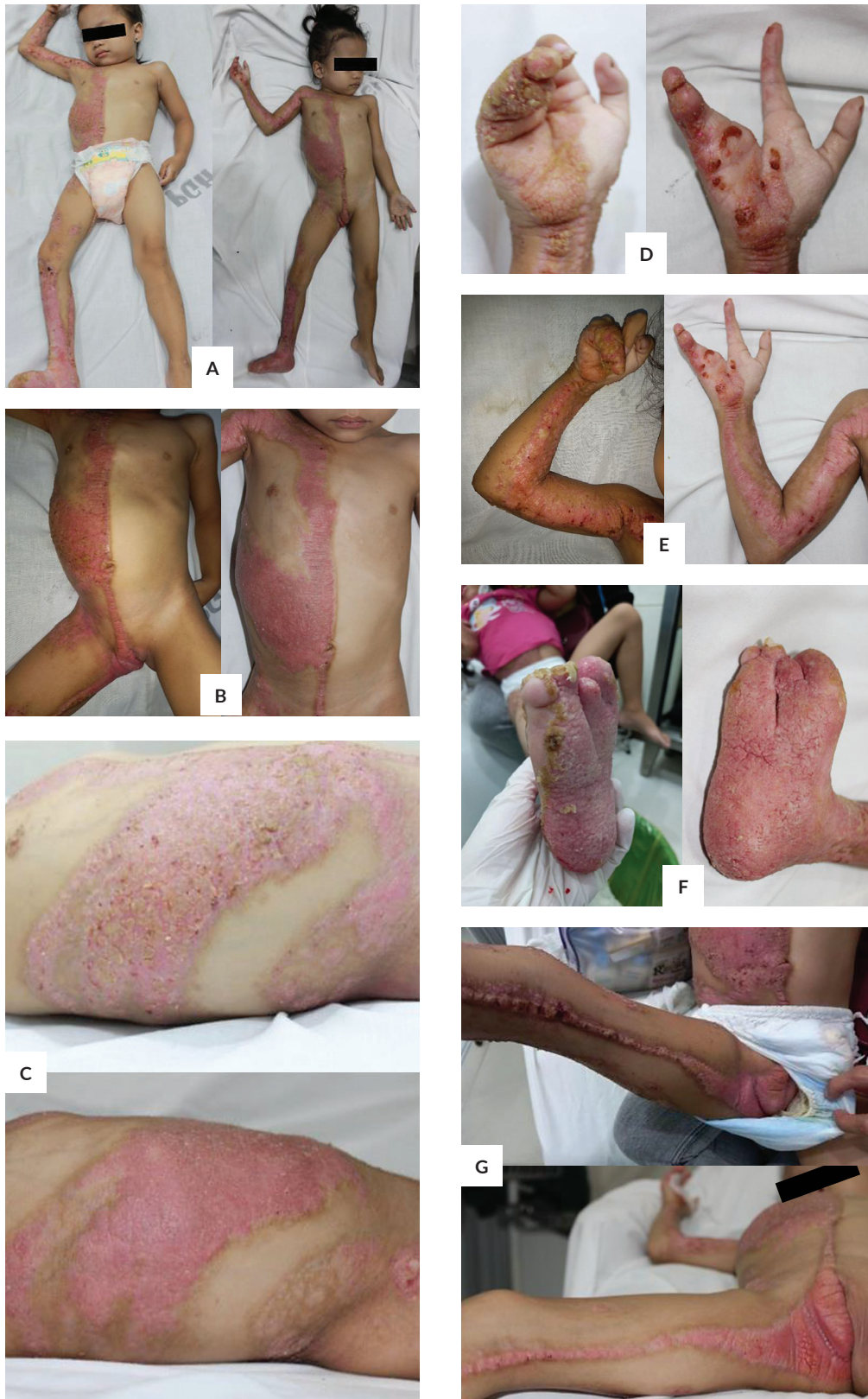
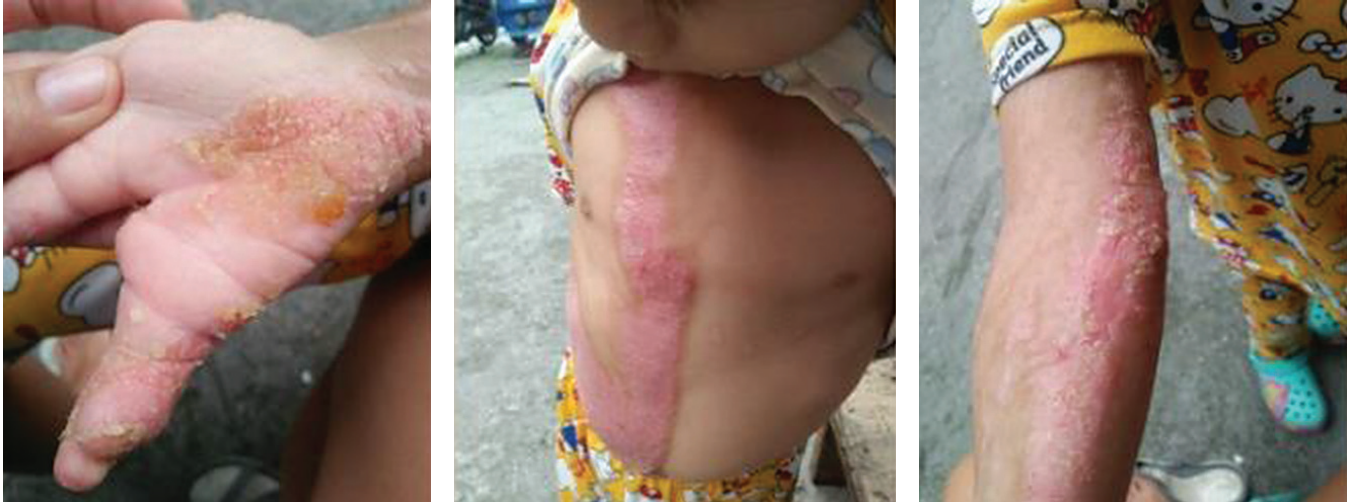
Figure 3. Photos taken baseline and at Week 16 of treatment. Noted decrease in erythema, thick verrucous yellowish plaques with areas of excoriations and scaling (A-G).



**Figure 4.** Photos taken after one month of treatment, sent via teleconsultation. Noted further decrease in erythema, thickness of verrucous plaques and scaling. Patient reports controlled pruritus.

## REFERENCES

1. Kang S, Amagai M, Bruckner AL, Enk AH, Margolis DJ, McMichael AJ, et al, editors. Fitzpatrick's Dermatology, 9th ed. McGraw-Hill Education; 2019. pp. 215, 804-805.
2. Fackler N, Zachary C, Kim DJ, Smith J, Sarpa HG. Not lost to follow-up: A rare case of CHILD syndrome in a boy reappears. *JAAD Case Rep.* 2018 Nov 9;4(10):1010-3. doi: 10.1016/j.jdcr.2018.10.001. PMID: 30456274; PMCID: PMC6232698.
3. Christiansen AG, Koppelhus U, Sommerlund M. Skin abnormalities in CHILD syndrome successfully treated with pathogenesis-based therapy. *Acta Derm Venereol.* 2015 Jul;95(6):752-3. doi: 10.2340/00015555-2044. PMID: 25587692.
4. Bajawi SM, Jafarri SA, Buraik MA, Al Attas KM, Hannani HY. Pathogenesis-based therapy: Cutaneous abnormalities of CHILD syndrome successfully treated with topical simvastatin monotherapy. *JAAD Case Rep.* 2018 Feb 23;4(3):232-4. doi: 10.1016/j.jdcr.2017.11.019. PMID: 29687057; PMCID: PMC5909487.
5. Yu X, Chen L, Yang Z, Gu Y, Zheng W, Wu Z, et al. An excellent response to topical therapy of four congenital hemidysplasia with ichthyosiform erythroderma and limb defects syndrome patients with an increased concentration of simvastatin ointment. *J Eur Acad Dermatol Venereol.* 2020 Jan;34(1):e8-e11. doi: 10.1111/jdv.15838. PMID: 31374135.
6. Kallis P, Bisbee E, Garganta C, Schoch JJ. Rapid improvement of skin lesions in CHILD syndrome with topical 5% simvastatin ointment. *Pediatr Dermatol.* 2022 Jan;39(1):151-2. doi: 10.1111/pde.14865. PMID: 34787337.
7. Maceda EBG, Kratz LE, Ramos VME, Abacan MAR. Novel NSDHL gene variant for congenital hemidysplasia with ichthyosiform erythroderma and limb defects (CHILD) syndrome. *BMJ Case Rep.* 2020 Nov 2;13(11):e236859. doi: 10.1136/bcr-2020-236859. PMID: 33139364; PMCID: PMC7607564.
8. Yu X, Zhang J, Gu Y, Deng D, Wu Z, Bao L, et al. CHILD syndrome mimicking verrucous nevus in a Chinese patient responded well to the topical therapy of compound of simvastatin and cholesterol. *J Eur Acad Dermatol Venereol.* 2018 Jul;32(7):1209-13. doi: 10.1111/jdv.14788. PMID: 29341259.
9. Sandoval KR, Machado MCR, de Oliveira ZNP, Nico MMS. CHILD syndrome: successful treatment of skin lesions with topical lovastatin and cholesterol lotion. *An Bras Dermatol.* 2019 Jul 26;94(3):341-3. doi: 10.1590/abd1806-4841.20198789. PMID: 31365666; PMCID: PMC6668949.
10. Bergqvist C, Abdallah B, Hasbani DJ, Abbas O, Kibbi AG, Hamie L, et al. CHILD syndrome: A modified pathogenesis-targeted therapeutic approach. *Am J Med Genet A.* 2018 Mar;176(3):733-8. doi: 10.1002/ajmg.a.38619. PMID: 29392821.