

ARTICLE INFO

Submitted: 17/01/2022

Accepted: 01/03/2022

Online: 03/08/2022

Effectiveness of Diode Laser Compared with Sodium Fluoride Varnish in Management of Dentin Hypersensitivity Associated with Gingival Recession

Benju Shrestha*, Shaili Pradhan, Krishna Prasad Lamichhane

Periodontology and Oral Implantology Unit, Department of Dental Surgery, National Academy of Medical Sciences, Bir Hospital, Kathmandu 44600, Nepal

*Corresponding author: benjushrsth539@gmail.com

To cite this article: Shrestha B, Pradhan S, Lamichhane KP (2022). Effectiveness of diode laser compared with sodium fluoride varnish in management of dentin hypersensitivity associated with gingival recession. *Arch Orolfac Sci*, 17(Supp.1): 97–106. <https://doi.org/10.21315/aos2022.17S1.OA07>

To link to this article: <https://doi.org/10.21315/aos2022.17S1.OA07>

ABSTRACT

Using laser for treatment of dentin hypersensitivity (DH) have recently shown promising results and better immediate reduction in pain scores. However, its efficacy and mechanism of action is controversial. Thus, this study aimed to evaluate the effectiveness of diode laser compared with sodium fluoride varnish in treating DH in patients with gingival recession. Eighteen patients with Miller's class I and class II gingival recession and hypersensitivity in at least two non-adjacent teeth were included in the study. Test surfaces ($n = 25$) were treated with diode laser, whilst control surfaces ($n = 23$) were treated with 5% sodium fluoride varnish. Visual Analogue Scale (VAS) scores were recorded for air and tactile stimulus for both groups at baseline, 15 min, 1 month and 3 months post-treatment. Results showed significant ($p < 0.05$) reduction in VAS scores at 15 min, 1 month and 3 months compared with baseline in both test and control surfaces, with no significant intergroup differences. However, the percentage reduction in DH was more in laser at all evaluation periods. The use of diode laser and sodium fluoride varnish showed good immediate and prolonged results. Further studies are needed to come up with more effective treatment methods.

Keywords: *Dentin hypersensitivity; diode laser; fluoride varnish; gingival recession*

INTRODUCTION

Dentin hypersensitivity (DH) is a short sharp pain arising from exposed dentine in response to stimuli, typically thermal, evaporative, tactile, osmotic or chemical, which could not be ascribed to any other form of dental defect or pathology (Dowell & Addy, 1983). It is one of the most common problems encountered in dental practice, limiting patient's regular eating habits. The pain may be mild to severe on eating

of sweet, sour, cold and hot foods. One of the aetiologies of DH is gingival recession. Previous studies have reported the prevalence of DH associated with gingival recession ranging from 29.7% to 93% (Bamise *et al.*, 2008; Chrysanthakopoulos, 2011; Alcântara *et al.*, 2018).

Several at home and in-office treatment approaches for DH have been tried and tested but most of these agents have the disadvantages of delayed action, multiple

applications and short-term relief (Bamise & Esan, 2011; He *et al.*, 2011; Blatz, 2012). According to Grossman (1935), the ideal treatment for DH must act fast, be easy to apply, be effective for long periods, does not irritate pulp or stain the teeth and be cost effective. However, no treatment that satisfies all these requirements is available yet.

Professionally applied topical fluorides have been recommended after periodontal treatment to reduce patient's discomfort (Porto *et al.*, 2009). Apart from precipitation of calcium fluoride crystals in the inlet of dentinal tubules, fluoride increases the enamel resistance to acid action. However, the precipitate is slowly soluble in saliva, which explains the transitory action of this barrier. Fluoride varnishes have the advantage of being retained on the teeth for hours, thereby enhancing fluoride uptake whilst providing a temporary coating on the affected tooth surfaces (Clark *et al.*, 1985).

An increasing use of diode laser in treatment of DH was found and it was proven to be more effective, faster and more comfortable than the traditional DH treatment approach (Rezazadeh *et al.*, 2019). However, the efficacy and mechanism of action of laser treatment for DH therapy are controversial (Sgolastra *et al.*, 2011). Most studies have compared laser with other conventional desensitising agents. Some randomised controlled trials demonstrated greater efficacy of lasers than topical desensitising agent in treating DH (Vieira *et al.*, 2009; Dilsiz *et al.*, 2010), whilst others suggested no significant difference between laser therapy and topical desensitising agent (Corona *et al.*, 2003; Flecha *et al.*, 2013). Thus, the present study aimed to evaluate the effectiveness of diode laser compared with sodium fluoride varnish in the treatment of DH in patients with gingival recession to provide them with a better treatment option that is faster in action and has long-lasting effect.

MATERIALS AND METHODS

This comparative observational study was conducted after receiving ethical approval from the Institutional Review Board, National Academy of Medical Sciences, Bir Hospital (Reference no.: 876/076/77). Participants were enrolled in the study after providing written informed consent. Each participant was observed for three months.

The sample size was calculated to be 18 patients per group under the predetermined level of significance (< 0.05) and confidence interval of 95%. The values for standard deviation (SD) and difference of mean was obtained from the study by Sicilia *et al.* (2009). However, the test and control surfaces were assigned in same individual as pain scores are highly dependent upon the individual's pain perception and varies from person to person. Teeth were used as statistical unit to minimise subjective errors.

Patients attending the institutional outpatient department of periodontology, with gingival recession and DH, and fulfilling all inclusion criteria were invited to participate in this study. The inclusion criteria were as follows:

1. Patients aged 20–70 years old.
2. Miller's class I and class II gingival recession.
3. Patients with at least two sensitive tooth not adjacent to each other.
4. Good oral hygiene at the time of treatment.

Otherwise, the exclusion criteria were as follows:

1. Presence of cavities/fracture/crack tooth.
2. Patients with defective restorations and premature contacts.
3. Teeth with crown or root-canal-treated teeth.
4. Known allergy to desensitising agent.
5. Abrasion requiring restoration.

A total of 18 subjects (48 teeth, 25 teeth from the test group and 23 teeth from the control group) were included in this study. Amongst them, 11 were females and 7 were males. Non-adjacent hypersensitive teeth with Miller's class I and class II recession were selected as the test and control surfaces (Fig. 1) to reduce the possibility of cross-effect that may occur during treatment of adjacent teeth and affect the patients' Visual Analogue Scale (VAS) scores. The adjacent teeth were included under the same category that is either test or control. Miller's class III and class IV recessions were excluded due to the difficulty in reaching the proximal areas accurately, which may affect the VAS scores.

DH was evaluated by pain response to air and tactile stimuli at the test and control sites at baseline. The pain response was recorded in a VAS scale of 0 to 10, where 0 represents "no pain" and 10 represents "greatest pain". Before desensitising procedures were performed, the tooth surface (buccal) was rinsed with water and gently dried with cotton. Isolation was obtained using cotton rolls and saliva ejector. The control surfaces

were treated with 5% sodium fluoride varnish (Fluoritop SR, 22,600 ppm of fluoride, ICPA Health Products Ltd., India) and the test surfaces were submitted to diode laser (Biolase Epic 10; 940 nm, BIOLASE, Inc., USA) irradiation. The VAS score was recorded for air and tactile stimuli at 15 min, 1 month and 3 months after treatment.

Recording of VAS scores: Patients' response to air blast was assessed by a short blast of 1 sec duration by three-way syringe at a distance of 2–5 mm from the tooth perpendicularly (Figs. 2A and 2B). For tactile stimulus, a straight probe (Probe 9) was run mesiodistally over the cervical area (Figs. 2C and 2D) and the VAS score was recorded.

In the control surfaces, sodium fluoride varnish was applied with applicator tips at the cervical region (Fig. 3A) and allowed to dry. After drying, another coat of varnish was applied. In the test surfaces, diode laser was used for 30 sec in continuous wave and non-contact mode in cervical areas (Fig. 3B), with tip at a distance of approximately 2 mm under the output power

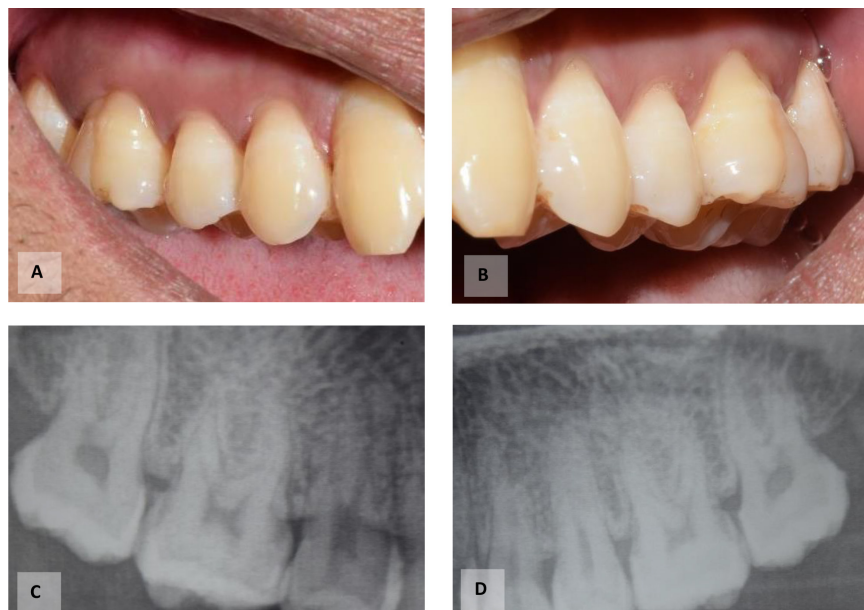

Fig. 1 Test and control sites (16 and 26, respectively) with Miller's class I gingival recession and DH. (A) and (C) Clinical and radiographic picture of the test site; (B) and (D) Clinical and radiographic picture of the control site.

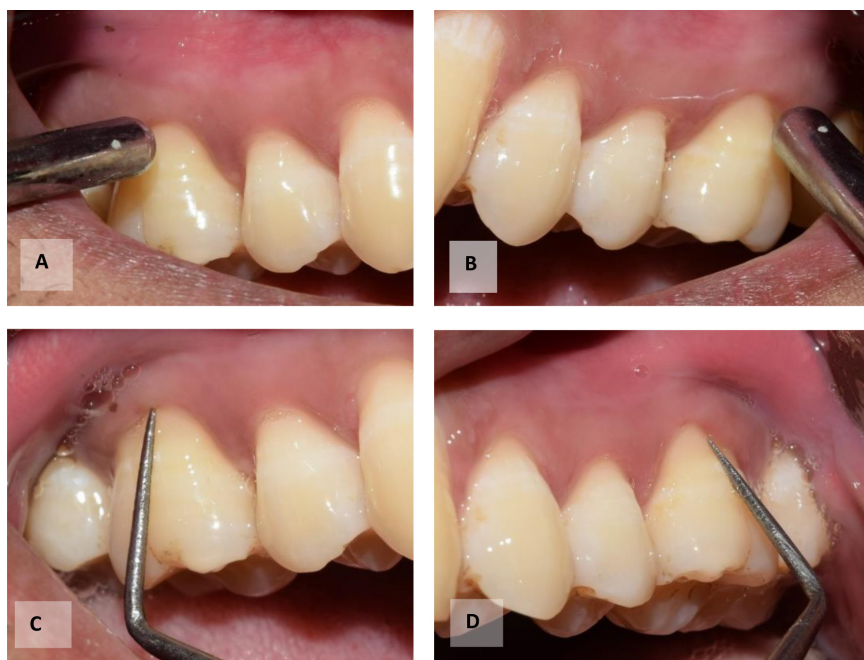

Fig. 2 Evaluation of patient’s response to air and tactile stimulus. (A) and (B) Air blast using three-way syringe at test and control sites, respectively; (C) and (D) Tactile stimulus provided using straight probe at test and control sites, respectively.

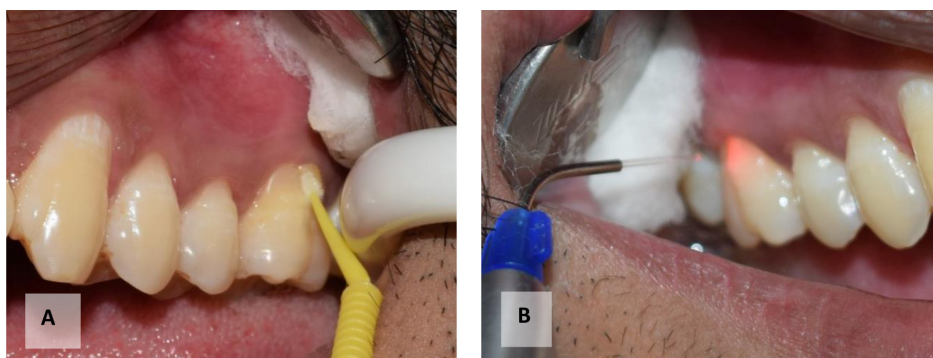


Fig. 3 (A) Application of fluoride varnish on the control site; (B) Diode laser irradiation at the test site.

of 2 W (166 J/cm²). Laser beam was directed perpendicularly to the tooth surface at three points: mesiobuccal, buccal and distobuccal. Each area was irradiated for 30 sec. Patients were instructed not to eat for about 4 h of varnish application (as per manufacturer instructions) and to re-initiate tooth brushing after 12 h, thus enhancing the interaction of fluoride with tooth structure.

Data were analysed with R-3.5.3. software (R Foundation for Statistical Computing, Vienna, Austria). Mean and SD were

calculated for the VAS scores at different time intervals. The percentage of reduction in DH was calculated by the difference of mean baseline VAS score and the mean VAS score after laser or varnish application (after 15 min, 1 month or 3 months) and by dividing the difference by the mean baseline VAS score. Paired *t*-test was used for intragroup comparison and independent *t*-test was used for intergroup comparison. A *p*-value < 0.05 was considered as significant.

RESULTS

All enrolled participants completed the treatment with no loss of follow ups. In addition, 83.33% of the enrolled subjects were between the age of 20 and 40 years old, which shows that young adults are more prone to DH than older population. The most frequently affected teeth were mandibular anterior teeth, followed by maxillary molars, mandibular premolars, maxillary premolars, and mandibular molars, and the least involved was maxillary anterior teeth. No unwanted effects and complications were seen in either group. A total of 48 teeth (25 in the test group and 23 in the control group) were included in the final analysis.

The mean VAS scores for air and tactile stimuli at different time intervals in the test and control group are shown in Table 1. In both sites, a reduction in mean VAS scores was found at all time intervals compared with baseline with respect to air and tactile stimuli. In the diode laser group, a complete reduction in DH was seen in response to tactile stimulus over three months.

Intragroup comparison showed statistically significant immediate reduction in DH (in 15 min) in the diode and fluoride varnish groups with respect to air and tactile stimuli (Table 2). Statistically significant reduction (p -value < 0.05) in the mean VAS scores was also observed at 3-month follow up compared with that at 15 min with respect

Table 1 Mean VAS score \pm SD at different time intervals for test and control groups

Time	Fluoride varnish (control) group (mean VAS \pm SD)		Diode laser (test) group (mean VAS \pm SD)	
	Air stimulus	Tactile stimulus	Air stimulus	Tactile stimulus
Baseline	4.74 \pm 2.4	1.87 \pm 2.49	5.48 \pm 2.18	3.0 \pm 2.9
15 min	2.04 \pm 1.89	0.52 \pm 1.24	1.92 \pm 1.73	0.68 \pm 1.25
1 month	0.69 \pm 1.11	0.26 \pm 0.75	0.68 \pm 1.44	0.08 \pm 0.27
3 months	0.34 \pm 0.71	0.08 \pm 0.28	0.36 \pm 0.75	0

Table 2 Intragroup comparison of mean VAS scores at different time intervals

Time interval	Fluoride varnish group (p -values)		Diode laser group (p -values)	
	Tactile stimulus	Air stimulus	Tactile stimulus	Air stimulus
Baseline vs. 15 min	0.0018	< 0.001	< 0.001	< 0.001
15 min vs. 1 month	0.13	< 0.001	0.03	0.001

Note: p -value of < 0.05 was considered significant.

Table 3 Intergroup comparison of mean VAS scores at different time intervals

Time intervals	p -values for air stimulus	p -values for tactile stimulus
Baseline	0.27	0.15
15 min	0.81	0.66
1 month	0.96	0.28
3 months	0.95	0.16

Note: p -value of < 0.05 was considered significant.

Table 4 Percentage reduction in DH among test and control group at different time intervals

Time intervals	Air stimulus (% reduction)		Tactile stimulus (% reduction)	
	Fluoride varnish	Diode laser	Fluoride varnish	Diode laser
15 min	56.96	72.19	64.96	77.33
1 month	85.44	86.09	87.59	97.33
3 months	92.82	95.72	93.43	100.00

to air stimulus in both groups, whilst the reduction in mean VAS score (15 min versus 1 month) was not statistically significant (p -value = 0.13) with respect to tactile stimulus in the fluoride varnish group.

Intergroup comparison of the mean VAS scores showed no significant differences at different time intervals with respect to air and tactile stimuli (Table 3). However, greater percentage reduction in DH was seen in the diode laser group than in the fluoride varnish group at all evaluation periods (Table 4) though it was not statistically significant.

DISCUSSION

DH is one of the common problems encountered in dental practice and it is a diagnosis of exclusion. The two main aetiologies of DH are gingival recession and enamel loss. Patients with gingival recession are found to have a high prevalence (29.7% to 93%) of DH (Chrysanthakopoulos, 2011). Various treatment modalities are available for treating DH, ranging from at-home treatment modalities to in-office treatment. However, none of them has been marked as gold standard. The home method is slower in action, whilst the in-office products provide immediate relief.

With the advent in technologies, new methods have been investigated and laser is one of them. Various lasers, such as CO₂, Nd:YAG, Er:YAG, He-Ne and diode, have been studied for the treatment of DH. Low-level lasers, such as He-Ne and GaAlAs (diode) lasers, have been reported to be effective in reducing DH (Corona

et al., 2003). Most of the studies have compared the treatment effect of lasers versus desensitiser chemical agents and they have shown controversial results. The present comparative observational study also compared the effectiveness of diode laser with that of sodium fluoride varnish in treating DH.

In this study, DH was evaluated using air blast from a three-way syringe and tactile stimulus due to their ease and the ability to control the exposure time. The evaporative effect of air stimulus changes the dentinal fluid flow, thus causing pain via the activation of mechanoreceptors. However, the tests for assessing DH are subjective. An *in vitro* study compared the effectiveness of lasers at different parameters and found that 2 W, 166 J/cm² and continuous wave mode caused maximum sealing of dentinal tubules, as observed by scanning electron microscopy (Liu *et al.*, 2013). This parameter was also used in the present study. The immediate desensitising effect of diode laser could be attributed to its induction of alterations in neural transmissions (Walsh, 1997; Ladalardo *et al.*, 2004). Besides, low-level lasers have photo-biomodulation effect, in which it stimulates sclerotic dentin production and thus reduces DH.

Fluoride varnish was chosen for application at the control sites as systematic reviews showed that oxalate-, chloride- and fluoride-based agents could effectively occlude dentinal tubules (Porto *et al.*, 2009). Furthermore, fluoride varnish remains in the tooth surface for hours, providing immediate relief, and the gradual action of sodium fluoride varnish is due to the gradual

deposition of calcium fluoride crystals in dentinal tubules (Corona *et al.*, 2003). In the present study, 5% sodium fluoride varnish was used, which is in agreement with a study that showed 5% sodium fluoride was effective in reducing DH up to 24 weeks (Ritter *et al.*, 2006).

The results of this study showed that laser and sodium fluoride varnish were effective at reducing dentinal hypersensitivity. No statistically significant differences were found in between the groups. This finding was similar to a study that showed no significant difference between the two over 90-day follow-up period (Lund *et al.*, 2013). Similarly, another study found that sodium fluoride varnish and diode laser were effective in reducing DH (Corona *et al.*, 2003). Though not statistically significant, the laser showed greater reduction in DH immediately and even one month after treatment. The present study also showed greater percentage reduction in VAS score amongst the diode laser group than the sodium fluoride group at all evaluation periods. Laser and sodium fluoride varnish showed significant DH reduction, with greater percentage of DH reduction in the laser group in many studies (Yilmaz *et al.*, 2011; Soares *et al.*, 2016; Aghanashini *et al.*, 2018). One of the limitation in a study by Yilmaz *et al.* (2011), was that they performed different treatments on adjacent teeth. Thus, cross effect may have occurred, which possibly contributed to the insignificant difference between diode laser and fluoride varnish. This limitation has been eliminated in the present study, where two adjacent teeth were not provided with different treatment. However, the findings were still similar.

The present study showed significant immediate reduction in DH in both groups. In such case, the possibility of a placebo effect should be considered as positive relation between dentist and patient could cause pain inhibition by the releasing of endorphins by the central nervous system

(Wilder-Smith, 1988). However, in the present study, a significant decrease in DH was observed immediately and even after one month and three months. Placebo could not show such durable effects.

In contrast to the findings of the present study, many studies showed that diode laser was more effective than chemical agents (Sicilia *et al.*, 2009; Pesevska *et al.*, 2010). This difference may be due to the action of laser at the neuronal level, whilst varnish acts by tubule occlusion. Sicilia *et al.* (2009) found diode laser (810 nm) to be more effective than potassium nitrate gel (10%) in the reduction of DH. However, the mean baseline VAS score in their study was less than in that in the present study and the laser parameters varied.

Sodium fluoride varnish (5%) was found to be more effective than diode laser (81% reduction in the fluoride varnish group and 67.1% in the laser group) in reducing DH (Dantas *et al.*, 2016). This finding is in contrast to that of the present study. The reason may be due to the repeated application of varnish (four applications over 72–96 h). The parameters for laser were also different from those in the present study. All parameters were not specified clearly in their study except for the energy of 4 J/cm², which is much lesser than that in the present study.

The limitations of this study are that procedures and clinical evaluation were performed by a single examiner, which may have been a source of bias; the lack of blinding; and the possibility of removal of varnish layer during tactile examination, which may have affected the results. If a third group that was control teeth (without any treatment) was included then, it could provide better evidence of the long-term effects of diode and fluoride varnish because DH may also have reduced overtime despite of no treatment due to the formation of reparative dentin.

CONCLUSION

Diode laser and sodium fluoride varnish are equally effective in the treatment of DH amongst patients with gingival recession, with good immediate results and prolonged action over three months. The choice of treatment could be made as per clinician's preference. Further studies are needed for designing the most appropriate treatment protocol for DH.

ACKNOWLEDGEMENTS

We would like to acknowledge Dr. Ranjita Shrestha Gorkhali, Dr. Pramod Kumar Koirala, Dr. Shweta Agrawal, Dr. Rejina Shrestha and Dr. Niyukty Aryal for their invaluable suggestions and support and Mr. Siddhartha Dhungana for his support in statistical analysis.

REFERENCES

- Aghanashini S, Puvvalla B, Nadiger S, Mundinamana DB, Bhat D, Andavarapu S (2018). Comparative evaluation of diode laser and fluoride varnish for treatment of dentin hypersensitivity: A clinical study. *J Interdiscip Dent*, **8**(3): 110–117. https://doi.org/10.4103/jid.jid_3_18
- Alcântara PM, Barroso NFF, Botelho AM, Douglas-de-Oliveira DW, Gonçalves PF, Flecha OD (2018). Associated factors to cervical dentin hypersensitivity in adults: A transversal study. *BMC Oral Health*, **18**: 155. <https://doi.org/10.1186/s12903-018-0616-1>
- Bamise CT, Esan TA (2011). Mechanisms and treatment approaches of dentine hypersensitivity: A literature review. *Oral Health Prev Dent*, **9**(4): 353–367.
- Bamise CT, Olusile AO, Oginni AO (2008). An analysis of the etiological and predisposing factors related to dentin hypersensitivity. *J Contemp Dent Pract*, **9**(5): 52–59.
- Blatz MB (2012). Laser therapy may be better than topical desensitizing agents for treating dentin hypersensitivity. *J Evid Based Dent Pract*, **12**(3 Suppl): 229–230. [https://doi.org/10.1016/S1532-3382\(12\)70044-1](https://doi.org/10.1016/S1532-3382(12)70044-1)
- Chrysanthakopoulos NA (2011). Prevalence of dentine hypersensitivity in a general dental practice in Greece. *J Clin Exp Dent*, **3**(5): e445–e451.
- Clark DC, Hanley JA, Geoghegan S, Vinet D (1985). The effectiveness of a fluoride varnish and a desensitizing toothpaste in treating dentinal hypersensitivity. *J Periodontal Res*, **20**(2): 212–219. <https://doi.org/10.1111/j.1600-0765.1985.tb00428.x>
- Corona SA, Nascimento TN, Catirse AB, Lizarelli RF, Dinelli W, Palma-Dibb RG (2003). Clinical evaluation of low-level laser therapy and fluoride varnish for treating cervical dentinal hypersensitivity. *J Oral Rehabil*, **30**(12): 1183–1189. <https://doi.org/10.1111/j.1365-2842.2003.01185.x>
- Dantas EM, Amorim FK, Nóbrega FJ, Dantas PM, Vasconcelos RG, Queiroz LM (2016). Clinical efficacy of fluoride varnish and low-level laser radiation in treating dentin hypersensitivity. *Braz Dent J*, **27**(1): 79–82. <https://doi.org/10.1590/0103-6440201602422>
- Dilsiz A, Aydın T, Emrem G (2010). Effects of the combined desensitizing dentifrice and diode laser therapy in the treatment of desensitization of teeth with gingival recession. *Photomed Laser Surg*, **28**(Suppl 2): S69–S74. <https://doi.org/10.1089/pho.2009.2640>
- Dowell P, Addy M (1983). Dentine hypersensitivity—a review: Aetiology, symptoms and theories of pain production. *J Clin Periodontol*, **10**(4): 341–350. <https://doi.org/10.1111/j.1600-051x.1983.tb01283.x>

- Flecha OD, Azevedo CG, Matos FR, Vieira-Barbosa NM, Ramos-Jorge ML, Gonçalves PF *et al.* (2013). Cyanoacrylate versus laser in the treatment of dentin hypersensitivity: a controlled, randomized, double-masked and non-inferiority clinical trial. *J Periodontol*, **84**(3): 287–294. <https://doi.org/10.1902/jop.2012.120165>
- Grossman LI (1935). A systematic method for the treatment of hypersensitive dentin. *J Am Dent Assoc*, **22**(4): 592–602. <https://doi.org/10.14219/jada.archive.1935.0110>
- He S, Wang Y, Li X, Hu D (2011). Effectiveness of laser therapy and topical desensitising agents in treating dentine hypersensitivity: A systematic review. *J Oral Rehabil*, **38**(5): 348–358. <https://doi.org/10.1111/j.1365-2842.2010.02193.x>
- Ladalarado TC, Pinheiro A, Campos RA, Brugnera Júnior A, Zanin F, Albernaz PL *et al.* (2004). Laser therapy in the treatment of dentine hypersensitivity. *Braz Dent J*, **15**(2): 144–150. <https://doi.org/10.1590/s0103-64402004000200011>
- Liu Y, Gao J, Gao Y, Xu S, Zhan X, Wu B (2013). *In vitro* study of dentin hypersensitivity treated by 980-nm diode laser. *J Lasers Med Sci*, **4**(3): 111–119.
- Lund RG, Silva AF, Piva E, Da Rosa WL, Heckmann SS, Demarco FF (2013). Clinical evaluation of two desensitizing treatments in southern Brazil: A 3-month follow-up. *Acta Odontol Scand*, **71**(6): 1469–1474. <https://doi.org/10.3109/00016357.2013.770919>
- Pesevska S, Nakova M, Ivanovski K, Angelov N, Kesic L, Obradovic R *et al.* (2010). Dentine hypersensitivity following scaling and root planing: Comparison of low-level laser and topical fluoride treatment. *Lasers Med Sci*, **25**(5): 647–650. <https://doi.org/10.1007/s10103-009-0685-0>
- Porto IC, Andrade AK, Montes MA (2009). Diagnosis and treatment of dentinal hypersensitivity. *J Oral Sci*, **51**(3): 323–332. <https://doi.org/10.2334/josnusd.51.323>
- Rezazadeh F, Dehghanian P, Jafarpour D (2019). Laser effects on the prevention and treatment of dentinal hypersensitivity: A systematic review. *J Lasers Med Sci*, **10**(1): 1–11. <https://doi.org/10.15171/jlms.2019.01>
- Ritter AV, de L Dias W, Miguez P, Caplan DJ, Swift EJ Jr (2006). Treating cervical dentin hypersensitivity with fluoride varnish. *J Am Dent Assoc*, **137**(7): 1013–1020. <https://doi.org/10.14219/jada.archive.2006.0324>
- Sgolastra F, Petrucci A, Gatto R, Monaco A (2011). Effectiveness of laser in dentinal hypersensitivity treatment: A systematic review. *J Endod*, **37**(3): 297–303. <https://doi.org/10.1016/j.joen.2010.11.034>
- Sicilia A, Cuesta-Frechoso S, Suárez A, Angulo J, Pordomingo A, De Juan P (2009). Immediate efficacy of diode laser application in the treatment of dentine hypersensitivity in periodontal maintenance patients: A randomized clinical trial. *J Clin Periodontol*, **36**(8): 650–660. <https://doi.org/10.1111/j.1600-051X.2009.01433.x>
- Soares ML, Porciúncula GB, Lucena MI, Gueiros LA, Leão JC, Carvalho AA (2016). Efficacy of Nd:YAG and GaAlAs lasers in comparison to 2% fluoride gel for the treatment of dentinal hypersensitivity. *Gen Dent*, **64**(6): 66–70.
- Vieira AH, Passos VF, de Assis JS, Mendonça JS, Santiago SL (2009). Clinical evaluation of a 3% potassium oxalate gel and a GaAlAs laser for the treatment of dentinal hypersensitivity. *Photomed Laser Surg*, **27**(5): 807–812. <https://doi.org/10.1089/pho.2008.2364>

Walsh LJ (1997). The current status of low level laser therapy in dentistry. Part 2. Hard tissue applications. *Aust Dent J*, **42**(5): 302–306. <https://doi.org/10.1111/j.1834-7819.1997.tb00134.x>

Wilder-Smith P (1988). The soft laser: Therapeutic tool or popular placebo? *Oral Surg Oral Med Oral Pathol*, **66**(6): 654–658. [https://doi.org/10.1016/0030-4220\(88\)90311-8](https://doi.org/10.1016/0030-4220(88)90311-8)

Yilmaz HG, Kurtulmus-Yilmaz S, Cengiz E (2011). Long-term effect of diode laser irradiation compared to sodium fluoride varnish in the treatment of dentine hypersensitivity in periodontal maintenance patients: A randomized controlled clinical study. *Photomed Laser Surg*, **29**(11): 721–725. <https://doi.org/10.1089/pho.2010.2974>