

CASE REPORT

Volume 16 Issue 1 2021

DOI: 10.21315/aos2021.16.1.7

ARTICLE INFO

Submitted: 20/2/2020

Accepted: 10/1/2021

Online: 25/6/2021

Challenges in Managing a Fractured Cement-retained Crown Located at the Aesthetic Zone: A Case Report

Oon Take Yeoh^{a*}, Wei Cheong Ngeow^b

^aDepartment of Restorative Dentistry, Faculty of Dentistry, University of Malaya, 50603 Kuala Lumpur, Malaysia

^bDepartment of Oral & Maxillofacial Clinical Sciences, Faculty of Dentistry, University of Malaya, 50603 Kuala Lumpur, Malaysia

* Corresponding author: yotum dental@um.edu.my

How to cite this article: Yeoh OT, Ngeow WC (2021). Challenges in managing a fractured cement-retained crown located at the aesthetic zone: A case report. *Arch Orofac Sci*, 16(1): 69–75. <https://doi.org/10.21315/aos2021.16.1.7>

To link to this article: <https://doi.org/10.21315/aos2021.16.1.7>

ABSTRACT

Implant prosthesis is a popular treatment modality but it is not complication free. This article discussed the management of a cemented, all-ceramic implant crown in the maxillary anterior region that had veneering ceramic fracture after three years in function. A screw-retained prosthesis was prescribed to avoid the show of the screw access channel on the incisal edge of the crown. This was achieved by changing the location of the screw hole using the angle screw channel that overcame the angulation issue.

Keywords: Angle correction abutment; angle screw channel; angle correction; screw-retained crown

INTRODUCTION

Implant prosthesis is a popular treatment modality to replace the extracted tooth. It was first introduced to rehabilitate fully edentulous jaws and later was used to replace missing teeth in the partially edentulous jaws (Adell *et al.*, 1981; Jemt, 1986). It is projected that there will be an increase in the need and demand for prosthodontic treatments and thus, one shall expect that the prescription of dental implants will continue to increase over the years (Douglass & Watson, 2002).

Despite its promising clinical performance and results, dental implants and implant prosthesis are not complication free (Gervais & Wilson, 2007; Jung *et al.*, 2012; Pjetursson

et al., 2012; Pjetursson *et al.*, 2014). The prosthetic complication rate is rather high. Earlier results that were published before the year 2000 reported an annual failure rate (AFR) of 5.07% for screw-retained prosthesis but this had decreased to 0.65% for studies that were published after the year 2000 (Pjetursson *et al.*, 2014). On the other hand, cement-retained prosthesis' AFR was 0.99% before the year 2000 and this figure reduced to 0.42% for clinical reports that were published after the year 2000. This shows that there is not much difference in terms of prosthetic complications regardless of the retention method used. The incidence of veneering ceramic fracture for a cemented implant crown is as high as 3.2% after five years (Pjetursson *et al.*, 2014).

One of the challenges in implant dentistry is to get the implant placed in the right position that allows a direct screw-retained prosthesis placement in the aesthetic zone. Although this may not always be the case, cement-retained implant prosthesis often is prescribed due to insufficient pre-operative planning and implant placement strategy (Chee & Jivraj, 2006). Another option includes the use of a cross-pinned prosthesis to overcome the angulation issue (Gervais *et al.*, 2008). The recent concept of angle screw channel was introduced and serves as an additional option in dealing with implants with suboptimal placement (Cavallaro & Greenstein, 2011; Berroeta *et al.*, 2015; Gjølvdal *et al.*, 2016).

This article discussed the management of a cemented, all-ceramic implant crown in the maxillary anterior region that had veneering ceramic fracture after three years in function. A screw-retained prosthesis was prescribed to avoid the appearance of the screw access channel on the incisal edge of the crown.

CASE REPORT

A 60-year-old female presented for extraction of tooth 11 followed by immediate implant placement in 2015 (TS III SA, Osstem, South Korea) followed by immediate loading. The last prosthesis was a cement-retained porcelain-fused to zirconia (PFZ) crown on a customised computer-aided design and manufactured (CAD/CAM) titanium abutment. After two and a half years in function, the patient returned with the complaint of the implant crown chipped off as she accidentally bit on a nut (Fig. 1). She was not keen to have a new crown made and opted to have a direct repair done. As a reliable resin bonding was not expected to be achieved with zirconia material, retention grooves were prepared and direct repair was carried out with composite material as a provisional measure (Fig. 2). Four months later, she came back with the same complaint and clinical examination noted that the composite material that was used to repair

the crown has dislodged. Another repair with composite was attempted. However, it only lasted for about two months. The patient finally was convinced that a new implant crown was needed and consented to have the implant crown remade.

The implant axis was assessed and determined through the working model that was prepared for implant crown fabrication made in the year 2015 (Fig. 3). This allowed a screw hole to be located and accessed accurately using a coarse grit diamond bur (Meisinger, Germany), however it has caused unavoidable damage to the crown as this access was located on its incisal edge (Fig. 4). As the patient was satisfied with the emergence profile of the crown, the impression coping was modified with a flowable composite to capture the soft tissue profile so that the dental technician was able to copy the contour (Fig. 5). The impression coping was then picked up with polyether material (Soft Monophase, 3M ESPE) (Fig. 6).

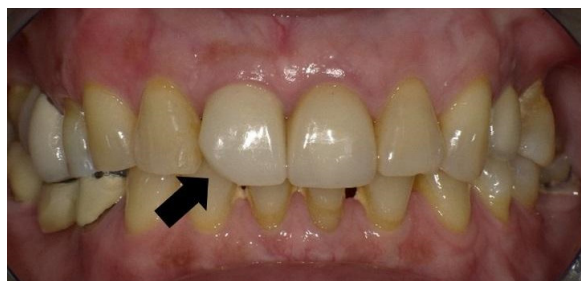

Fig. 1 Chipped veneering ceramic which has been repaired with composite using a porcelain kit. However, it only lasted for six months after two attempt of repair.

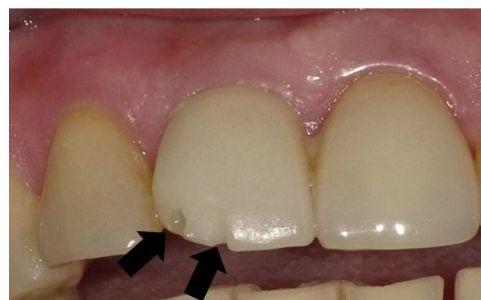

Fig. 2 Retention grooves were prepared to aid in composite retention.

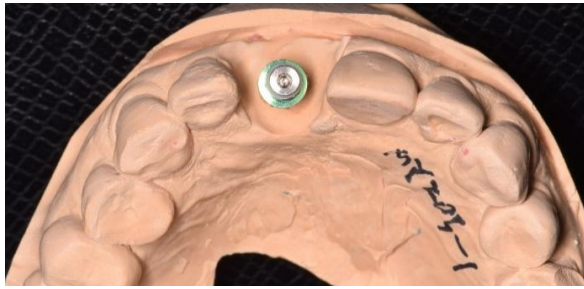


Fig. 3 Implant axis was assessed on the working model.

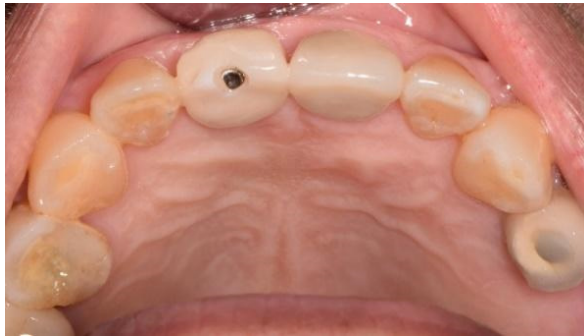

Fig. 4 Accurate access to abutment screw that was located directly over the incisal edge of the crown.

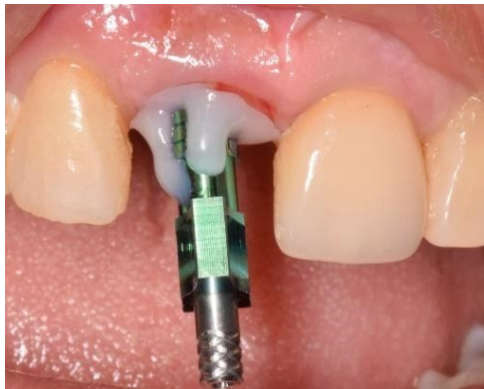

Fig. 5 Modified impression coping to capture the soft tissue profile.

A decision was made to convert the cement-retained prosthesis into a screw-retained prosthesis by using an angle screw channel abutment to facilitate future maintenance work, and to facilitate crown removal in case of porcelain fracture. Titanium base abutment with angle screw channel (Dynamic TiBase®, Dynamic Abutment® Solutions, Lleida, Spain) was used for the new prosthesis. The working model

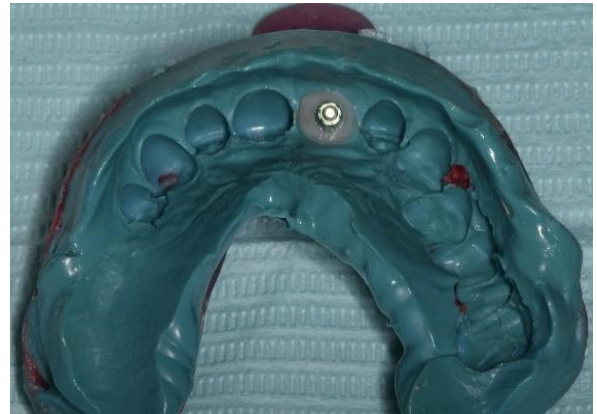

Fig. 6 Modified impression coping was picked up in the impression.

was scanned with the scanbody (Dynamic Abutment Scanbody, Dynamic Abutment® Solutions, Lleida, Spain) and the final prosthesis was designed with CAD software (Dental System™ 2017 Premium, 3Shape, Copenhagen, Denmark). The CAD image showed the amount of angle correction that was needed in order to bring the screw access channel palatally for a screw retained prosthesis. (Fig. 7). The metal coping was then prepared by milling with a 5-axis milling machine (Zenotec select hybrid, Wieland Dental, Ivoclar Vivadent Group). A metal-ceramic prosthesis was then fabricated for a direct to implant, screw-retained crown (Fig. 8).

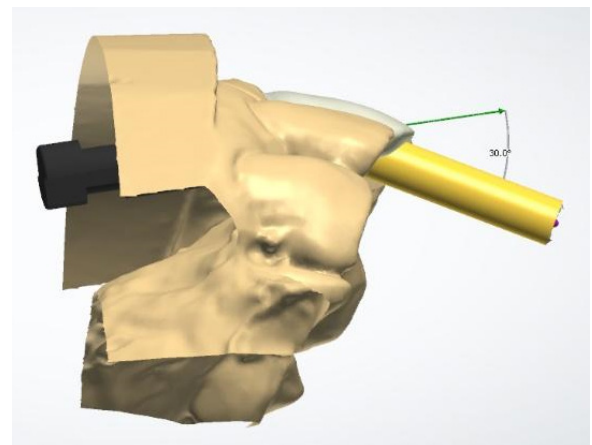


Fig. 7 Digital design of the crown indicating 30 degree of angle correction was required to bring the screw access channel palatally.

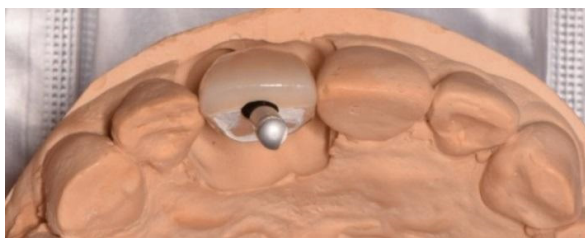


Fig. 8 Direct screw access with the implant driver.

During insertion visit, the screw-retained implant crown was tried-in for aesthetic and occlusal adjustment. The implant was then inserted and torqued to 25N/cm using the Dynamic screwdriver. This was followed by packing of polytetrafluoroethylene (PTFE) tape to protect the screw head and the screw access hole was sealed temporarily with a temporary cement (IRM, Dentsply Sirona). Subsequently, a review appointment was carried out before the screw access hole was sealed with a bonding agent (One Coat 7 Universal, Coltene, Switzerland) and resin composite (Fig. 9 and Fig. 10).

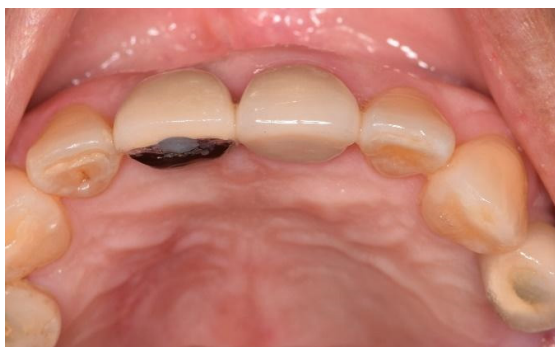

Fig. 9 The implant crown was inserted and screwed, followed by sealing of the access hole with composite.

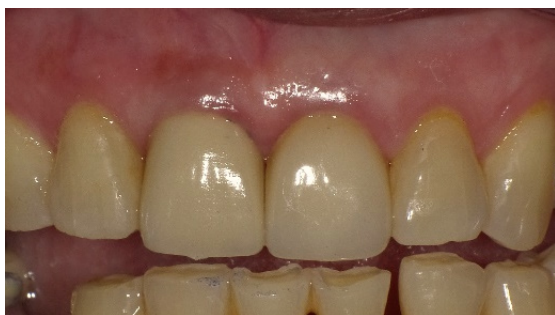

Fig. 10 Labial view of the implant crown; note the cervical contour of previous crown was copied.

DISCUSSION

The management of an implant crown with veneering ceramic fracture is always challenging. A direct repair would be the most cost effective and convenient way to rectify this unfortunate situation. However, it requires specific equipment to be used in order to increase the longevity of the repair (Özcan & Niedermeier, 2002; Özcan, 2003). The scenario was further complicated by the use of a PFZ prosthesis as surface treatment and bonding on a zirconia structure is more challenging (Tzanakakis *et al.*, 2016). There is currently no universally accepted method to obtain a predictable chemical bonding on a zirconia substructure, especially in an aged zirconia, which has been in function for years. Micromechanical retention methods could be employed and even that failed to enhance the success of the direct repair procedure for this current patient. Clinically, it is also difficult for clinicians to determine the fracture patterns, cohesive fracture within veneering porcelain, adhesive fracture between veneering porcelain and zirconia or a mixed pattern (Al-Amleh *et al.*, 2010). This has a profound implication on the success of the repair as different surfaces would require different approaches for surface treatment.

Retrieving a cement-retained implant crown can also be a tedious and risky procedure. Various methods have been proposed to facilitate this act but none is a perfect solution (Patil, 2011; Wicks *et al.*, 2012; Buzayan *et al.*, 2014; Krishnan *et al.*, 2014; Kheur *et al.*, 2015). Unscrewing the splinted prosthesis would not have been possible if the implant had a deep internal connection design (Patil, 2011). In many of the clinical cases, the techniques used to retrieve the prostheses allowed them to be reused after screw tightening or repair but these were not applicable to our case as gaining access to the screw itself would have rendered the crown unsightly as the screw access hole encroached the incisal edge and part of the labial area. Thus, instead of using a cement-retained prosthesis, a screw-retained prosthesis was planned so that it is easily retrievable in future for maintenance.

The angle screw channel abutment design, in particular the Dynamic Abutment, was introduced in 2004 (Berroeta *et al.*, 2015). Its original design was a variant of the conventional UCLA abutment pattern, with the substructures of the implant prosthesis being either cast to a preformed connection area or as a fully castable design. The manufacturer later launched the titanium base abutment that allows screw-cement retained prosthesis to have angle correction as well. Dynamic Abutment, however, is not a genuine component for most of the implant companies. Major implant companies that supply angle screw abutment include Nobel Biocare (Angulated Screw Channel (ASC); up to 25° correction, Nobel Biocare), Straumann (Variobase® for Crown AS; up to 25° correction, Straumann) and Dentsply Sirona Implants (Atlantis® Custom Base Solution with angulated screw access, up to 30° correction, Dentsply Sirona). Other companies that offer a similar solution are cara I-Butment (Kulzer GmbH; up to 25° correction) and Osteon Bi-Axial screw (Osteon Medical, Melbourne, Australia; up to 30° correction). The Dynamic Abutment allows angle correction up to 30°. The current generation of angle screw abutment system allows a full digital workflow using proprietary CAD/CAM systems.

A metal-ceramic final prosthesis was planned to replace the previous PFZ crown in the current case. Ceramic chipping remains as one of the most frequent complications for densely-sintered zirconia (Sailer *et al.*, 2015). With the advancement of CAD/CAM technology, there is an increasing trend of the prescriptions of implant prosthesis with monolithic ceramic material that is cemented to a titanium insert. However, there is insufficient clinical data to support its routine use without restriction (Conejo *et al.*, 2017). Furthermore, fabrication of PFZ prosthesis is technique sensitive as the technician has to provide a zirconia substructure with adequate support for veneering porcelain, using the veneering ceramic with the right coefficient of thermal expansion, cooling protocol and to finish and polish the

prosthesis using the correct instrument with care. Therefore, a PFM prosthesis was indicated to minimise the factors that can affect the success of the prosthesis.

Certainly a new cement-retained implant crown can be fabricated as a new prosthetic replacement for the chipped crown, even though the crown is retrievable. The authors believed that it is not ideal to repair a chipped ceramic repair for two reasons. Firstly, as titanium is highly reactive to the oxidation process, firing the implant crown in the ceramic furnace to separate the prosthesis from the abutment would oxidise the connection area and further affect the quality of fit of the abutment. Secondly, one needs to consider a more frequent prosthetic complication, which is screw loosening. The incidence for a loosen screw in an implant prosthesis is as high as 1.82% annually (Pjetursson *et al.*, 2014). If this occurs in a cement-retained prosthesis, particularly in this case, an access hole to an abutment screw needs to be prepared and this will definitely leave the crown with an unaesthetic appearance. Therefore, a screw-retained implant crown is not an unreasonable choice for the patient. Such a screw-retained crown will facilitate future maintenance work to be carried out for the implant and its prosthesis.

In summary, this paper shows a case example, where an angle screw abutment design was used to overcome implant angulation issues. Angle screw abutment also can be used for cases in which the ridge anatomy does not allow a direct to implant prosthesis to be planned. This is a common scenario in the maxillary anterior region, where the ridge anatomy does not allow implants to be placed in a palatal position for screw-retained prosthesis. This is in accordance with the findings from a retrospective clinical study that reported that majority of the angulated screw abutments were used to restore implant in the maxillary anterior region (Greer *et al.*, 2017). If the pre-operative planning was carried out adequately, the clinician then will have the opportunity to choose

an implant system that supplies the angle screw abutment. This will avoid the use of a non-genuine, third party solution to resolve the implant angulation issue.

REFERENCES

- Adell R, Lekholm U, Rockler B, Brånemark PI (1981). A 15-year study of osseointegrated implants in the treatment of the edentulous jaw. *Int J Oral Surg*, **10**(6): 387–416. [https://doi.org/10.1016/s0300-9785\(81\)80077-4](https://doi.org/10.1016/s0300-9785(81)80077-4)
- Al-Amleh B, Lyons K, Swain M (2010). Clinical trials in zirconia: a systematic review. *J Oral Rehabil*, **37**(8): 641–652. <https://doi.org/10.1111/j.1365-2842.2010.02094.x>
- Berroeta E, Zabalegui I, Donovan T, Chee W (2015). Dynamic abutment: A method of redirecting screw access for implant-supported restorations: Technical details and a clinical report. *J Prosthet Dent*, **113**(6): 516–519. <https://doi.org/10.1016/j.prosdent.2014.11.009>
- Buzayan MM, Mahmood WAA, Yunus N (2014). A simple procedure for retrieval of a cement-retained implant-supported crown: A case report. *Quintessence Int*, **45**(2): 125–128. <https://doi.org/10.3290/j.qi.a31008>
- Cavallaro J Jr, Greenstein G (2011). Angled implant abutments: A practical application of available knowledge. *J Am Dent Assoc*, **142**(2): 150–158. <https://doi.org/10.14219/jada.archive.2011.0057>
- Chee W, Jivraj S (2006). Screw versus cemented implant supported restorations. *Br Dent J*, **201**(8): 501. <https://doi.org/10.1038/sj.bdj.4814157>
- Conejo J, Kobayashi T, Anadioti E, Blatz MB (2017). Performance of CAD/CAM monolithic ceramic implant-supported restorations bonded to titanium inserts: A systematic review. *Eur J Oral Implantol*, **10**(Suppl 1): 139–146.
- Douglass CW, Watson AJ (2002). Future needs for fixed and removable partial dentures in the United States. *J Prosthet Dent*, **87**(1): 9–14. <https://doi.org/10.1067/mpr.2002.121204>
- Gervais MJ, Hatzipanagiotis P, Wilson PR (2008). Cross-pinning: The philosophy of retrievability applied practically to fixed, implant-supported prostheses. *Aus Dent J*, **53**(1): 74–82. <https://doi.org/10.1111/j.1834-7819.2007.00013.x>
- Gervais MJ, Wilson PR (2007). A rationale for retrievability of fixed, implant-supported prostheses: a complication-based analysis. *Int J Prosthodont*, **20**(1): 13–24.
- Gjelvold B, Sohrabi MM, Chrcanovic BR (2016). Angled Screw Channel: An alternative to cemented single-implant restorations – Three clinical examples. *Int J Prosthodont*, **29**(1): 74–76. <https://doi.org/10.11607/ijp.4686>
- Greer AC, Hoyle PJ, Vere JW, Wragg PF (2017). Mechanical complications associated with angled screw channel restorations. *Int J Prosthodont*, **30**(3): 258–259. <https://doi.org/10.11607/ijp.5150>
- Jemt T (1986). Modified single and short-span restorations supported by osseointegrated fixtures in the partially edentulous jaw. *J Prosthet Dent*, **55**(2): 243–247. [https://doi.org/10.1016/0022-3913\(86\)90352-5](https://doi.org/10.1016/0022-3913(86)90352-5)
- Jung RE, Zembic A, Pjetursson BE, Zwahlen M, Thoma DS (2012). Systematic review of the survival rate and the incidence of biological, technical, and aesthetic complications of single crowns on implants reported in longitudinal studies with a mean follow-up of 5 years. *Clin Oral Implants Res*, **23**(Suppl 6): 2–21. <https://doi.org/10.1111/j.1600-0501.2012.02547.x>
- Kheur M, Harianawala H, Kantharia N, Sethi T, Jambhekar S (2015). Access to abutment screw in cement retained restorations: A clinical tip. *J Clin Diagn Res*, **9**(2): ZD17–ZD18. <https://doi.org/10.7860/JCDR/2015/11159.5607>

- Krishnan V, Tony Thomas C, Sabu I (2014). Management of abutment screw loosening: Review of literature and report of a case. *J Indian Prosthodont Soc*, **14**(3): 208–214. <https://doi.org/10.1007/s13191-013-0330-2>
- Özcan M (2003). Evaluation of alternative intra-oral repair techniques for fractured ceramic-fused-to-metal restorations. *J Oral Rehabil*, **30**(2): 194–203. <https://doi.org/10.1046/j.1365-2842.2003.01037.x>
- Özcan M, Niedermeier W (2002). Clinical study on the reasons for and location of failures of metal-ceramic restorations and survival of repairs. *Int J Prosthodont*, **15**(3): 299–302.
- Patil PG (2011). A technique for repairing a loosening abutment screw for a cement-retained implant prosthesis. *J Prosthodont*, **20**(8): 652–655. <https://doi.org/10.1111/j.1532-849X.2011.00748.x>
- Pjetursson BE, Asgeirsson AG, Zwahlen M, Sailer I (2014). Improvements in implant dentistry over the last decade: Comparison of survival and complication rates in older and newer publications. *Int J Oral Maxillofac Implants*, **29**(Suppl): 308–324. <https://doi.org/10.11607/jomi.2014suppl.g5.2>
- Pjetursson BE, Thoma D, Jung R, Zwahlen M, Zembic A (2012). A systematic review of the survival and complication rates of implant-supported fixed dental prostheses (FDPs) after a mean observation period of at least 5 years. *Clin Oral Implants Res*, **23**(Suppl 6): 22–38. <https://doi.org/10.1111/j.1600-0501.2012.02546.x>
- Sailer I, Makarov NA, Thoma DS, Zwahlen M, Pjetursson BE (2015). All-ceramic or metal-ceramic tooth-supported fixed dental prostheses (FDPs)? A systematic review of the survival and complication rates. Part I: Single crowns (SCs). *Dent Mater*, **31**(6): 603–623. <https://doi.org/10.1016/j.dental.2015.02.011>
- Tzanakakis EG, Tzoutzas IG, Koidis PT (2016). Is there a potential for durable adhesion to zirconia restorations? A systematic review. *J Prosthet Dent*, **115**(1): 9–19. <https://doi.org/10.1016/j.prosdent.2015.09.008>
- Wicks R, Shintaku WH, Johnson A (2012). Three-dimensional location of the retaining screw axis for a cemented single tooth implant restoration. *J Prosthodont*, **21**(6): 491–493. <https://doi.org/10.1111/j.1532-849X.2012.00887.x>