

Case series of children with steroid-Induced glaucoma

Lam CS , Umi Kalthum MN, Norshamsiah MD, Bastion MLC

Lam CS, Umi Kalthum MN, Norshamsiah MD, et al. Case series of children with steroid-Induced glaucoma. *Malays Fam Physician*. 2018;13(3): 32–37.

Keywords:

Steroid ophthalmic solutions, child, drug-related side effects and adverse reactions, glaucoma, filtering surgery

Authors:

Norshamsiah Md Din

(Corresponding author)
Department of Ophthalmology,
Universiti Kebangsaan Malaysia
Medical Center, Jalan Yaacob Latiff,
56000 Cheras, Kuala Lumpur
Malaysia
Email: shamsiahdr@hotmail.com

Lam ChenShen

Department of Ophthalmology
Universiti Kebangsaan Malaysia
Kuala Lumpur, Malaysia

Umi Kalthum Md Noh

Department of Ophthalmology
Universiti Kebangsaan Malaysia
Medical Center, Kuala Lumpur
Malaysia

Mae-Lynn Catherine Bastion

Department of Ophthalmology
Universiti Kebangsaan Malaysia
Medical Center, Kuala Lumpur
Malaysia

Abstract

Steroid-induced glaucoma is the most serious complication of the injudicious use of steroids, particularly among children affected by allergic conjunctivitis. This condition is steroid-dependent, and children are commonly being prescribed topical anti-inflammatories, including topical steroids, by general practitioners. Furthermore, topical steroids are also available over the counter, and this availability contributes to overuse without proper monitoring by an ophthalmologist. We present a series of five cases illustrating the devastating effect of unmonitored, long-term use of steroids among children for vernal keratoconjunctivitis. The medications were prescribed initially by general ophthalmologists and were continually bought over the counter by parents. At the presentation to our center, these patients were already compromised visually, exhibiting glaucomatous optic disc changes and high intraocular pressure. The series highlights the optic nerve damage resulting in irreversible visual compromises among children on long-term, topical steroids and the importance of regular monitoring with a low threshold for ophthalmologist referral.

Introduction

Vernal keratoconjunctivitis (VKC) is a chronic, atopic ocular surface disease, which involves mainly IgE-mediated hypersensitivity reactions. Recent studies suggest non-IgE-mediated reactions involving a multitude of cells, including eosinophils, mononuclear cells, neutrophils, and CD4 T-helper cells.¹⁻³ It affects mainly boys in the first decades of life. Patients usually present with itchy, inflamed red eyes, photophobia, and foreign body sensation. Associated giant papillae over tarsal conjunctiva and limbus worsen the gritty sensations and induce more eye rubbing, with detrimental effects to ocular surface health. Over time, chronic micro- and macro-erosions of the corneal epithelium leads to shield-ulcer formation and eventual corneal vascularization. This vascularization not only leads to permanent visual problems, but it also reduces the chance of corneal graft survival should a graft be needed for visual rehabilitation in the future.^{4,5}

Corticosteroid is a potent and commonly used agent which is often prescribed to control ocular inflammation following surgery, VKC, or uveitic conditions.⁶ Various forms of topical corticosteroid are available at various concentrations, including Betamethasone 0.2%, Dexamethasone 0.5%, Prednisolone 1%, and Fluoromethalone (FML) 0.1%. Any of these preparations have the potential to induce ocular hypertension in susceptible

individuals, known as steroid responders. Ocular hypertension, which is defined as elevation of intraocular pressure, may subsequently cause optic nerve damage and visual field defects, and, ultimately, steroid-induced glaucoma. As the glaucoma progresses, patients will sustain irreversible visual losses and, potentially, eventual blindness. Both the concentration and duration of usage are proportionate to the risk.⁶

Steroids are often known as “wonder drugs” which alleviate the VKC symptoms rapidly and effectively. Due to the chronicity of VKC and effectiveness of topical steroid for this condition, young patients tend to have prolonged prescriptions. The availability of topical steroids at general practitioners’ clinics and over-the-counter pharmacies leads to overuse of this agent. The potential risk of visual loss due to cataracts and glaucoma may easily have been overlooked; hence, proper counseling to parents is not delivered. Children are at higher risk than adults for being steroid responders.^{7,9} VKC, which tends to wax and wane with different environmental exposures and food consumption patterns, leads to the prolonged use of topical steroids among children, in particular.

Therefore, clinicians and pharmacists should be more vigilant in prescribing steroid eye drops to children with VKC. In this case series, we report on cases of steroid-induced glaucoma in children with VKC.

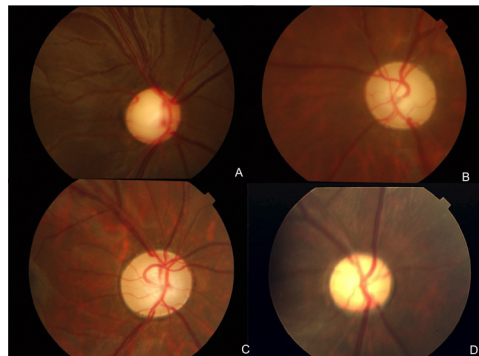


Figure 1: Optic disc photos showing advanced cupping of the disc.

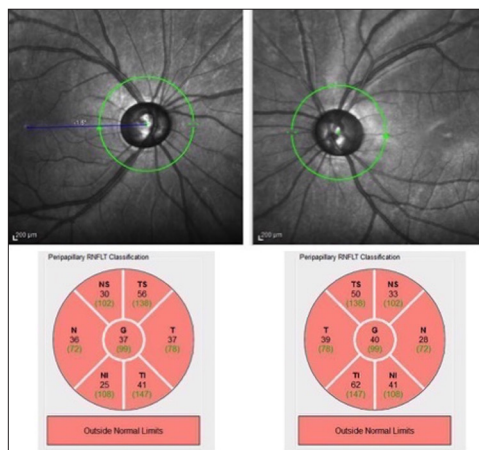


Figure 2: Optical coherence tomography of retinal nerve fiber layer (OCT RNFL) of patient Case 2 showing thinning of both nerve fiber layers

Case Reports

Case 1

A 10-year-old Malay boy with a history of four years of vernal keratoconjunctivitis was referred from a private ophthalmologist for uncontrolled intraocular pressure (IOP) in the right eye despite the use of four topical anti-glaucoma agents. Upon presentation, his right eye visual acuity was 6/18, while the acuity in the left eye was 6/12. There was marked relative afferent pupillary defect (RAPD) in the right eye and its IOP was 30mmHg, while the left eye's IOP was 12mmHg. The right eye optic disc was pale with a cup-to-disc ratio (CDR) of 0.9 (Figure 1: A), while left eye had a CDR of 0.5. The visual field (VF) showed tunnel vision in the right eye (Figure 4: A – Right eye), while left eye field was normal. This young patient had been using fluoromethalone eye drops regularly since 2008. Despite maximum glaucoma medical therapy, his eye deteriorated due to poorly controlled IOP, and he subsequently underwent a right eye trabeculectomy with mitomycin C (MMC). The right eye IOP was eventually controlled with a single anti-glaucoma agent, and the left

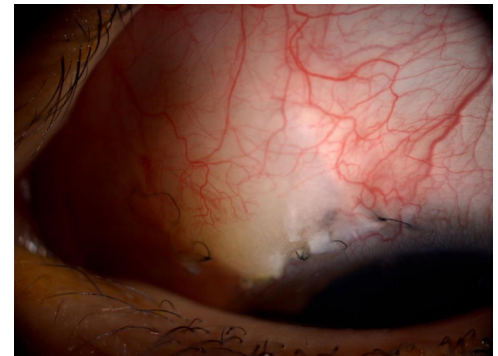


Figure 3: Trabeculectomy done on patient Case 2.

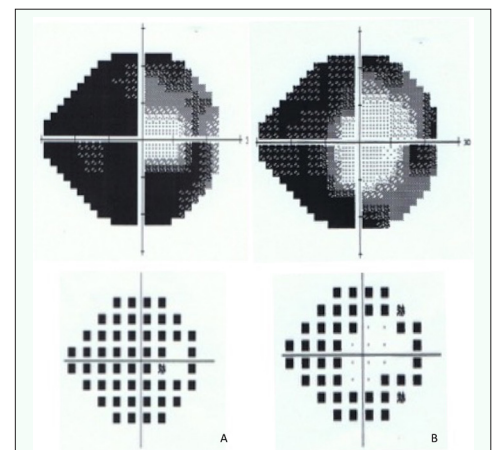


Figure 4: HVF showing tunnel vision in right eye of patients in Cases 1 and 2.

eye IOP was controlled with one anti-glaucoma agent without surgical intervention. The VKC is currently controlled with cyclosporine eye drops and tacrolimus eye ointment. His current visual acuity in the right eye is 6/12 and 6/9 in the left eye. His visual field remains similar to the initial presentation.

Case 2

An 11-year-old Malay girl with a four-year history of VKC was referred from a private ophthalmologist for uncontrolled IOP in both eyes. She was diagnosed with allergic conjunctivitis and started initially on topical Maxidex 0.5%, which she had been buying over the counter ever since without an ophthalmologist's supervision. Upon examination, her visual acuity was 6/24 bilaterally; the IOP was 42mmHg for the right eye and 40mmHg for the left eye. The optic discs were pale in both eyes, with almost full cupping. (Figure 1: B, C) (Figure 2: Optical coherence tomography of optic disc showing bilateral severe thinning of retinal nerve fiber layer). She underwent a trabeculectomy with MMC in

both eyes (**Figure 3**: Left eye trabeculectomy). The IOP of both eyes is well-controlled without anti-glaucoma medication at present. Her visual acuity remains the same as it was during the initial presentation, i.e., 6/24 bilaterally. The VF, which showed tunnel vision bilaterally upon initial presentation, has not worsened much over time (**Figure 4**: B – Right eye).

Case 3

A 10-year-old Malay boy, who was diagnosed as VKC at the age of 7, was referred for continuation of care for steroid-induced-glaucoma on two anti-glaucoma agents. He was on FML eye drops, oral prednisolone, and oral cyclosporine for the allergic eye disease. His IOP was otherwise well-controlled, the right eye reading was 17mmHg and left eye was at 18mmHg. His visual acuity upon presentation was 6/18 bilaterally, and a fundus examination showed pink optic discs, with cup-to-disc ratios of 0.7 bilaterally. There was a constricted VF, which was worse in the left eye. His IOP is well-controlled with the two anti-glaucoma agents at present.

Case 4

A 17-year-old Malay boy first presented at our center at the age of 14 with worsening allergic conjunctivitis. He had been on sodium chromoglycate eye drops and antihistamine eye drops. The patient, however, defaulted on follow-up. Due to the frequent flare-up of his VKC, he regularly used unprescribed topical steroids sold at the pharmacy without supervision from an ophthalmologist. At presentation, his visual acuity was 6/9 in both eyes, and the IOP was 36mmHg and 38mmHg in the right and left eyes, respectively, with cup-to-disc ratios of 0.6 bilaterally. Fortunately, his VF is within normal limits. To date, the patient's IOP is well-controlled with one anti-glaucoma medication and no surgical intervention.

Case 5

A 12-year-old Malay boy was referred to our center for poorly-controlled IOP despite maximal anti-glaucoma treatment and a history of glaucoma-filtering surgery in the left eye. He had suffered from VKC since the age of 4 and was diagnosed by a private ophthalmologist. His parents had brought him to many clinics, and he had been invariably using topical steroids, either prescribed by different clinics or sold over the counter. He was subsequently diagnosed with steroid-induced glaucoma at the age of 11. The left eye visual acuity was 6/24, while right eye had an acuity of 6/12, and the recorded IOPs were 12mmHg and 30mmHg for the right and left eye, respectively.

The optic discs were already pale at presentation with advanced cup-to-disc ratios of 0.9 (**Figure 1**: D), and the VF was constricted in the left eye. He had a repeat trabeculectomy with MMC in the left eye, and is currently doing well on one anti-glaucoma medication.

Discussion

Topical steroids are valuable agents in the treatment of a wide range of ocular disorders; however, their use is not without potential complications. The complications include cataracts, glaucoma, and opportunistic ocular infections. Steroid-induced glaucoma is one of the most debilitating diseases, as it may cause irreversible loss of vision and, potentially, blindness.

Steroid-induced glaucoma is due primarily to increased resistance to aqueous outflow. The exact mechanism is uncertain, but studies have shown that corticosteroid up-regulates production of ground substances over the endothelial lining of the trabecular meshwork (TM) itself. This production leads to microstructural changes in sponge-like TM and, subsequently, increases resistance to aqueous outflow.^{10,11} In-vitro studies have also shown that phagocytic activity of the TM is suppressed and enzymes, such as proteases, are reduced.^{10,12} Hence, debris deposition increases in the TM, resulting in a further increase in outflow resistance. Corticosteroids are demonstrable in the aqueous humor after 5 to 30 minutes of topical application. Most are lipophilic and readily permeate through the epithelium.¹³

The types of corticosteroid eye drops used and the duration of use are important determinants in the development of glaucoma.¹⁴ Dexamethasone eye drops are associated with a higher risk of glaucoma compared to prednisolone and fluoromethalone eye drops.^{14,15} Fluoromethalone has the smallest risk of causing ocular hypertension but nonetheless may lead to glaucoma if used over prolonged periods,¹⁶ as noted in Cases 1 and 3. Therefore, usage of drugs with lower potency does not guarantee increased safety.

Longer duration of use of topical steroids increases the risk of ocular hypertension. The rise in IOP is evident any time between hours to weeks after commencing topical corticosteroid use.^{6,17,18} Some studies have even suggested that usage for more than 8 to 10 weeks may result in irreversibly high IOP, which does not disappear even after withdrawal

Table 1: Summary of the case series

	Age (at presentation)	Race Gender	Types of topical corticosteroid	Duration of usage	Visual acuity upon presentation	IOP upon presentation (mmHg)	Cup-to-disc ratio upon presentation	HVF upon presentation (Mean deviation dB)	Surgical intervention	Number of anti-glaucoma medications at present	Current VA	Current VF (Mean deviation dB)	Cataract
Case 1	10	Malay Male	FML	7 years	6/18 (R) 6/12 (L)	30 (R) 12 (L)	0.9 (R) 0.5 (L)	-32.03 (R) -3.38 (L)	Yes	1 (R) 1 (L)	6/12 (R) 6/9 (L)	-29.86 (R) -6.80 (L)	Mild PSC
Case 2	11	Malay Girl	Dexamethasone	4 years	6/24 (R) 6/24 (L)	42 (R) 40 (L)	0.9 (R) 0.9 (L)	-27.37 (R) -29.10 (L)	Yes	0 (R) 0 (L)	6/24 (R) 6/24 (L)	-29.15 (R) -31.59 (L)	Mild PSC
Case 3	10	Malay Male	FML	3 years	6/18 (R) 6/18 (L)	17 (R) 18 (L)	0.7 (R) 0.7 (L)	-25.65 (R) -16.21 (L)	No	2 (R) 2 (L)	6/6 (R) 6/6 (L)	-20.00 (R) -21.77 (L)	Clear
Case 4	17	Malay Male	Dexamethasone	3 years	6/9 (R) 6/9 (L)	36 (R) 38 (L)	0.6 (R) 0.6 (L)	-3.43 (R) -2.98 (L)	No	1 (R) 1 (L)	6/9 (R) 6/9 (L)	-4.44 (R) -2.92 (L)	Clear
Case 5	12	Malay Male	Betamethasone	7 years	6/12 (R) 6/24 (L)	12 (R) 30 (L)	0.5 (R) 0.9 (L)	-4.85 (R) -30.10 (L)	Yes	1 (R) 1 (L)	6/9 (R) 6/12 (L)	-17.58 (R) -25.69 (L)	PSC

R – right eye, L – left eye, PSC – Posterior Subcapsular Cataract

of the medications.^{9,18} The persistence of elevated IOP despite steroid discontinuation is noted in all of the patients in this series. This irreversibility suggests that prolonged topical steroid use causes permanent changes to the microstructure of the TM.

Most patients remain symptom-free until significant glaucomatous optic nerve damage has occurred, as initial nerve fiber layer damage accompanied by a moderate visual field defect is often unnoticeable. Children, in particular, usually have no or vague complaints and therefore often present in the late stages of the disease. Two out of 5 cases (Cases 2 and 3) were already at the advanced stage of glaucoma, with significant visual morbidity, when they presented, and their visual fields had already been severely compromised. They now require lifelong treatment with anti-glaucoma medications. Three of the patients who required glaucoma filtering surgery had been using topical steroid for 4 years or more. These cases illustrate aptly that injudicious or prolonged use of steroid eye drops in children can lead to significant vision and VF impairment, leading to eventual blindness. Furthermore, these children developed glaucoma at a very young age, and being dependent on eye drops for their whole life not only exposes them to the adverse effects of medications, but also imposes a great burden on the family and the country's economy. The possibility of complete blindness is real, as glaucoma progression is only slowed by medication and not completely halted.

Steroid-induced cataracts are another potential complication of prolonged steroid usage among VKC children.¹⁹ This can lead to poor vision, as visually significant cataracts have been reported in a few studies,^{18,20} and these children may require early cataract operations. The most common type of cataract induced by steroids is the posterior subcapsular type,¹⁹ which was present in three patients in the series. However, their cataracts were not visually significant, and they did not require cataract operations. Furthermore, glaucoma surgery is known to predispose patients to cataracts, and cataracts may develop later in these individuals.¹⁸

The incidence of allergic eye disease is on the rise due to environmental factors and food consumption patterns. Among children, the disease can be more severe and difficult to control due to poor compliance with standard medications. Steroids are very effective anti-inflammatory agents, helping to relieve the symptoms of itchiness and able to improve the appearance of patients' eyes. Hence, parents tend to use steroids when their children have a flare-up of VKC. Unfortunately, many practitioners and parents are not aware of the detrimental effects of chronic topical steroid application to vision, namely, glaucoma and cataracts.

Children, compared to adults, are at higher risk of being steroid responders. Those aged less than 10 years old, show more rapid and severe increases in IOP,^{8,9} despite only being on twice-daily regimes.²¹ This rapid increase may be attributed to the degree of maturity of the drainage angle.⁸ In this case series, four cases were prescribed topical corticosteroids at the less than 10 years of age. This, again, emphasizes the importance of cautious use of topical corticosteroid in children, including proper monitoring and preferably under the continued care of an ophthalmologist. Therefore, parents should be informed of the danger posed to children, and proper follow-up must be emphasized when using steroids. We recommend that topical steroids for ocular use should only be prescribed by ophthalmologists with access to IOP monitoring.

Conclusion

This case series highlights the possibility of severe and permanent side effects stemming from topical steroid eye drops, especially among children. General physicians and pharmacists should be aware of the damaging effects of unregulated and chronic steroid usage. They need to exercise caution when treating patients with ocular allergies with steroids. Parents also should be educated on the potential side effects of steroid use in children, especially if prolonged usage is envisioned. Preferably, topical steroids should only be prescribed by ophthalmologists with proper monitoring of the IOP and other potential side effects.

How does this paper make a difference to general practice?

- It increases the awareness among general physicians and pharmacists regarding steroid-induced glaucoma, particularly among children, as they are more prone to this complication.
- It stresses the importance of educating patients and parents regarding this potential complication upon prescription of steroid eye drops in order to avoid unsupervised and/or prolonged usage.
- It recommends that steroid eye drops be preferably prescribed by an ophthalmologist with access to intraocular pressure monitoring.

References

- Bielory L. Allergic and immunologic disorders of the eye. Part I: Immunology of the eye. *J Allergy Clin Immunol.* 2000;106(5):805-16.
- Bielory L. Allergic and immunologic disorders of the eye. Part II: Ocular allergy. *J Allergy Clin Immunol.* 2000;106(5):805-16.
- Leonardi A, De Dominicis C, Motterle L. Immunopathogenesis of ocular allergy: A schematic approach to different clinical entities. *Curr Opin Allergy Clin Immunol.* 2007;7(5):429-35.
- Egrilmez S, Sahin S, Yagci A. The effect of vernal keratoconjunctivitis on clinical outcomes of penetrating keratoplasty for keratoconus. *Can J Ophthalmol.* 2004;39(7):772-7.
- Wagoner MD, Ba-Abbad R. Penetrating keratoplasty for keratoconus with or without vernal keratoconjunctivitis. *Cornea.* 2009;28(1):14-8.
- Kersey JB, Broadway DC. Corticosteroid-induced glaucoma: A review of the literature. *Eye (Lond).* 2006;20(4):407-16.
- Lam DS, Fan DS, Ng JS, et al. Ocular hypertensive and anti-inflammatory responses to different dosages of topical dexamethasone in children: A randomized trial. *Clin Exp Ophthalmol.* 2005; 33(2):252-258.
- Kwok AK, Lam DS, Ng JS, et al. Ocular hypertensive response to topical steroids in children. *Ophthalmology.* 1997;104(12):2112-6.
- Ang M, Ti SE, Loh R, et al. Steroid-induced ocular hypertension in Asian children with severe vernal keratoconjunctivitis. *Clin Ophthalmol.* 2012; 6:1253-8.
- Shan SW, Do CW, Lam TC, et al. New insight of common regulatory pathway in human trabecular meshwork cells in response to dexamethasone and prednisolone using an integrated quantitative proteomics: SWATH and MRM-HR mass spectrometry. *J Proteome Res.* 2017;16(10):3753-3765.
- Filla MA, Dimeo KD, Tong T, et al. Disruption of fibronectin matrix affects type IV collagen, fibrillin and laminin deposition into extracellular matrix of human trabecular meshwork (HTM) cells. *Exp Eye Res.* 2017;165:7-19.
- Tektas OY, Lutjen-Drecoll E. Structural changes of the trabecular meshwork in different kinds of glaucoma. *Exp Eye Res.* 2009; 88(4):769-75.
- McGhee CN, Dean S, Danesh-Meyer H. Locally administered ocular corticosteroids: Benefits and risks. *Drug Saf.* 2002; 25(1):35-55.
- Cantrill HL, Palmberg, Zink HA, et al. Comparison of in vitro potency of corticosteroids with ability to raise intraocular pressure. *Am J Ophthalmol.* 1975; 79(6):1012-1017.
- Mindel JS, Tavitian HO, Smith H, Walker EC. Comparative ocular pressure elevation by medrysone, fluorometholone, and dexamethasone phosphate. *Arch Ophthalmol.* 1980; 98(9):1577-8.
- Fan DS, Ng JS, Lam DS. A prospective study on ocular hypertensive and anti-inflammatory response to different dosages of fluorometholone in children. *Ophthalmology.* 2001;108(11):1973-7.
- Phulke S, Kaushik S, Kaur S, et al. Steroid-induced glaucoma: An avoidable irreversible blindness. *J Curr Glaucoma Pract.* 2017;11(2):67-72.
- Sihota R, Konkall VL, Dada T, Agarwal HC, Singh R. Prospective, long-term evaluation of steroid-induced glaucoma. *Eye (Lond).* 2008;22(1):26-30.
- Jobling AI, Augusteyn RC. What causes steroid cataracts? A review of steroid-induced posterior subcapsular cataracts. *Clin Exp Optim.* 2002; 85(2):61-75.
- Gupta S, Shah P, Grewal S, Chaurasia AK, Gupta V. Steroid-induced glaucoma and childhood blindness. *Br J Ophthalmol.* 2015; 59:1-3.
- Ng JS, Fan DS, Young AL, et al. Ocular hypertensive response to topical dexamethasone in children: A dose-dependent phenomenon. *Ophthalmology.* 2000;107(11):2097-100.