

A Review of the Clinical Significance of Lumbar Puncture in the Diagnostic Approach of Aneurysmal Subarachnoid Hemorrhage (SAH): A Case Report of CT-Negative and Lumbar Puncture-Positive SAH



Maria Vashti Zerlinda Lesmana,¹ Edrik Wiyogo,¹ Frandy Susatia,¹
Candra Wiguna,¹ Harsan Harsan¹

ABSTRACT

Headaches are a common presentation in the emergency department (ED). Even though not all are potentially serious, some such as subarachnoid hemorrhage (SAH) can be more dangerous than others. SAH is a medical emergency with an almost 50% mortality rate. It is crucial not to miss the diagnosis of SAH, as a missed or delayed diagnosis can be severely detrimental. It classically presents as thunderclap headache, a severe, sudden-onset headache. There are various approaches in diagnosing or excluding SAH, which is classically done by performing a computed tomography (CT) scan followed by a lumbar puncture (LP). But with the improved sensitivity of more modern diagnostic

tools, more physicians are in support of changing this classical teaching. The aim of this case report is to review the advantages and disadvantages of LP in diagnosing SAH, along with other diagnostic tools commonly used.

Keywords subarachnoid hemorrhage, lumbar puncture, cerebrospinal fluid, aneurysmal subarachnoid hemorrhage, brain ct scan, brain ct angiography, brain mr angiography

INTRODUCTION

Subarachnoid hemorrhage (SAH) constitutes about 5% of strokes and 1%-3% of all headaches.[1,2]

SAH may be uncommon, but it is a life-threatening condition, with mortality rates approaching 50%. It also carries significant risks of serious morbidity,[3-5] which is why prompt – and more importantly – accurate diagnosis is paramount. Historically, a LP has been used to rule out SAH after a negative CT result. But in more recent years, with the advent of modern CT scans and CT angiography,[6,7]_the role of LP as a means to rule out SAH has been questioned.

✉ Maria Vashti Zerlinda Lesmana
zerlindavs@gmail.com

¹ Siloam Hospitals Department of Neurology, Siloam Hospitals, Kebon Jeruk, Jakarta Indonesia

Academic editor: Raymond L. Rosales

Submitted date: September 24, 2023

Accepted date: October 31, 2023

Other factors that disfavor LP are the risks associated with LP, including postdural puncture headache (PDPH), iatrogenic infections and brainstem herniation. The procedure is also painful and anxiety-provoking for most patients, further shadowing its benefits.[8,9] Because of this, other diagnostic approaches have been suggested as alternatives to LP, such as CT angiography (CTA) or magnetic resonance angiography (MRA).[8,10,11] Despite that, LP is still recommended by the AHA/ASA 2023 Guidelines for the Management of Aneurysmal Subarachnoid Hemorrhage for CT negative patients presenting after 6 hours.[12] Spinal fluid investigation may also help point to

an alternative diagnosis in patients with atypical presentations.

Along with this case of CT-negative and LP-positive SAH, we aim to review the clinical significance of LP in the diagnostic approach of aneurysmal SAH, considering its risks and benefits to each patient and different individual circumstances.

CASE REPORT

A 50-year-old female patient was admitted to the hospital with severe throbbing headache which had started three days prior to admission. The headache became severe enough that it interfered with her

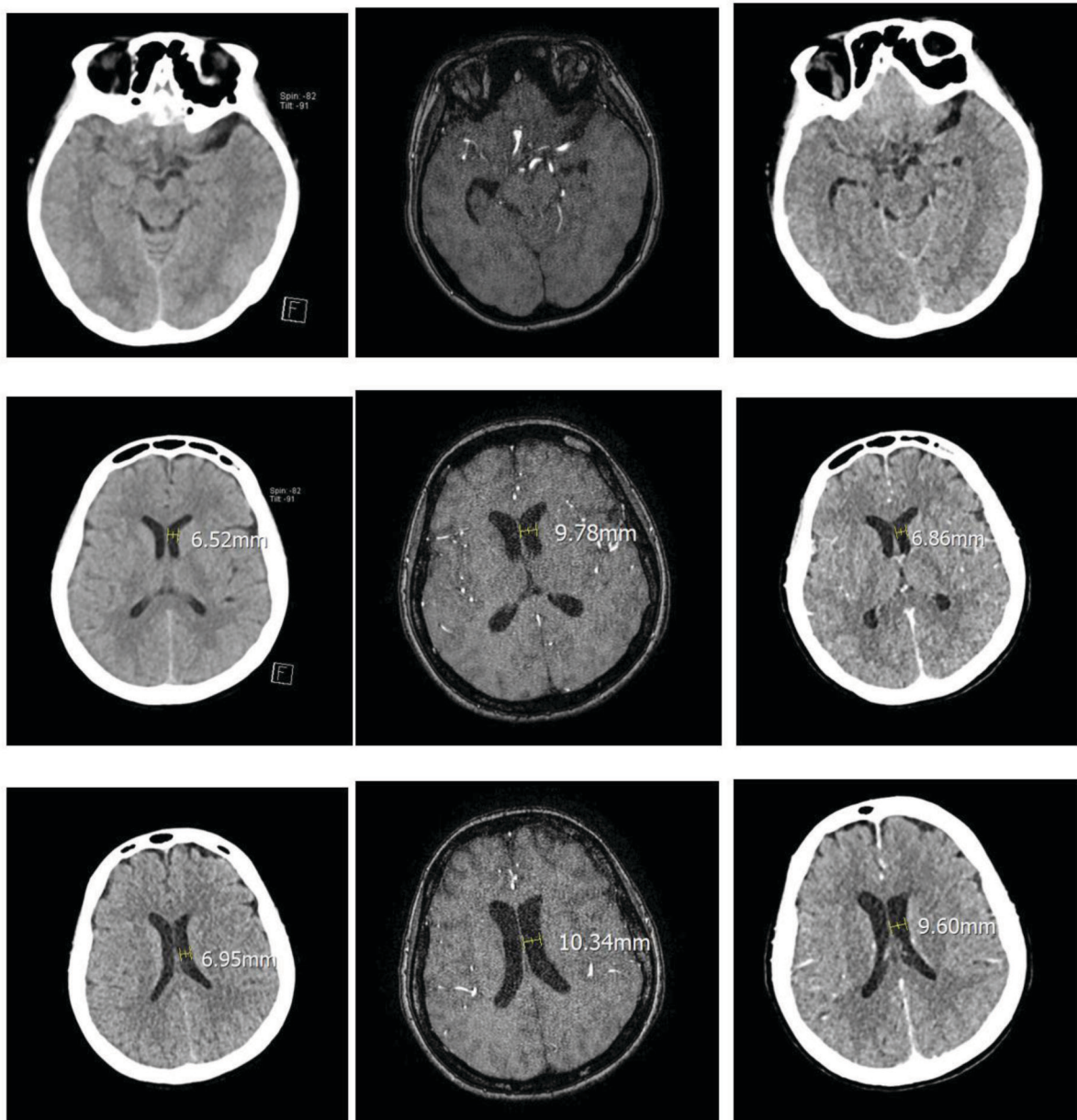


Figure 1 CT Brain Non-contrast (01/04/2023) vs MRI-MRA Brain (03/04/2023) vs CTA Brain (05/04/2023)

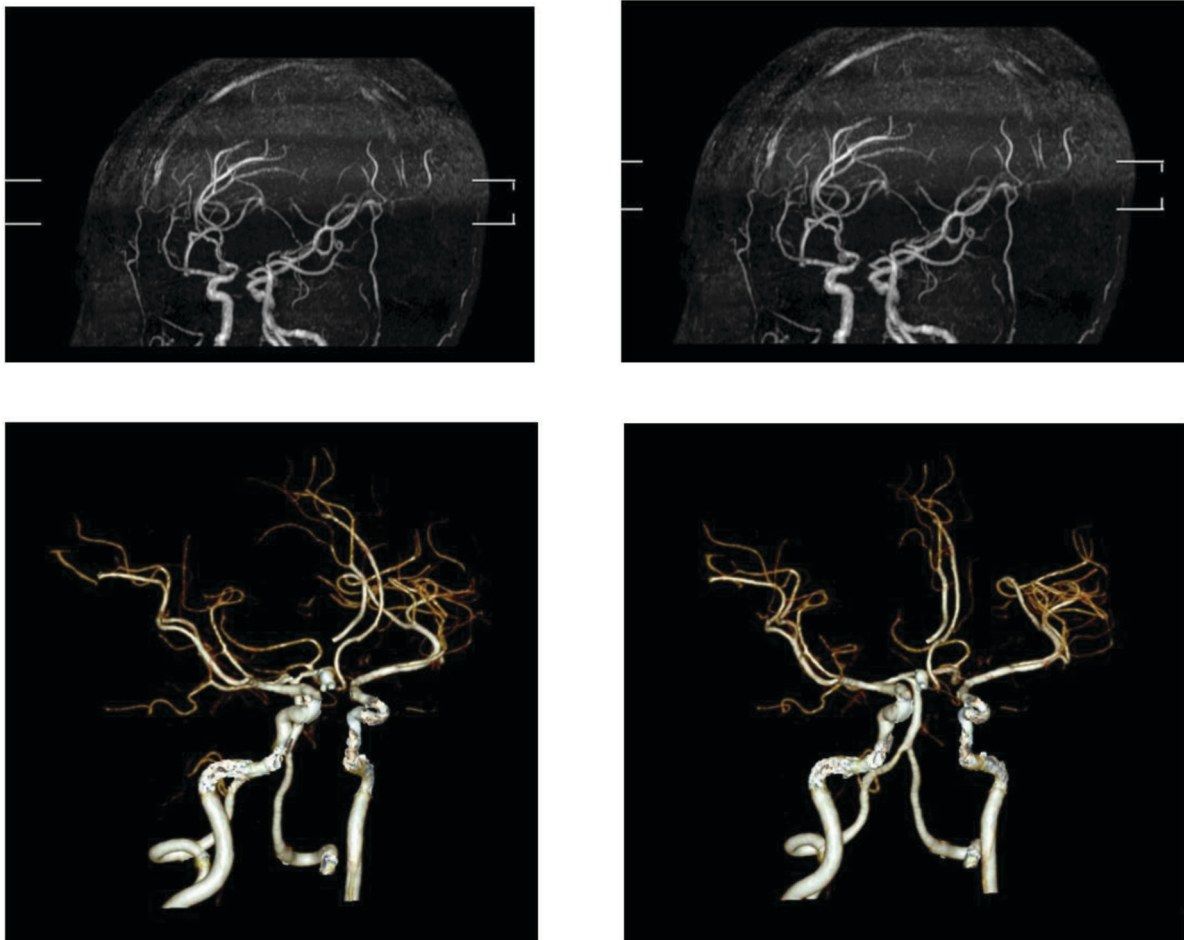


Figure 2 MRI-MRA Brain (03/04/2023) vs CTA Brain (05/04/2023)

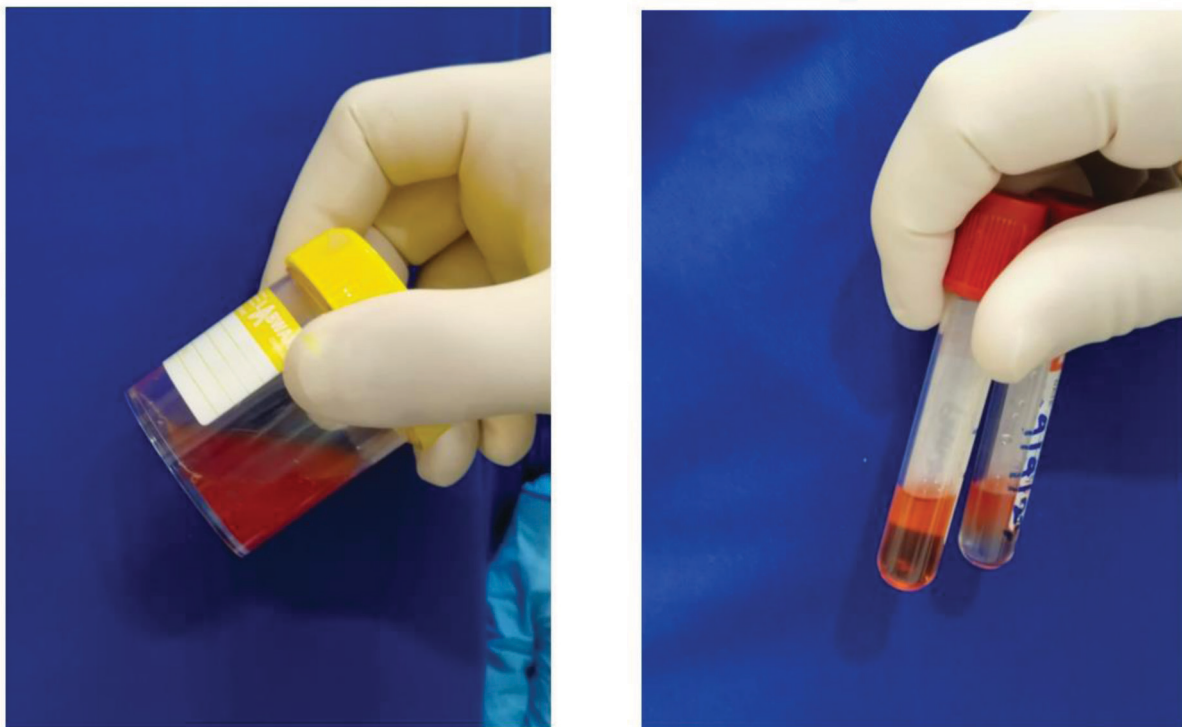


Figure 3 Macroscopic View of Lumbar Puncture

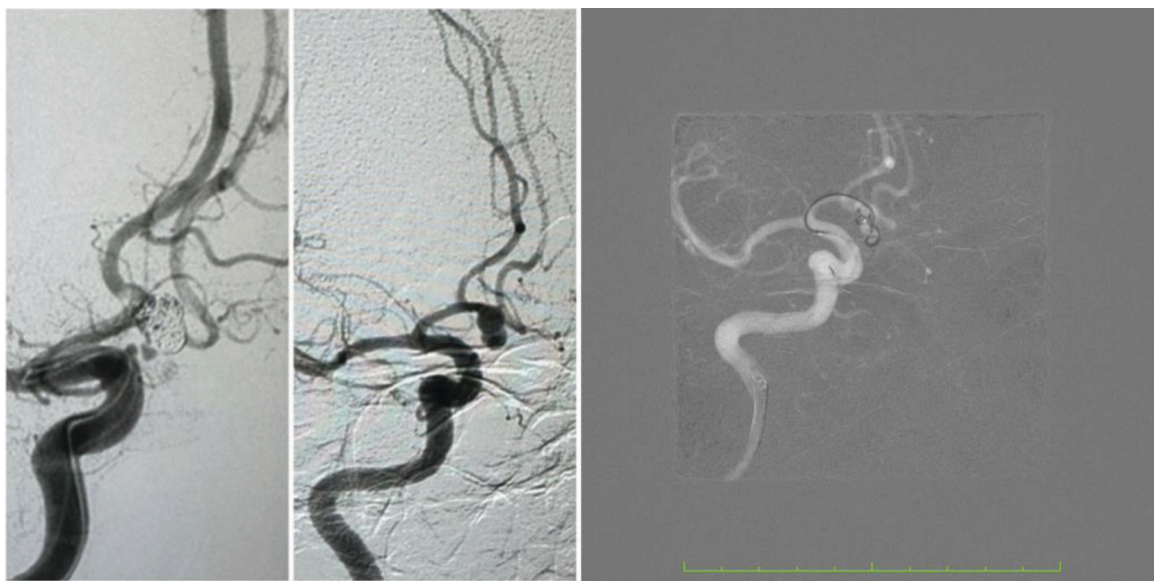

Figure 4 DSA post coiling (06/04/2023)

daily activities and sleep, and was no longer relieved with over-the-counter nonsteroidal anti-inflammatory drugs (NSAIDs). The patient denied any trauma, fever, neck stiffness, nausea or vomiting. She had no significant past medical or family history. She denied taking illicit drugs, smoking or drinking alcohol.

Motor strength and sensory exam were normal for both upper and lower limbs, and no cranial nerve or cerebellar deficits noted. There was no nuchal rigidity.

A cranial CT scan on admission showed no intracranial aneurysms or subarachnoid hemorrhage (SAH).

During the course of the hospital stay, the patient received tricyclic antidepressant, NSAID, muscle relaxants and benzodiazepines. However, her headache worsened, as observed on the pain scale. She also developed nuchal rigidity and light-headedness. Because of her deteriorating condition, the patient was taken for cranial magnetic resonance imaging and magnetic resonance angiography (MRI-MRA).

The MRI/MRA showed mild lateral bilateral ventriculomegaly with hyperintense debris and mild ependymal-leptomeningeal, as well as an arachnoid cyst in the left medial fossa ($\pm 1.8 \times 3.1 \times 1.8$ cm). A suspected saccular aneurysm was seen at the base of A2 ($\pm 4 \times 5 \times 4$ mm) with its dome facing anteriorly.

A LP was then performed, which showed xanthochromic fluid, 730/uL cells, positive Nonne Pandy test, 43 mg/dL glucose, 137 mg/dL protein and 107 mmol/L chloride.

A CT angiography (CTA) was done which showed mild subarachnoid hemorrhage in the chiasmatic cistern and posterior gray column of left lateral ventricle suspected coming from wide neck aneurysm in the segment border of A1-A2 right anterior cerebral artery with two small lumps facing the inferior wall of the aneurysm.

Digital subtraction angiography (DSA) showed a wide neck right anterior cerebral artery aneurysm and coiling of the aneurysm was performed. The headache receded several days after coiling and there were no further episodes of SAH.

DISCUSSION

Presentation of SAH

SAH is classically present with a characteristic headache that is sudden and severe, with the pain intensity peaking within seconds to minutes. It is often described by patients as the worst headache of their life, and is dubbed a “thunderclap” headache. Other associated symptoms are exertional onset, syncope, vomiting, neck pain and seizures. Focal neurological deficits, nuchal rigidity, loss of consciousness and retinal hemorrhage may also be present.[9,10]

Despite a clear classical description of its presentation, the rate of missed or delayed diagnosis of SAH has been reported to range from 12% to 53%.[9,13] In reality, the presentation of SAH patients is not often textbook; 40% to 60% of patients with aneurysmal SAH will present being neurologically intact,[14] and not all SAH patients

present with severe headache.[13] Because of this, further diagnostic testing is necessary, with non-contrast CT scan as the initial test of choice.[12,14] Nonetheless, as headache is a common complaint in the emergency department (ED), it may be difficult to decide which patients should be subject to further testing.[2,4]

For this reason, Perry, et al. published the Ottawa SAH Rule in 2013 to standardize which patients require further diagnostic testing, allowing physicians to easily make more informed decisions. Despite having a specificity of 15.3% – meaning that most patients investigated might not have SAH – the Ottawa SAH Rule has a sensitivity of 100%, allowing virtually all SAH patients to be properly diagnosed. All patients that are eligible according to the criteria and has at least one high-risk variable should receive a non-contrast head CT scan.[15]

Based on the Ottawa SAH rule, patients which are considered eligible are all alert patients older than 15 years with new severe non-traumatic headache reaching the maximum intensity within 1 hour, without new neurological deficits, previous aneurysms, SAH, brain tumors, or history of recurrent headaches (≥ 3 episodes over the course of ≥ 6 months). High-risk variables include: age ≥ 40 years old, neck pain or stiffness, witnessed loss of consciousness, onset during exertion, thunderclap headache (instantly peaking pain and limited neck flexion on examination).[15]

Our patient's presentation is not typical, instead of an acute thunderclap headache, she presented with a subacute progressively worsening headache. She also did not present with neck stiffness, nuchal rigidity or any other neurologic deficits. When a presentation is atypical such as this, there is no decision rule or guideline to recommend a certain approach, therefore the physician should use their best judgment to decide which testing is more appropriate – or if it is necessary. Although, most of the time, when a test is deemed necessary, a non-contrast CT scan is the preferred first test.

Computed Tomography

A non-contrast CT scan is the first diagnostic test that should be performed in all patients who are suspected to have SAH.[10,12,14] The CT scan has been widely tested, and more recent studies with modern CT scans have shown sensitivity as

high as 100%.[16,17] As such, some authors have suggested the CT-only approach for diagnosing SAH.[8,18,19]

However, the high sensitivity of a CT scan is very time-dependent and diminishes with time.[14,16] After the initial 6 hours, a CT scan's sensitivity drops to 85.7%,[10] increasing the utility of performing a LP after a negative CT. Our patient presented well over 6 hours of headache onset, which could have caused the SAH to be missed by CT. A study by Perry, et al. shows that for diagnosing SAH, physicians are only willing to adopt a clinical diagnostic decision rule that has 99%-100% sensitivity,[20] which might be justified due to its high burden of mortality and morbidity.[1,21,22] Even with current advancements in modern CT scans, it still has limitations and can be used as the sole diagnostic tool only in neurologically intact patients presenting within 6 hours of headache onset.[7,12,14,16]

Lumbar Puncture

LP has traditionally been used as a secondary test to remove any doubts of a negative CT scan.[23] Patients that have a negative CT scan (38.3%) may have a positive LP indicative of SAH (shown by increased RBC or presence of xanthochromia).[24] Conversely, it is estimated that virtually all patients with negative LP following a negative CT scan does not have a SAH.[25]

Despite that, LP is not a perfect test. It is prone to error due to traumatic tap being a considerable factor for false positives,[9,26] and it is also associated with certain risks, from the common low back pain and postdural puncture headache, to epidural nerve injury, iatrogenic infections, epidural hematoma and brainstem herniation. Moreover, it is an invasive test that is anxiety provoking and painful to most patients. Therefore, it is understandable that physicians who believe in the high accuracy of modern CT scans to forgo LP in their patients, fearing it would do more harm than good.[8,9]

Traumatic taps are estimated to happen in about one in six LPs. This is a significant amount and therefore requires strategies to correctly rule out or diagnose SAH while minimizing false positive results. [9] It has been suggested that spectrophotometry has better performance over visual inspection because it can differentiate xanthochromia from the oxyhemoglobin of traumatic tap with the bilirubin

of SAH.[10,27] While spectrophotometry has superior sensitivity over visual inspection (87% [95% CI = 71%-96%] and 83% [95% CI = 59%-96%], respectively), it is also more prone to false positives. Interestingly, when combined with red blood cell (RBC) count, visual inspection for the presence of xanthochromia makes for 100% sensitivity to exclude SAH, higher than both spectrophotometry alone and visual inspection alone.[26] Perry, et al. determined the most reasonable cut-off for RBC was the presence of fewer than $2000 \times 10^6/L$ red blood cells in addition to no xanthochromia in the final tube, which excluded the diagnosis of aneurysmal SAH with a sensitivity of 100% and specificity of 91.2%.[9,10,26] Currently, most institutions, as with ours, still rely solely on visual inspection.[10] In the cerebrospinal fluid sample taken from our patient, we found visible xanthochromia on all tubes, but only 730 cells/ μL , which is equivalent to $730 \times 10^6/L$, below the cut-off of $2000 \times 10^6/L$, which could be caused by the combination of the subacute nature of presentation in our patient causing less RBCs to enter the cerebrospinal fluid, or the prolonged delay from onset allowing lysis of more RBCs.

There are different practice variations regarding the timing of LP. The United Kingdom guidelines require LP to be performed >12 hours from headache onset,[28] which is supported by the study from the UK National External Quality Assessment Scheme for Immunochemistry Working Group. The rationale for the 12 hours wait is to allow for the breakdown of RBC in vivo and allow xanthochromia to develop, thus increasing sensitivity.[29] This study, however, uses spectrophotometry and not visual inspection, which may not be widely available. More research needs to be done to have conclusive evidence for waiting 12 hours before performing LP, as the delay in diagnosis will also increase patient wait time in the ED and may delay treatment. Current guidelines do not recommend a specific timing for performing LP after a negative CT scan.[12,30] In our case, waiting would provide no benefit as she presented after three days of headache onset.

LP will have greater benefit when performed in certain circumstances, for example, when there is no attending radiologist or neuroradiologist to interpret the scan, the use of older generation CT scans, or patients with a low hematocrit level. These factors could cause false negative CT results; therefore,

performing an LP is highly encouraged.[12,16] LP will also have greater benefit when there is a very high suspicion of SAH with a negative CT, specifically when there is a pre-test probability of >20% before the CT scan, as determined by Carpenter, et al., although patients with such a high probability would more likely than not have a positive CT scan. Also, there are currently no studies showing pre-CT findings or criteria (from patient history or physical examination) that would significantly increase the pre-test probability of SAH to 20% or higher.[9]

Other potential causes of false negative CT scans include: CT uses imaging slices >5 mm when imaging through the base of the brain, motion artifact in imaging results, or artifacts owing to metal in the surrounding bone or soft tissue.[9]

Computed Tomography Angiography

Computed tomography angiography (CTA) is an invaluable tool to visualize cerebrovascular anatomy. As a non-invasive test that could detect aneurysms, CTA has also been tested as a possible replacement for the use of LP in ruling out SAH, with a sensitivity of up to 98% and specificity of 100% for aneurysms in patients with SAH.[11] However, aneurysms detected may be unrelated to the headache.[10,12] This could lead to more tests being performed without bringing benefit to the patient, increase patient anxiety for ruptured SAH, and influence the patient's ability to obtain life insurance.[30] The patient can also be at risk for complications of CTA including nephrotoxicity, increased radiation exposure and allergic reaction.[31] On the other hand, one survey showed that 79.2% of patients favored the use of CTA over LP to exclude SAH.[32] Additionally, CTA can be helpful in certain conditions where performing a LP would be difficult or harmful, such as in an obese, agitated and/or coagulopathic patient.

A negative non-contrast head CT followed by a CTA showing no aneurysm has a post-test probability of SAH <1%.[10,11] While this percentage falls below most clinicians' test threshold (in which no further testing would be required),[10,20] an analysis estimated the sensitivity of CTA for ruptured aneurysms <3 mm at <61%,[12,33] and aneurysms <4 mm at 92%.[10,34] While a larger aneurysm size would increase the risk of hemorrhage, a study

found that 26% of SAH are caused by aneurysms <5 mm.[35] This raises the question of whether LP should still be performed after both a negative non-contrast CT scan and CTA, but it is doubtful that LP would be beneficial in that scenario, as the probability of SAH is extremely low.[11]

Guidelines from AHA/ASA recommend the use of CTA after ruling in SAH with a positive CT scan or LP to aid in choosing the treatment modality for each patient. DSA, however, is still the gold-standard for evaluation of cerebrovascular anatomy.[12]

Magnetic Resonance Imaging/Magnetic Resonance Angiography

Magnetic resonance imaging and angiography (MRI/MRA) has a pooled sensitivity and specificity of 95% and 89%, respectively for detection of cerebral aneurysms.[36] However, it has limited sensitivity in more acutely presenting patients and is of more use in subacute (three days after headache onset) or chronic SAH,[10,31] which is the case in our patient. Additionally, MRI/MRA is costly. A cost-effectiveness study for SAH diagnostic strategies comparing CT followed by LP (CT/LP), CT followed by CTA (CT/LPA) and CT followed by MRA (CT/MRA) showed that CT/MRA was the costliest while inferior to CT/LP in effectiveness. The study also suggests the non-inferiority of CT/LP compared to other approaches

and advises against the change of current guidelines supporting the CT/LP strategy.[37]

CONCLUSION

LP is still relevant in the diagnostic approach of SAH, despite technological advances in CT/CTA and MRI/MRA imaging. Following guidelines from AHA/ASA, LP should be done after a negative CT on patients with acute onset severe headache presenting with a new neurological deficit, or presenting after 6 hours of headache onset.[12] ACEP also recommends shared decision-making for the use of CTA as an alternative for LP after a negative CT (level C recommendation),[30] but more high-quality studies are needed to confirm the superiority of one over the other. In our patient, the use of LP and CTA both played a role in diagnosis of SAH, but perhaps standardized thresholds, and also testing (with use of spectrophotometry over visual inspection) can further maximize the utility of LP. CTA can be used instead in certain patients when performing LP would be difficult or harmful, such as obese, agitated and/or coagulopathic patients. MRI/MRA has limited sensitivity in patients presenting <48 hours and therefore might be less useful in most scenarios,[10,31,36] but in our case has been useful in diagnosing SAH.

REFERENCES

1. Etmnan N, Chang HS, Hackenberg K, De Rooij NK, Vergouwen MDI, Rinkel GJE, et al. Worldwide incidence of aneurysmal subarachnoid hemorrhage according to region, time period, blood pressure, and smoking prevalence in the population: A systematic review and meta-analysis. *JAMA Neurol*. 2019 May 1;76[5]:588.
2. Landtblom AM, Fridriksson S, Boivie J, Hillman J, Johansson G, Johansson I. Sudden onset headache: A prospective study of features, incidence and causes. *Cephalalgia*. 2002 Jun;22[5]:354–60.
3. Nieuwkamp DJ, Setz LE, Algra A, Linn FH, De Rooij NK, Rinkel GJ. Changes in case fatality of aneurysmal subarachnoid haemorrhage over time, according to age, sex, and region: a meta-analysis. *The Lancet Neurology*. 2009 Jul;8[7]:635–42.
4. Carstairs SD, Tanen DA, Duncan TD, Nordling OB, Wanebo JE, Paluska TR, et al. Computed tomographic angiography for the evaluation of aneurysmal subarachnoid hemorrhage. *Academic Emergency Medicine*. 2006 May;13[5]:486–92.
5. Rehman S, Phan HT, Reeves MJ, Thrift AG, Cadilhac DA, Sturm J, et al. Case-fatality and functional outcome after subarachnoid hemorrhage (SAH) in INternational STRoke oUtcomes sTudy (INSTRUCT). *Journal of Stroke and Cerebrovascular Diseases*. 2022 Jan;31[1]:106201.
6. Perry JJ, Stiell IG, Sivilotti MLA, Bullard MJ, Emond M, Symington C, et al. Sensitivity of computed tomography performed within six hours of onset of headache for diagnosis of subarachnoid haemorrhage: prospective cohort study. *BMJ*. 2011 Jul 18;343[jul18 1]:d4277–d4277.
7. Backes D, Rinkel GJE, Kemperman H, Linn FHH, Vergouwen MDI. Time-dependent test characteristics of head computed tomography in patients suspected of nontraumatic subarachnoid hemorrhage. *Stroke*. 2012 Aug;43[8]:2115–9.
8. Gottlieb M, Morgenstern J. Lumbar puncture should not be routinely performed for subarachnoid hemorrhage after a negative head CT. *Annals of Emergency Medicine*. 2021 Jun;77[6]:643–5.
9. Carpenter CR, Hussain AM, Ward MJ, Zipfel GJ, Fowler S, Pines JM, et al. Spontaneous subarachnoid hemorrhage: A systematic review and meta-analysis describing the diagnostic accuracy of history, physical examination, imaging, and lumbar puncture with an exploration of test thresholds. In: Zehrabchi S, editor. *Acad Emerg Med*. 2016 Sep;23[9]:963–1003.
10. Marcolini E, Hine J. Approach to the diagnosis and management of subarachnoid hemorrhage. *WestJEM*. 2019 Feb 28;20[2]:203–11.
11. McCormack RF, Hutson A. Can computed tomography angiography of the brain replace lumbar puncture in the evaluation of acute-onset headache after a negative non-contrast cranial computed tomography scan? *Academic Emergency Medicine*. 2010 Apr;17[4]:444–51.
12. Hoh BL, Ko NU, Amin-Hanjani S, Hsiang-Yi Chou S, Cruz-Flores S, Dangayach NS, et al. 2023 guideline for the management of patients with aneurysmal subarachnoid hemorrhage: A guideline from the American Heart Association/American Stroke Association. *Stroke* [Internet]. 2023 Jul [cited 2023 Sep 17];54[7]. Available from: <https://www.ahajournals.org/doi/10.1161/STR.0000000000000436>
13. Vermeulen MJ, Schull MJ. Missed diagnosis of subarachnoid hemorrhage in the emergency department. *Stroke*. 2007 Apr;38[4]:1216–21.
14. Edlow JA, Fisher J. Diagnosis of subarachnoid hemorrhage: Time to change the guidelines? *Stroke*. 2012 Aug;43[8]:2031–2.
15. Perry JJ, Stiell IG, Sivilotti MLA, Bullard MJ, Hohl CM, Sutherland J, et al. Clinical decision rules to rule out subarachnoid hemorrhage for acute headache. *JAMA*. 2013 Sep 25;310[12]:1248.
16. Dubosh NM, Bellolio MF, Rabinstein AA, Edlow JA. Sensitivity of early brain computed tomography to exclude aneurysmal subarachnoid hemorrhage: A systematic review and meta-analysis. *Stroke*. 2016 Mar;47[3]:750–5.
17. Cortnum S, Sørensen P, Jørgensen J. Determining the sensitivity of computed tomography scanning in early detection of subarachnoid hemorrhage. *Neurosurgery*. 2010 May;66[5]:900–2; discussion 903.
18. Long B, Koyfman A. Controversies in the diagnosis of subarachnoid hemorrhage. *The Journal of Emergency Medicine*. 2016 Jun;50[6]:839–47.
19. Claveau D, Dankoff J. Is lumbar puncture still needed in suspected subarachnoid hemorrhage after a negative head computed tomographic scan? *CJEM*. 2014 May;16[03]:226–8.
20. Perry JJ, Eagles D, Clement CM, Brehaut J, Kelly AM, Mason S, et al. An international study of emergency physicians' practice for acute headache management and the need for a clinical decision rule. *CJEM*. 2009 Nov;11[06]:516–22.
21. Hop JW, Rinkel GJE, Algra A, Van Gijn J. Case-fatality rates and functional outcome after subarachnoid hemorrhage: A systematic review. *Stroke*. 1997 Mar;28[3]:660–4.
22. English SW. Long-term outcome and economic burden of aneurysmal subarachnoid hemorrhage: Are we only seeing the tip of the iceberg? *Neurocrit Care*. 2020 Aug;33[1]:37–8.
23. Gill HS, Marcolini EG, Barber D, Wira CR. The utility of lumbar puncture after a negative head CT in the emergency department evaluation of subarachnoid hemorrhage. *Yale J Biol Med*. 2018 Mar;91[1]:3–11.
24. Kameda-Smith M, Aref M, Jung Y, Ghayur H, Farrokhyar F. Determining the Diagnostic utility of lumbar punctures in computed tomography negative suspected subarachnoid hemorrhage: A systematic review and meta-analysis. *World Neurosurgery*. 2021 Apr;148:e27–34.
25. Perry JJ, Spacek A, Forbes M, Wells GA, Mortensen M, Symington C, et al. Is the combination of negative computed tomography result and negative lumbar puncture result sufficient to rule out subarachnoid hemorrhage? *Annals of Emergency Medicine*. 2008 Jun;51[6]:707–13.
26. Perry JJ, Alyahya B, Sivilotti MLA, Bullard MJ, Emond M, Sutherland J, et al. Differentiation between traumatic tap and aneurysmal subarachnoid hemorrhage: prospective cohort study. *BMJ*. 2015 Feb 18;350[feb18 8]:h568–h568.
27. Bakr A, Silva D, Cramb R, Flint G, Foroughi M. Outcomes of CSF spectrophotometry in cases of suspected subarachnoid haemorrhage with negative CT: two years retrospective review in a Birmingham hospital. *British Journal of Neurosurgery*. 2017 Mar 4;31[2]:223–6.
28. Subarachnoid haemorrhage caused by a ruptured aneurysm: diagnosis and management. London: NICE; 2022. (NICE guideline).
29. UK National External Quality Assessment Scheme for Immunochemistry Working Group. National guidelines for

- analysis of cerebrospinal fluid for bilirubin in suspected subarachnoid haemorrhage. *Ann Clin Biochem*. 2003 Sep 1;40[5]:481–8.
30. Godwin SA, Cherkas DS, Panagos PD, Shih RD, Byyny R, Wolf SJ, et al. Clinical policy: Critical issues in the evaluation and management of adult patients presenting to the emergency department with acute headache. *Annals of Emergency Medicine*. 2019 Oct;74[4]:e41–74.
31. Long B, Koyfman A, Runyon MS. Subarachnoid hemorrhage. *Emergency Medicine Clinics of North America*. 2017 Nov;35[4]:803–24.
32. Youssef NA, Gordon AJ, Moon TH, Patel BD, Shah SJ, Casey EM, et al. Emergency Department patient knowledge, opinions, and risk tolerance regarding computed tomography scan radiation. *The Journal of Emergency Medicine*. 2014 Feb;46[2]:208–14.
33. Westerlaan HE, Van Dijk JMC, Jansen-van Der Weide MC, De Groot JC, Groen RJM, Mooij JJA, et al. Intracranial aneurysms in patients with subarachnoid hemorrhage: CT angiography as a primary examination tool for diagnosis—systematic review and meta-analysis. *Radiology*. 2011 Jan;258[1]:134–45.
34. Van Der Wee N, Rinkel GJ, Hasan D, Van Gijn J. Detection of subarachnoid haemorrhage on early CT: is lumbar puncture still needed after a negative scan? *Journal of Neurology, Neurosurgery & Psychiatry*. 1995 Mar 1;58[3]:357–9.
35. Ohashi Y, Horikoshi T, Sugita M, Yagishita T, Nukui H. Size of cerebral aneurysms and related factors in patients with subarachnoid hemorrhage. *Surgical Neurology*. 2004 Mar;61[3]:239–45.
36. Sailer AMH, Wagemans BAJM, Nelemans PJ, De Graaf R, Van Zwam WH. Diagnosing intracranial aneurysms with MR angiography: Systematic review and meta-analysis. *Stroke*. 2014 Jan;45[1]:119–26.
37. Ward MJ, Bonomo JB, Adeoye O, Raja AS, Pines JM. Cost-effectiveness of diagnostic strategies for evaluation of suspected subarachnoid hemorrhage in the emergency department: Cost-effectiveness of diagnosing SAH. *Academic Emergency Medicine*. 2012 Oct;19[10]:1134–44.



Open Access This article is licensed under a Creative Commons Attribution-NonCommercial-ShareAlike 4.0 International License, which permits use, share — copy and redistribute the material in any medium or format, adapt — remix, transform, and build upon the material, as long as you give appropriate credit, provide a link to the license, and indicate if changes were made. You may do so in any reasonable manner, but not in any way that suggests the licensor endorses you or your use. You may not use the material for commercial purposes. If you remix, transform, or build upon the material, you must distribute your contributions under the same license as the original. You may not apply legal terms or technological measures that legally restrict others from doing anything the license permits. The images or other third party material in this article are included in the article's Creative Commons license, unless indicated otherwise in a credit line to the material. If material is not included in the article's Creative Commons license and your intended use is not permitted by statutory regulation or exceeds the permitted use, you will need to obtain permission directly from the copyright holder. To view a copy of this license, visit <https://creativecommons.org/licenses/by-nc-sa/4.0/>.