

# Ankle Height Preservation with the Hind Foot Nail and Iliac Crest Bone Blocks in Patients with Sequelae of Partial or Complete Talus Bone Loss

Gunasekeran C<sup>1</sup>, MS Orth, Bhowmick K<sup>1</sup>, MS Orth, Ramasamy B<sup>2</sup>, FRACS, Jepegnanam TS<sup>1</sup>, MS Orth

<sup>1</sup>Department of Orthopaedics, Christian Medical College and Hospital Vellore, Vellore, India

<sup>2</sup>Department of Orthopaedics, Royal Adelaide Hospital, Adelaide, Australia



This is an open-access article distributed under the terms of the Creative Commons Attribution License, which permits unrestricted use, distribution, and reproduction in any medium, provided the original work is properly cited

Date of submission: 22nd November 2020

Date of acceptance: 06th August 2021

## ABSTRACT

**Introduction:** The management of talus bone loss in trauma is difficult and unsatisfactory. This study assessed whether the height of the ankle was preserved when entire or partial talar bone loss was managed with hind foot intramedullary nail augmented with autogenous rectangular or trapezoidal cortico-cancellous bone blocks from the iliac crest in the presence of active or latent infection.

**Materials and methods:** Four patients were included in the study from January 2011 to December 2017. In the first stage, all four patients underwent debridement of the ankle, total or partial excision of the talus, and antibiotic-loaded bone cement spacer (ALBC) placement in the ankle joint. The second stage of the arthrodesis procedure was initiated six to eight weeks after the primary procedure, where these patients underwent arthrodesis with hindfoot nail and bone blocks from the iliac crest.

**Results:** All patients were followed-up for an average of 17.6 months (range 12.0 – 32.0 months). The arthrodesis site had united in all these four patients. The AOFAS scores were satisfactory in all patients. One patient underwent nail removal after the arthrodesis site had united.

**Conclusions:** The hind foot nail with iliac crest bone block maintains the ankle height and ensures successful arthrodesis. In patients with partial/ complete bone loss with suspicion or confirmation of infection, staging the arthrodesis procedure minimises the chance of complications.

### Keywords:

*hind foot arthrodesis, staged management, talar bone loss, infection*

## INTRODUCTION

The management of Type 3 and 4 talus fracture-dislocations

with extrusion is difficult and unsatisfactory. These injuries are usually violent and are associated with severe soft tissue damage. The resultant combination of gross contamination, soft tissue damage, and attempts at restoring the normal ankle anatomy either by replacing the extruded talus in its original position or by fixation gives a poor outcome<sup>1-3</sup>. Treatment for these injuries is either retention/ fixation of the talus, preserving the ankle anatomy, or excision of the talus with arthrodesis of the tibio-calcaneal joint<sup>2,4-8</sup>. These contrasting methods of management of talus bone loss have found acceptance in orthopaedic practices worldwide<sup>2,7,8</sup>. Preservation of the talus maintains the ankle architecture and height but is complicated by high rates of infection, late-stage osteonecrosis, and multiple procedures<sup>3,8</sup>.

When there is a complete loss of the talus or restoring the original anatomy is impossible, tibio-calcaneal arthrodesis becomes the keystone of treatment, which can be achieved by internal as well as external fixation<sup>9-11</sup>. Screws, plates, and intramedullary nails are used for internal fixation and compression<sup>12-15</sup>. External fixation devices used for tibio-calcaneal arthrodesis are uniplanar or circumferential compression frames<sup>10,16,17</sup>. Internal fixation is found to be superior to external fixation as they are biomechanically stable and have higher union rates<sup>11,18</sup>. Union at the arthrodesis site is augmented by autogenous bone graft and allografts<sup>19,20</sup>. Metallic or ceramic prosthetic replacement of the entire talus has been described with fair results<sup>21-23</sup>.

This aim of this study is to assess the outcome of management of the sequelae of talus bone loss (complete or partial) with hind foot nail device and autogenous rectangular/trapezoidal bone graft blocks from the iliac crest to reconstruct the height of the ankle joint in the presence of confirmed/suspicion of infection.

## MATERIALS AND METHODS

This retrospective study was approved by our Institutional review board. Four non-consecutive patients were identified from the hospital database of a Level 1 trauma referral centre from the year January 2011 to December 2017 and included in this study. Informed consent was taken from all these patients. The inclusion criteria for this study were patients with partial/complete talectomy and its sequelae of infection, bone loss, and soft tissue loss requiring flap coverage. The exclusion criteria were patients with prior hind foot arthrodesis or who were unwilling to participate in this study. All were male with an average age of 28.2 years, and were involved in fall from height with a compound injury of the ankle. None of the patients had any co-morbidity.

Patient 1 was treated by us from the initial time of the injury, wherein, the entire extruded part of the talus was excised leaving a remnant of the talus with soft tissue attachment in the ankle joint. In Patient 2, the talus was completely excised and ALBC placed in the ankle joint before presenting to us. In patients 3 and 4, ORIF of the talus with soft tissue cover was performed at different hospitals. Radiographs of these two patients indicated a failure of fixation, de-vascularisation with features of chronic infection. All the patients except Patient 1 had undergone an average of two surgeries before undergoing staged arthrodesis at our institution. Pre-operative markers of infection were performed for all these patients.

In all the four patients, we staged the arthrodesis procedure. In the first stage, the ankle joint was debrided and the entire talus or the infected and de-vascularised part of the talus was excised. In Patient 2, the talus was already excised and filled with ALBC. In this patient, we debrided the ankle joint and re-applied the ALBC containing 2g of Vancomycin and Meropenem, respectively. In patients 1, 3 and 4, debridement of the ankle joint was performed and the de-vascularised, infected part of the talus was excised till bleeding healthy bone was achieved. The ankle joint with the remnant talus was filled with ALBC as mentioned above. The second stage of the arthrodesis procedure was initiated six to eight weeks after the primary procedure in which these patients underwent arthrodesis with hind foot nail and bone blocks from the iliac crest. In the post-operative period, the clinical and radiological follow-up of these patients was done from six weeks onwards of the arthrodesis procedure.

Bony union was defined radiologically as at least three cortices union in AP and lateral views during the follow-up period which was assessed by two of the authors at any time<sup>24</sup>. A functional assessment of the treatment was done by the AOFAS scores (maximum score of 86)<sup>25</sup>. The complications of infection, wound necrosis and, implant failure were noted.

The ankle joint was exposed by the anterolateral approach<sup>26</sup>. The skin incision was made 5cm proximal to the ankle joint and continued 5cm distally in line with the base of the 4th metatarsal. Previous posteromedial or posterolateral skin incisions over the area were ignored. If the previous skin incision was present on the anterior ankle region, it was included in the universal incision. Sinuses over the ankle region were curetted and debrided. The extensor tendons and neurovascular structures of the anterior compartment of the ankle were retracted medially and the joint capsule was incised in line with the skin incision, exposing the distal tibia, ankle joint up to the tibiofibular joint and the talonavicular joint. The ankle joint was debrided and depending on the osteonecrosis or osteomyelitis of the talus; it was partially or completely excised in cases with infection. Patient 2 had already undergone complete talectomy secondary to multiple previous surgeries performed at a different hospital, whereas, Patients 1, 3 and 4 underwent debridement of the talus till bleeding bone was achieved. The ankle joint was stabilised with joint spanning external fixator or below knee POP splints in all four patients. The void of the talar dome area was filled with Gentamycin cement [DePuy CMW™, USA] mixed with 2g each of Vancomycin and Meropenem each, respectively. This antibiotic-loaded bone cement (ALBC) was applied to control the infection and maintaining the space and architecture of the talar dome, to be filled with bone graft in the second stage of the surgery<sup>27</sup>. The wound was closed in layers with a suction drain. In all four patients, the debrided tissues and bone were sent for antimicrobial cultures.

In the post-operative period, patients were administered with culture appropriate intravenous or oral antibiotics for six weeks. These patients were allowed to walk on crutches without applying weight on the affected limb.

In the second stage, the ankle joint was exposed through the same incision as previously described and the cement spacer was removed. The tibial plafond and the talar remnant or calcaneum were curetted till bleeding cancellous bone was visualised. The gap between the distal tibia and the talus remnant or calcaneum (such as in Patient 2 where the talus was completely excised) was measured. The gap was 2.5cm, 3.5cm, 3cm, and 3.2cm in Patients 1, 2, 3, and 4, respectively. Two rectangular or trapezoidal bone blocks were harvested from each of the patient's iliac crest with a standard width of 3cm and length according to the gap as measured. The width of these bone blocks was kept at a standardised 3cm to accommodate the width of the tibial plafond. These bone blocks were packed in the void of the tibiotalar joint lengthwise, maintaining the height of the ankle joint. Tibio-calcaneal arthrodesis was now performed using the hind foot nail, maintaining the bone blocks in position, so that one of the screws into the nail would pass through the bone blocks, holding them in position. The ankle was held in 0° - 5° of plantar flexion and 5° - 10° of valgus

Table I: Treatment details, functional score and sequelae

Serial Number	1st Stage Surgery	Infection	Culture	Antibiotics	Talar Lesion	2nd Stage Surgery (Arthrodesis)	BG	Complications	Follow-up months	AOFAS Score (Max= 86)	Sequelae
1	Debridement, Partial Excision Talus, Antibiotic Spacer, And Joint Spanning External Fixator	NIL	NIL	Cap cephalixin six weeks	Partial talus excision	Trigen retrograde femur nail	Iliac crest	NIL	24	76	NIL
2	Talectomy, Antibiotic Spacer Done At Different Hospital	NIL	NIL	Cap cephalixin six weeks	Complete talectomy	Trigen hind foot nail	Iliac crest	NIL	30	73	NIL
3	Partial Talectomy, Antibiotic Spacer	Yes	GNB (p. aeruginosa)	Iv piperacillin and tazobactam six weeks	Partial talus excision	Trigen hindfoot nail	Iliac crest	Wound infection (culture - p. aeruginosa)	24	66	1. Ankle debridement six months after arthrodesis 2. Hind foot nail removal 10 months after arthrodesis
4	Partial Talectomy Antibiotic Spacer, Joint Spanning External Fixator	Yes	Coagulase negative staphylococcus	Cap cloxacillin six weeks	Partial talus excision	Trigen retrograde femur nail	Iliac crest	NIL	12	70	NIL

Table II: Comparison of AOFAS scores with other articles on the management of talus bone loss

Article	AOFAS score
Tibio- calcaneal arthrodesis with hind foot nail in severe loss of talus (Klos et al <sup>15</sup> )	71.5
Retrograde nail for tibiotalocalcaneal arthrodesis in severe bone loss of distal tibia and talus (Ochman et al <sup>16</sup> )	58.3
Ankle arthrodesis using Iliarov method (Fragomen et al <sup>10</sup> )	71
Management of talus non-union with avascular necrosis with hind foot nail and bone grafting (Abd-Ella et al <sup>15</sup> )	76.6
Our paper	71.25

for final fixation in all the patients. In Patients 2 and 3, we used hind foot nails [TriGen, Smith and Nephew, USA], whereas, in Patients 1 and 4, we used retrograde femur nails [TriGen meta-nail, Smith and Nephew, USA] for fixation as shown in Table I.

The patients were given a below-knee cast after suture removal for a period of 6 weeks after which they were mobilised with weight-bearing as tolerated to full weight bearing at 12 weeks.

## RESULTS

The average follow-up period was 22.5 months (range: 12.0 – 30.0 months). The arthrodesis site had united in all these patients. No limb length discrepancy was detected except in Patient 3 where the operated limb was short by 3mm. Culture positive bacterial growth was present in Patients 3 and 4, who grew gram-negative bacteria (*Pseudomonas aeruginosa*) and coagulase-negative Staphylococci, respectively. Both these patients were administered culture appropriate antibiotics for a period of six weeks after the first stage of the reconstruction.

Bony union was observed in all four patients between the tibial plafond and the talar remnant and calcaneum (Fig. 1 to 5).

The average AOFAS score was 71.25 (range: 70.0 – 76.0) which was acceptable in all the patients as shown in Table I. There was no limitation of knee movement in these four patients.

Patient 3 developed a wound infection of the ankle joint six months after the arthrodesis procedure. This patient underwent debridement of the ankle joint and was given culture appropriate antibiotics. He again developed an infection of the ankle joint 10 months after the arthrodesis procedure. The radiograph of the ankle indicated a bony union at the arthrodesis site. Clinical resolution of all the symptoms was achieved at this time after nail removal. He was advised full weight-bearing after removal of the implant (Fig. 4).

## DISCUSSION

Salvage of post-traumatic or infective talus injuries with partial or complete loss is managed with debridement and tibio-calcaneal or tibiototalcalcaneal arthrodesis<sup>10,17</sup>. Kolker *et al* have described the staged management of three cases of talus osteomyelitis secondary to trauma using an external fixator and iliac crest bone grafting<sup>28</sup>. Jaffe *et al* have described four clinical scenarios of talar bone loss and osteomyelitis, all of whom were treated with four different techniques<sup>29</sup>. Klos *et al* have described the management of

nine cases of talar bone loss with the hindfoot nail in a single stage<sup>15</sup>. Ochman *et al* have described the management of three patients with severe bone loss of the talus and the distal tibia with initial soft tissue cover and staged tibio-calcaneal arthrodesis with hind foot nails with an emphasis on the role of the intramedullary implant in the salvage of these limbs. Restoration of ankle height was not achieved in these patients as all of them underwent tibio-calcaneal arthrodesis through extramedullary and intramedullary implants with the remnant talus, if present, used as a bone graft<sup>30</sup>.

Preservation of ankle height in patients undergoing tibiototalcalcaneal (TTC) arthrodesis has been obtained by the use of the Ilizarov technique, ceramic/ metallic implants, femoral head allografts, 3D titanium cages, and 3D printed talus arthroplasty<sup>10,20,22,23,31,32,33</sup>. The advantages of maintaining the ankle height are that it restores the limb length, provides adequate tension to the soft tissues, and preserves the musculotendinous function of the foot<sup>31</sup>. In this series, we used trapezoidal or rectangular bone blocks from the patient's iliac crest to maintain the height of the ankle joint. None of the patients had limb length discrepancy except Patient 3 who was short by 3mm. All the four patients had endured a minimum of two surgeries with three patients (Patients 2 and 3) undergoing reverse sural artery (RSA) flap for soft tissue coverage before presenting to us. Two of the patients (Patients 3 and 4) were found to have culture-positive growth after the first stage. We did not use the femoral head allografts to maintain the ankle height in these patients during the second stage of reconstruction to decrease the chance of residual infection. The 3D printed titanium cages and talus arthroplasty has an important role in the management of talus reconstruction and has shown to have good early outcomes<sup>21-23</sup>. These technological advances are not universally available, popular, and cause financial strain on the patient.

Rammelt *et al* has described the stages of post-traumatic reconstruction of talus non-union/malunion based on the presence of avascular necrosis (AVN) and infection<sup>34</sup>. Based on this classification, all four patients in this series fall under stage 5, where the authors have advised repeated debridement of the infected and necrotic bone resulting in complete or partial loss of the talus followed by fusion at a later stage. All the patients in our series except Patient 1 had multiple surgeries with ill-defined treatment history. We had maintained a high index of suspicion for infection even before initiating the first stage of debridement and ALBC spacer application. During the debridement, all of the necrotic and infected bone was removed resulting in partial remnant talus which showed good bleeding from the surface and still attached to the soft tissues. Hence, the arthrodesis was completed in a staged fashion.

The ankle joint was exposed by the anterolateral "universal" incision in all our patients. We did not use the transfibular

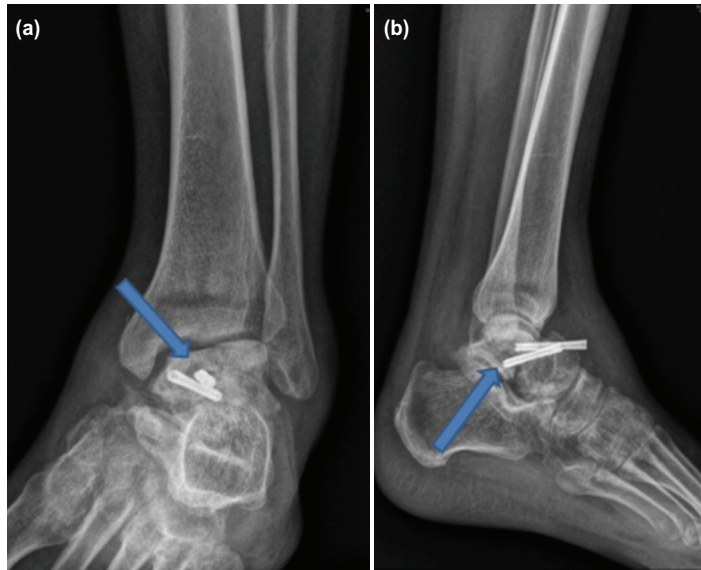


Fig. 1: (a, b) Pre-operative AP and lateral radiographs of Patient 4.

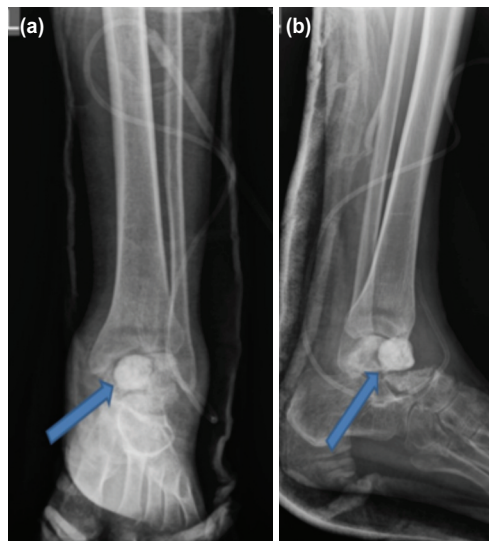

Fig. 2: (a, b) 1st stage debridement and ALBC application with partial loss of talus in patient.

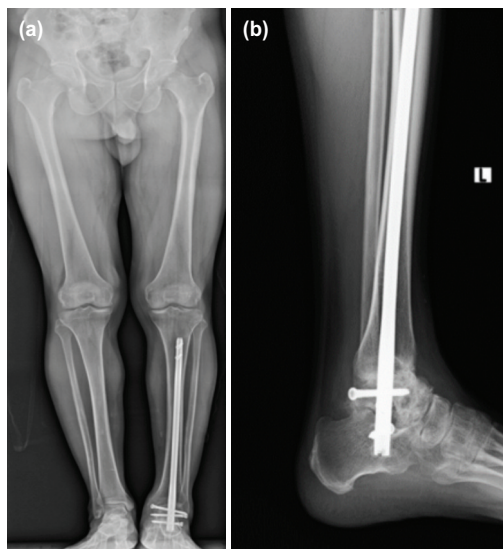


Fig.3: (a, b) AP and lateral radiographs of Patient 4 at follow-up of 12 months.

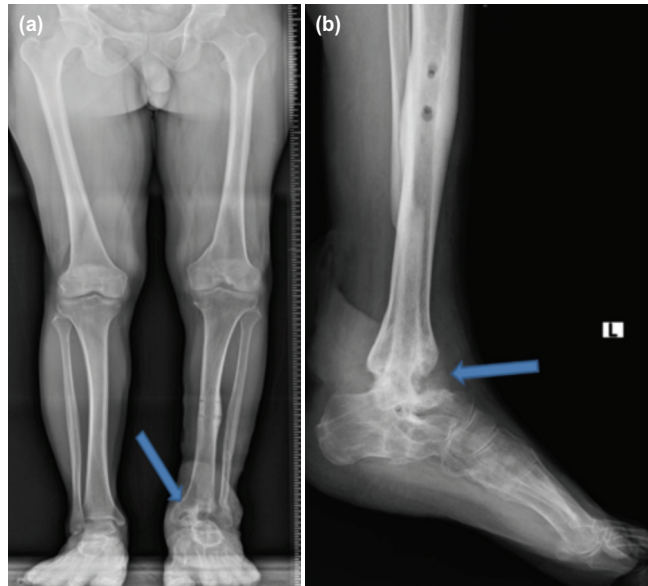


Fig. 4: (a, b) Patient 3 after nail removal with arthrodesis site union at 24 months of follow-up.

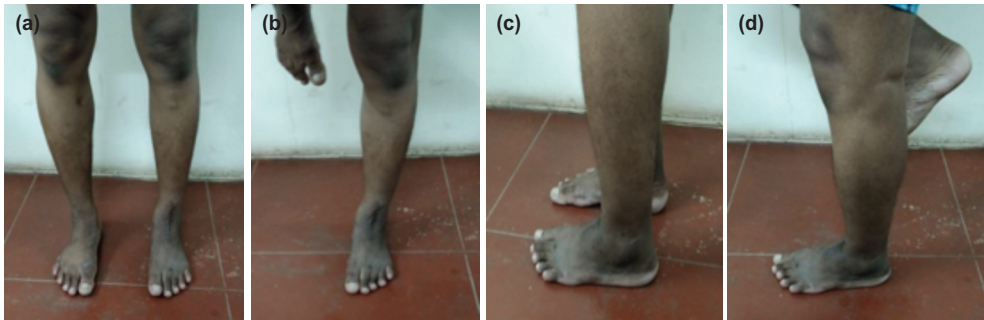

Fig. 5: (a, b, c, d) Clinical pictures of Patient 4 at 12 months of follow-up.

approach as described by Klos *et al* or the posterior approach described by Abd-Ella *et al* since we wanted to avoid damage to the ankle syndesmosis and extensive dissection of the posterior structure<sup>15,35</sup>. Damage to the syndesmotoc ligaments and the interosseous membrane increases the inversion and rotational stresses around the ankle joint resulting in deep muscular pain and weakness while walking<sup>36</sup>. Preservation of the fibula maintains the anatomy of the ankle joints and providing restraint to the peroneal tendons<sup>37</sup>.

All our patients were young males and involved in heavy manual work. We believe that maintaining the height of the ankle joint as well as avoiding injury to the syndesmotoc ligaments during exposure helped in decreasing the morbidity of the involved limb. All the patients have acceptable AOFAS scores comparable to the literature available on the management of this rare condition, despite an infected nail removal in Patient 3 as shown in Table II. In patients 1 and 4, we used the retrograde femur nail for fixation instead of the dedicated hind foot nail to keep the surgical costs down. We found that the retrograde femur nails are a good alternative to the hind foot nails.

Staging the arthrodesis procedure, use of ALBC to maintain the ankle architecture during the first stage of debridement, use of culture appropriate antibiotics, autogenous dome filling bone blocks to maintain the height of the ankle, and an intramedullary nail device is a safe way to approach this difficult problem. A review of English literature did not reveal many studies where the talar bone loss or its complications were managed in two stages, using the bone blocks to maintain the height of the ankle and the nail device, although, each of these strategies has been applied individually by various authors. Abd-Ella *et al* has described the management of talus bone loss with hind foot nail and strut graft from the iliac crest in a single stage<sup>35</sup>. Clowers *et al* has described trapezoidal bone blocks fashioned out of femoral head allografts in the management of severe bone loss from the hind foot<sup>38</sup>. We hope that this study adds to the literature on the management of talar bone loss.

Limitations of this study are its retrospective nature, lack of comparative data, and the small number of patients. However, despite our appreciation of the limitations of our investigation, we believe that the results of this study could be useful in adding to the literature for the management of

partial or complete talus bone loss secondary to the trauma associated with infection.

heeled strategy. The use of autogenous rectangular or trapezoidal iliac crest bone blocks prevents the loss of ankle height.

## CONCLUSION

In conclusion, staging the management of talus bone loss in patients with proven or even suspicion of infection is a well-

## CONFLICT OF INTEREST

The authors declare no potential conflict of interest.

## REFERENCES

1. Canale ST, Kelly FB Jr. Fractures of the neck of the talus. Long-term evaluation of seventy-one cases. *J Bone Joint Surg Am.* 1978; 60(2): 143-56.
2. Marsh JL, Saltzman CL, Iverson M, Shapiro DS. Major open injuries of the talus. *J Orthop Trauma.* 1995; 9(5): 371-6. doi: 10.1097/00005131-199505000-00002
3. Smith CS, Nork SE, Sangeorzan BJ. The extruded talus: results of reimplantation. *J Bone Joint Surg Am.* 2006; 88(11): 2418-24. doi: 10.2106/JBJS.E.00471
4. Palomo-Traver JM, Cruz-Renovell E, Granell-Beltran V, Monzonís-García J. Open total talus dislocation: case report and review of the literature. *J Orthop Trauma.* 1997; 11(1): 45-9. doi: 10.1097/00005131-199701000-00014
5. Hiraizumi Y, Hara T, Takahashi M, Mayehiyo S. Open total dislocation of the talus with extrusion (missing talus): report of two cases. *Foot Ankle.* 1992; 13(8): 473-7. doi: 10.1177/107110079201300808
6. Detenbeck LC, Kelly PJ. Total dislocation of the talus. *J Bone Joint Surg Am.* 1969; 51(2): 283-8.
7. Brewster NT, Maffulli N. Reimplantation of the totally extruded talus. *J Orthop Trauma.* 1997; 11(1): 42-5. doi: 10.1097/00005131-199701000-00011
8. Vallier HA, Nork SE, Barei DP, Benirschke SK, Sangeorzan BJ. Talar neck fractures: results and outcomes. *J Bone Joint Surg Am.* 2004; 86(8): 1616-24.
9. Cierny G 3rd, Cook WG, Mader JT. Ankle arthrodesis in the presence of continuous sepsis. Indications, methods, and results. *Clin Podiatr Med Surg.* 1990; 7(3): 545-63.
10. Fragomen AT, Borst E, Schachter L, Lyman S, Rozbruch SR. Complex ankle arthrodesis using the Ilizarov method yields high rate of fusion. *Clin Orthop Relat Res.* 2012; 470(10): 2864-73. doi: 10.1007/s11999-012-2470-9
11. DeHeer PA, Catoire SM, Taulman J, Borer B. Ankle arthrodesis: a literature review. *Clin Podiatr Med Surg.* 2012; 29(4): 509-27. doi: 10.1016/j.cpm.2012.07.001
12. Ogilvie-Harris DJ, Fitsialos D, Hedman TP. Arthrodesis of the ankle. A comparison of two versus three screw fixation in a crossed configuration. *Clin Orthop Relat Res.* 1994; (304): 195-9.
13. Gruen GS, Mears DC. Arthrodesis of the ankle and subtalar joints. *Clin Orthop Relat Res.* 1991; (268): 15-20.
14. Boer R, Mader K, Pennig D, Verheyen CC. Tibiotalocalcaneal arthrodesis using a reamed retrograde locking nail. *Clin Orthop Relat Res.* 2007; 463: 151-6.
15. Klos K, Drechsel T, Gras F, Beimel C, Tiemann A, Hofmann GO, Mückley T. The use of a retrograde fixed-angle intramedullary nail for tibiocalcaneal arthrodesis after severe loss of the talus. *Strategies Trauma Limb Reconstr.* 2009; 4(2): 95-102. doi: 10.1007/s11751-009-0067-y
16. Williams JE Jr, Marcinko DE, Lazerson A, Elleby DH. The Calandruccio Triangular Compression Device. A schematic introduction. *J Am Podiatry Assoc.* 1983; 73(10): 536-9. doi: 10.7547/87507315-73-10-536
17. Dennison MG, Pool RD, Simonis RB, Singh BS. Tibiocalcaneal fusion for avascular necrosis of the talus. *J Bone Joint Surg Br.* 2001; 83(2): 199-203. doi: 10.1302/0301-620x.83b2.11500
18. Moeckel BH, Patterson BM, Inglis AE, Sculco TP. Ankle arthrodesis. A comparison of internal and external fixation. *Clin Orthop Relat Res.* 1991; (268): 78-83.

19. Koller H, Assuncao A, Kolb K, Holz U. Reconstructive surgery for complete talus extrusion using the sandwich block arthrodesis: a report of 2 cases. *J Foot Ankle Surg.* 2007; 46(6): 493-8. doi: 10.1053/j.jfas.2007.08.008
20. Myerson MS, Neufeld SK, Uribe J. Fresh-frozen structural allografts in the foot and ankle. *J Bone Joint Surg Am.* 2005; 87(1): 113-20. doi: 10.2106/JBJS.C.01735
21. Harnroongroj T, Vanadurongwan V. The talar body prosthesis. *J Bone Joint Surg Am.* 1997; 79(9): 1313-22. doi: 10.2106/00004623-199709000-00005
22. Taniguchi A, Takakura Y, Sugimoto K, Hayashi K, Ouchi K, Kumai T, et al. The use of a ceramic talar body prosthesis in patients with aseptic necrosis of the talus. *J Bone Joint Surg Br.* 2012; 94(11): 1529-33. doi: 10.1302/0301-620X.94B11.29543
23. Tanaka Y, Takakura Y, Kadono K, Taniguchi A, Hayashi K, Iida J, et al. Alumina ceramic talar body prosthesis for idiopathic aseptic necrosis of the talus. *Key Eng Mater.* 2003; 240-242: 805-8. doi: 10.4028/www.scientific.net/KEM.240-242.805
24. Lachiewicz PF, Funcik T. Factors influencing the results of open reduction and internal fixation of tibial plateau fractures. *Clin Orthop Relat Res.* 1990; (259): 210-5.
25. Kitaoka HB, Alexander IJ, Adelaar RS, Nunley JA, Myerson MS, Sanders M. Clinical rating systems for the ankle-hindfoot, midfoot, hallux, and lesser toes. *Foot Ankle Int.* 1994; 15(7): 349-53. doi: 10.1177/107110079401500701
26. Canale ST, Campbell WC. St Louis Campbell's Operative Orthopaedics. 10th ed. Vol 4. St Louis, MO: Mosby; 2003. 4283 p.
27. Bhowmick K, Gunasekeran C, Varghese VD, Livingston A, Jepegnanam TS, Daniel AJ, et al. Efficacy of Antibiotic-loaded Poly (Methyl Methacrylate) Beads in Orthopaedic Infections. *J Clin Diag Res.* 2018; 12(9). doi: 10.7860/JCDR/2018/35222.11977
28. Kolker D, Wilson MG. Tibiocalcaneal arthrodesis after total talectomy for treatment of osteomyelitis of the talus. *Foot Ankle Int.* 2004; 25(12): 861-5. doi: 10.1177/107110070402501204
29. Jaffe KA, Conlan TK, Sardis L, Meyer RD. Traumatic talectomy without fracture: four case reports and review of the literature. *Foot Ankle Int.* 1995; 16(9): 583-7. doi: 10.1177/107110079501600913
30. Ochman S, Evers J, Raschke MJ, Vordemvenne T. Retrograde nail for tibiotalocalcaneal arthrodesis as a limb salvage procedure for open distal tibia and talus fractures with severe bone loss. *J Foot Ankle Surg.* 2012; 51(5): 675-9. doi: 10.1053/j.jfas.2012.04.015
31. Jeng CL, Campbell JT, Tang EY, Cerrato RA, Myerson MS. Tibiotalocalcaneal arthrodesis with bulk femoral head allograft for salvage of large defects in the ankle. *Foot Ankle Int.* 2013; 34(9): 1256-66. doi: 10.1177/1071100713488765
32. Backus JD, Ocel DL. Ankle Arthrodesis for Talar Avascular Necrosis and Arthrodesis Nonunion. *Foot Ankle Clin.* 2019; 24(1): 131-42. doi: 10.1016/j.fcl.2018.11.004
33. Scott DJ, Steele J, Fletcher A, Parekh SG. Early Outcomes of 3D Printed Total Talus Arthroplasty. *Foot Ankle Spec.* 2020; 13(5): 372-7. doi: 10.1177/1938640019873536
34. Rammelt S. Secondary correction of talar fractures: asking for trouble? *Foot Ankle Int.* 2012; 33(4): 359-62. doi: 10.3113/FAI.2012.0359
35. Abd-Ella MM, Galhoum A, Abdelrahman AF, Walther M. Management of Nonunited Talar Fractures With Avascular Necrosis by Resection of Necrotic Bone, Bone Grafting, and Fusion With an Intramedullary Nail. *Foot Ankle Int.* 2017; 38(8): 879-84. doi: 10.1177/1071100717709574
36. McBryde A, Chiasson B, Wilhelm A, Donovan F, Ray T, Bacilla P. Syndesmotic screw placement: a biomechanical analysis. *Foot Ankle Int.* 1997; 18(5): 262-6. doi: 10.1177/107110079701800503
37. Smith JT, Chiodo CP, Singh SK, Wilson MG. Open ankle arthrodesis with a fibular-sparing technique. *Foot Ankle Int.* 2013; 34(4): 557-62. doi: 10.1177/1071100713477617
38. Clowers BE, Myerson MS. A novel surgical technique for the management of massive osseous defects in the hindfoot with bulk allograft. *Foot Ankle Clin.* 2011; 16(1): 181-9. doi: 10.1016/j.fcl.2010.12.005