

# RADIOLOGICAL AND FUNCTIONAL OUTCOME POST FIXATION IN UNSTABLE PROXIMAL FEMUR FRACTURE: COMPARISON BETWEEN PROXIMAL FEMORAL NAIL ANTIROTATION (PFNA) AND PROXIMAL FEMORAL LOCKING COMPRESSION PLATE (PFLCP)

Zaraihah MR<sup>1</sup>, Nurhafizah MN<sup>2</sup>, Shukri Y<sup>2</sup>, Nazri MY<sup>1</sup>

<sup>1</sup>Orthopedics Department, IIUM Medical Centre

<sup>2</sup>Orthopedics Department, Hospital Sultanah Nurzahirah

## INTRODUCTION:

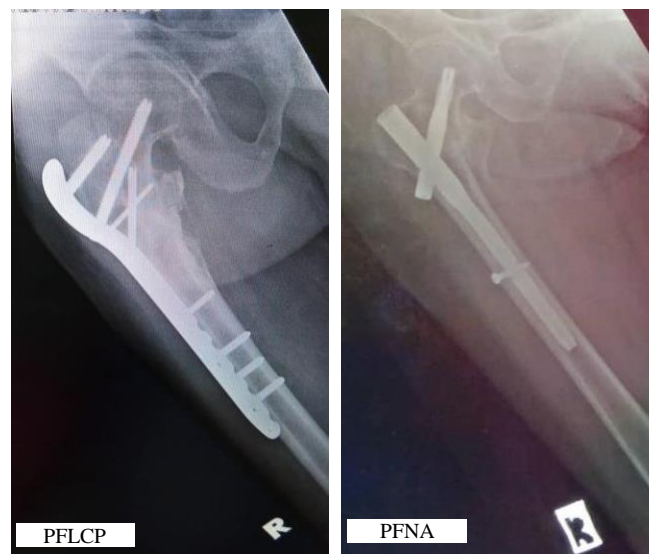
Incidence of unstable proximal femoral fracture is increasing in trend and the treatment is challenging. Operative treatment offers various selection of implant including plate and intramedullary nail. The purpose of this study is to compare radiological and functional outcome between both implants: PFNA and PFLCP.

## METHODS:

This is a single centre observational cohort study involving all patients with unstable proximal femur fracture, admitted from January 2012 till December 2017. Plain pelvic and hip radiographs at immediate, 6 month and 1 year post-operative. Neck shaft angle (NSA) and its difference on contralateral side measured. Radiological outcome evaluated prevalence of varus malalignment and quality of fracture reduction. Functional outcome is measured by using Lower Extremity Functional Scale (LEFS).

## RESULTS:

Sample population is 91 patients. Radiological and functional outcome didn't differ significantly ( $p > 0.05$ ) but PFLCP group had shown significant shorter union time (table 1,2).



Variable	PFNA (n=44)	PFLCP (n=47)	p-value
<b>Age (years)</b>			
Mean	57.45	50.23	0.145
SD	23.54	23.31	
<b>Gender</b>			
Male	28	33	0.505
Female	16	14	
<b>Time from injury to surgery (days)</b>			
Mean	12.89	12.23	0.533
SD	4.34	5.48	
<b>Time of fracture union (months)</b>			
Mean	11.44	9.15	0.018
SD	4.95	4.03	
<b>Fracture type</b>			
AO 31 A.2	18	16	0.716
AO 31 A.3	17	18	
<b>Seinsheimer type</b>			
type 3a	8	7	
type 4	0	0	0.381
type 5	2	5	
<b>Varus malalignment (post operation)</b>			
Immediate	4	7	
6 months	19	16	
1 year	24	21	
<b>LEFS Score</b>			
Mean	64.19	68.50	0.113
SD	13.65	11.73	

Reduction quality (NSA difference at immediate post-operative)	PFNA, (n,%)	PFLCP, (n,%)	p-value
Good (<5 degree)	41 (93.2)	41 (87.2)	0.487
Acceptable(5-10 degree)	3 (6.8)	6 (12.8)	*Fisher exact test
Poor (>10 degree)	0	0	
<b>Total</b>	<b>44 (100)</b>	<b>47 (100)</b>	

## DISCUSSIONS:

Association of radiological and functional outcome between both implants was statistically insignificant ( $p > 0.05$ ), which concurrent with the study by Singh AK, 2017, Li GX, 2012.

## CONCLUSION:

Both implants were effective in treating unstable proximal femur fractures.

## REFERENCES:

1. Singh AK et al. Treatment of Unstable Trochanteric Femur Fracture: PFNA versus PFLCP. Am. Journal. 2017.