

Functional Outcome Of Surgical Treatment Of Displaced Acetabular Fracture By Anterior Approach

¹Koh KH, ¹ Mohd Asihin MA, ¹Ahmad AR, ¹Ganaisan P

¹ Orthopaedic and Traumatology Department, Hospital Tuanku Ja'afar, Jalan Rasah, Bukit Rasah, 70300 Seremban

INTRODUCTION:

Treatment of acetabular fractures has evolved tremendously for the past decades with the primary aim to restore joint congruency and prevent early post traumatic arthritis. The purpose of this study is to evaluate the functional outcome of surgical fixation of displaced acetabular fractures by anterior approach in our local settings.

MATERIALS & METHODS:

This is a retrospective clinical study of 52 patients which underwent fixation surgery for displaced acetabular fractures in Hospital Tuanku Ja'afar Seremban, Negeri Sembilan from April 2014 to March 2017. All patients had fixation done via anterior approach (ilioinguinal or modified Stoppa approach). Patients with severe traumatic brain injury and/or spinal cord injury and pre-morbidly non-ambulatory patients were excluded. Follow up range from ten months to three years.

RESULTS:

There were 37 males and 15 females with mean age of 35 years old. Only 17 patients were contactable and agreeable for the study. The average Majeed score was 83.5 (range between 49-100). One patient sustained foot drop as a result of sciatic nerve injury and another had surgical site infection. Both of these patients scored fair outcome. There was no reported incidence of sexual dysfunction i.e. erectile dysfunction in all male subjects.

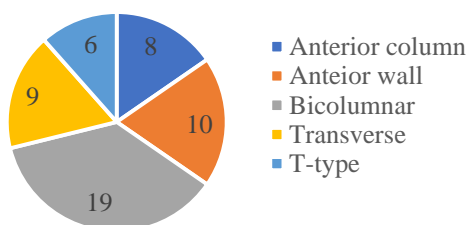


Figure 1: Type of acetabular fracture involved

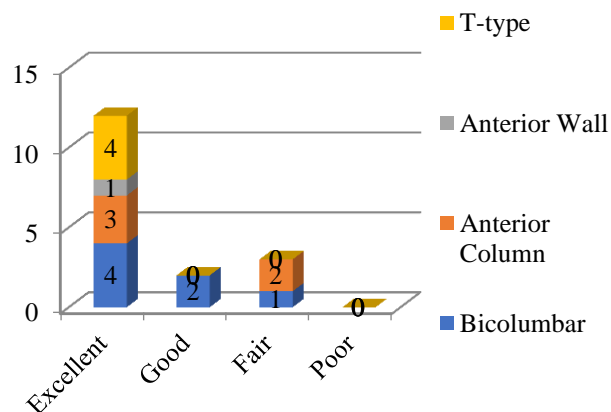


Figure 2: Majeed score distribution

DISCUSSIONS:

Good to excellent functional outcome was noted in majority of acetabular fracture treated surgically via anterior approach in our case series. Only those patients with post-operative complication reported fair outcome. We concluded that acetabular fracture treated via anterior approach (ilioinguinal approach or modified Stoppa) is a viable option with predictable outcome. However, the study requires larger sample size and continuous data collection and analysis to further validate our finding. Our finding using Majeed score is consistent with other findings using similar or different method of data analysis.

CONCLUSION:

The overall functional outcome of acetabular fixation using anterior approach was excellent. This was achieved by fracture union after anatomical reduction of acetabulum.

REFERENCES:

1. Majeed SA. Grading the outcome of pelvic fractures. J Bone Joint Surg.1989; 71-B: 304-306 (Table I and II, page 305).