

A Case Report On Reconstruction Of Degloving Injury Of Finger With Groin Flap Using Local Anaesthesia

¹Liew MY, ²Ahmad AA, ³Ahmad Hanif KA, ¹Ahmad AR

¹Department of Orthopaedics, Hospital Tuanku Ja'afar, Jalan Rasah, Bukit Rasah, 70300 Seremban, Negeri Sembilan

²Department of Orthopaedics, International Medical University, Jalan Dr Muthu, Bukit Rasah, 70300 Seremban, Negeri Sembilan

³Department of Orthopaedics, Hospital Port Dickson, KM 11, Jalan Pantai, 71050 Port Dickson, Negeri Sembilan

INTRODUCTION:

Degloving injuries of fingers is a challenge in its treatment because of irreplaceable quality of skin that has been lost, exposure of delicate structures, importance of providing early cover for remaining tissues to restore function and complexity of reconstruction¹. As such, these injuries are often referred to tertiary centres with hand surgery unit to be performed by hand surgeons. This often results in delay of treatment and predisposes the remaining tissues to infection and necrosis. This case report aim to demonstrate that reconstruction surgery such as groin flap for degloving injuries of fingers need not necessarily be performed at a hand surgery unit by a hand surgeon.

MATERIALS & METHODS:

Local anaesthesia was used. Origin of superficial circumflex iliac artery (SCIA) from the femoral vessels is determined at 2-finger width (2-3 cm) below the inguinal ligament and 2.5 cm inferior to palpable femoral artery pulse². A line was drawn from this site and parallel to the inguinal ligament to estimate the course of SCIA. The flap design was centered about this axis with 2-finger width above the inguinal ligament as upper border and 2-finger width below the vascular origin as lower border³. Base of flap is medial border of the sartorius. Additional 2 to 3 cm is added to total length of flap to allow mobility during the postoperative period².

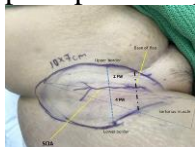


Figure 1: Estimation of SCIA also confirmed with ultrasound and flap design³.

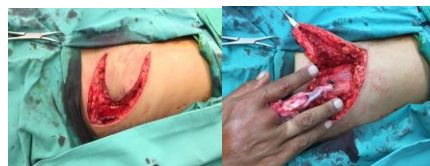

Figure 2: Groin flap prepared and finger implanted into it.

RESULTS:

No skin necrosis noted at the base and inferior extension of groin flap during the 3 week period before flap division. Following flap division, there is no loss of skin and edges of flap donor site apposed nicely leaving behind a good scar. Flap on the finger also appeared healthy.

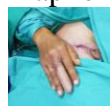

Figure 4: Reconstructed finger with groin flap 3 weeks after operation.

DISCUSSIONS:

Aims of reconstruction are to provide thin, pliable and sensate skin that prevents contracture and stiffness whilst also cosmetically acceptable¹. Groin flap is an axial-patterned cutaneous flap based on SCIA, which can provide soft-tissue coverage to defects on the degloved finger. This flap has the advantage of primary donor site closure, hidden donor site and vascular reliability¹. Presumed disadvantage of groin flap is the discomfort experienced by the patient during the time required before flap division. This can be reduced by proper planning of flap orientation and length².

CONCLUSION:

Reconstruction of degloving injuries on finger using groin flap is achievable by any orthopaedic-trained surgeons with a good knowledge of groin regional anatomy and basic