

## Modified Sling Procedure: A Novel Method For Fixation Of AC Joint Disruption

<sup>1</sup>Wong AWF, <sup>1</sup>Leong WH

<sup>1</sup>Department of Orthopaedic Surgery, Sarawak General Hospital, Kuching, Sarawak

### INTRODUCTION:

We present here a method of stabilization of the acromioclavicular and coracoclavicular joint disruption by combining together tightrope and sling procedure. We feel that this technique is appealing as it is easily reproducible, cost effective, and has lower rate of complications associated with the standard fixation technique.

### MATERIALS & METHODS:

Mr A, underwent a modified sling procedure for an acromioclavicular disruption (Rockwood type III) sustained after a road traffic accident. He was subsequently evaluated for radiological and functional outcome post operatively, as well as observed for hardware failure in subsequent follow ups.

Patient in supine with head elevated at approximately 20 degrees. A 5cm incision was made vertically directly over coracoclavicular ligament down to coracoid process, advancing through intermuscular plane taking care to avoid the cephalic vein. Reduction was done using downward pressure on the clavicle. 3 Ethibond 5 sutures were passed under the coracoid process and through a single 3.2mm drill hole on the clavicle, then tied down using a 4 hole mini plate tied as a horizontal post. Wound closure was then performed in layers.

### RESULTS:

Immediate post operative radiograph showed a well reduced ACJ. Patient was put on an arm sling and physio started 2 weeks post-operatively. At 12<sup>th</sup> week follow up, patient had regained full ROM of the affected shoulder and radiograph revealed a well healed dissociation. DASH and Oxford Shoulder scores showed good functional outcome.

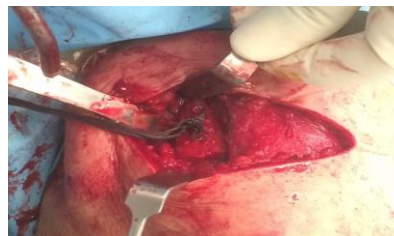

Figure 1: Intraoperative picture

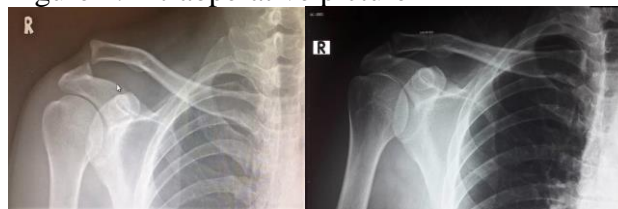


Figure 2: Preoperative and postoperative radiograph

### DISCUSSIONS:

AC and CC reconstruction techniques carry a distinct complication profile involving clavicle/coracoid fractures from hardware failure, as well as involvement of costly implants.

### CONCLUSION:

The modified sling procedure aims to reduce the incidence of clavicle/coracoid fractures, as well as concurrently being cost-effective while maintaining good functional outcome.

### REFERENCES:

1. Coracoid fracture with recurrent AC joint separation after tight rope repair. *Radiology case reports Volume 6, Issue 4, 2011*
2. Early failure of coracoclavicular ligament reconstruction using tightrope system. *Acta Orthop. Belg.*, 2016, 82, 119-123