

Alternative Treatment Of Tibialis Posterior Tendon Avulsion Fracture

¹Hussin AR, ¹Khor JK, ¹Tahir SH,

¹Arthroscopic and Sports Injury Unit, Orthopaedics and Traumatology Institute, Hospital Kuala Lumpur

INTRODUCTION:

An avulsion fracture of the tibialis posterior tendon is a rare injury. It usually occurs in young athletes because of an induced trauma. ⁽¹⁾ It is the most common fracture of the navicular bone, often associated with ligamentous injuries and results from twisting forces on the mid foot. ⁽²⁾ Symptoms are pain distal and posterior to the medial malleolus, loss of stability of the foot. ⁽³⁾ These fractures are commonly treated conservatively, except for avulsion of the posterior tibial tendon insertion (tuberosity fracture) which have better outcome with surgical intervention especially in a case of complete wide separation from the insertion site. ⁽¹⁾⁽⁵⁾

CASE:

A 20-year-old student was referred to our orthopaedic clinic with complaints of pain and swelling over the medial aspect of left foot after twisted ankle injury for a month duration with no sign of improvement.

Physical Examination(Fig1):

Left Ankle: Swelling and tenderness over medial aspect, inferior to medial malleolus. Unable to perform single leg heel rise test

X-ray (Fig2): Avulsion fracture of navicular

Management:

Patient underwent open surgery where the small avulsed piece of the bone excised, and the remaining tendon reattached to the insertion site of navicular bone by Y-Knot RC 2.8mm anchor suture with Nicky's sliding knot. (Figure3a) Post-surgery patient was casted for 6 weeks with the ankle in flexion and inversion. Reassessment after surgery shows good outcome. (Figure3b&c)

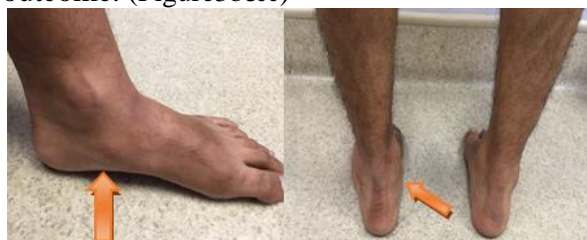

Figure 1: Swelling and tenderness over insertion of tibialis posterior tendon over medial aspect of left ankle

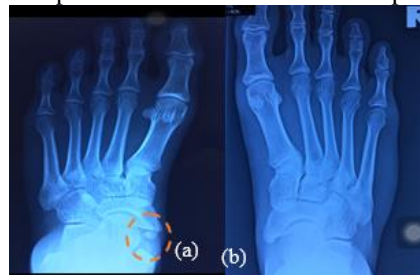

Figure 2: X-ray of Left Foot (a) showed avulsion fracture over left navicular bone, compared to Right Foot X-ray(b)

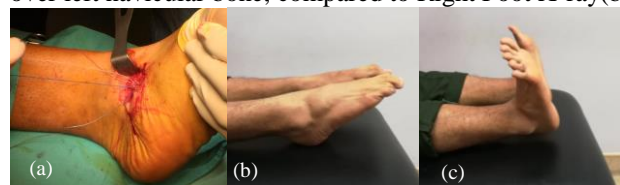


Figure 3: a) Anchor suture used to reattach tendon to insertion site. Assessment 6 weeks post operation: b) Plantarflexion c) Dorsiflexion. Patient also able to perform single leg heel rise test and tiptoeing

DISCUSSIONS:

Demand on the tibialis posterior tendon is high during gait particularly just after heel strike. Localized hypo vascularity in a critical zone is vulnerable to injury (tendon rupture). Younger patients tend to sustain a traumatic avulsion of the tendon at its insertion into the navicular bone. Middle aged/elderly patients often suffer a mid-substance inflammatory/ degenerative tear. Misdiagnosed is not uncommon. ⁽⁴⁾

CONCLUSION:

Surgical treatment of avulsion fracture of tibialis posterior tendon has better outcome than conservative treatment, especially in young patients. We recommend reattachment of tendon to insertion site of navicular bone using anchor suture. It provides good result in term of pain relief and clinical stability.

REFERENCES:

1. Kenneth JohnsonMD(1983)Tibialis Posterior Tendon Rupture
2. Melvin H. Jahss (1982) Spontaneous Rupture of the Tibialis Posterior Tendon: Clinical Findings, Tenographic Studies, and a New Technique of Repair