

Spinal Epidural Abscess In Neonate : A Case Report

¹Tiw ZS, ¹IM Akmal, ¹WAR Zainuddin, ¹S Razip

¹Department Orthopaedic, Hospital Pakar Sultanah Fatimah, Jalan Salleh 84000 Muar Johor

INTRODUCTION:

Incidence of spinal epidural abscess is rare in neonates^{3,4}. It is higher in children under 2 years and those more than 12⁴. Early signs and symptoms are nonspecific, usually manifest in neurological deficit.

CASE REPORT:

A 10 month old adopted boy with no antenatal complications and born via spontaneous vaginal delivery, presented initially with fever and cough which then was treated as pneumonia. Subsequently came back after 2 months with shortness of breath, unable to sit without support and reduced movement over bilateral lower limbs. MRI was done and showed T4 to T8 spondylodiscitis with paravertebral enhancing collection causing cord compression and right mid and lower lobe lung consolidation.

(Figure 1 & 2).

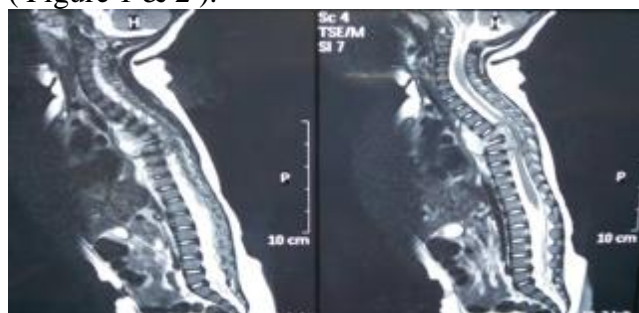


Figure 1 : Sagittal view of MRI Spine T₂ weighted.

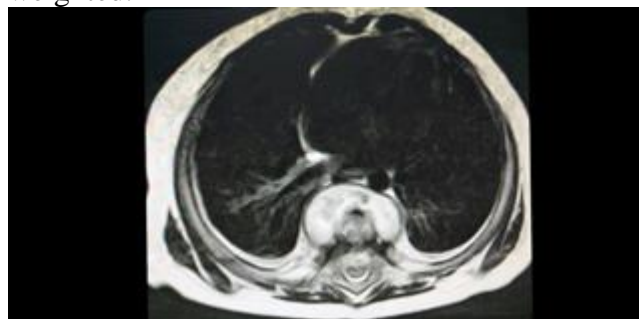


Figure 2 : Axial view of MRI Spine at level of T7.

Patient was started on anti-TB and antibiotic for 6 weeks despite negative in all initial tuberculosis screening. However, lower limb weakness persisted and repeated MRI showed progression of paravertebral collection extending from T3 to T9 with cord compression and oedema.

Patient underwent spinal decompression with drainage and was put on body cast. HPE and biopsy was sent for investigation.

DISCUSSION:

Spinal epidural abscess usually is very rare in neonate without any history of spinal instrumentation⁴. It's usual main route is through hematogenous spread from primary site^{3,4}. Diagnosis are usually from clinical history and radiological finding². The aim of treatment is to eradicate the infection so that good recovery from neurological deficits and minimal spinal residual deformity.

CONCLUSION:

Spinal epidural abscess can be treated with medical treatment. However surgical intervention may be required if there is spinal instability, worsening neurology or poor response with medical treatment.

REFERENCES:

1. Krishnamohan P. Spinal Epidural Abscess. *Curr Infect Dis Rep* 2014 Nov
2. Ravindra Kumar Garg. Spinal Tuberculosis: A Review. *J Spinal Cord Med* 2011 Sep34(5): 440-454
3. Najet Farideh. Spinal Epidural Abscess in Neonate. *Curr Infect Dis Rep* 2014 Nov 16(11): 436
4. Tang K, Xenos C. Spinal Epidural Abscess in Neonate. *Child's Nerv Sys.* 2001 Oct 17(10): 629-631