

Community Acquired MRSA Spinal Epidural Abscess In A Healthy Young Girl

¹Mohd Aslam MF, ¹M Yusuf H, ¹Azmi A, ¹Mohamad F

¹Orthopaedic Department, Hospital Kuala Lumpur, Jalan Pahang, 53000 Kuala Lumpur

INTRODUCTION:

Spinal epidural abscess (SEA) is unusual bacterial infections requiring prompt diagnosis and treatment to prevent devastating neurologic sequelae. The predominant pathogen in spinal epidural abscess is *Staph aureus*¹. We presented a case of Community Acquired - Methicillin Resistant Staph Aureus (CA-MRSA) causing SEA.

CASE REPORT:

11 years old girl presented with severe pain over right hip and buttock for one week associated with fever and refusal to walk. Symptoms started after fell in a sitting position at the playground. There was mild tenderness at the right anterior hip and gluteal region. There was no spinal tenderness. The gluteal region was swollen. There were spikes of temperature up to 39.7°C. The white cell count was normal (8.1 x 10³/uL) but ESR and CRP were elevated (>120 mm/hr, 21.9). Radiographs and ultrasound were normal. She was treated as septic arthritis of right hip joint. Blood culture grew gram positive cocci thus, started on Cloxacillin. However, symptoms were not improving. On day 5 of admission, she developed acute urinary retention requiring catheterization. The bladder was distended with loss of perianal sensation and lax anal tone, in keeping with cauda equina syndrome. Urgent MRI showed large right piriformis and presacral collection with intraspinal, right paraspinal extension, adjacent right sacral alar osteomyelitis and bilateral L5 to S3 nerve roots impingement. We proceeded with right L5 laminotomy and L5/S1 decompression urgently. Blood and tissue cultures grew MRSA and based on sensitivity, antibiotic was changed to intravenous Vancomycin and Linezolid. After two weeks, pain had resolved, able to pass urine voluntarily and walking. She completed two weeks of Linezolid and six weeks of Vancomycin. A repeat MRI at six weeks showed abscess

collection was almost resolved with residual inflammatory changes of sacral alae.

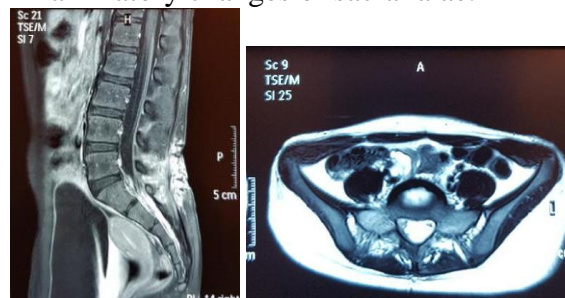


Figure 1 & 2; (MRI Lumbar and Pelvis): shows presacral collection with intraspinal, right paraspinal extension, adjacent right sacral alar osteomyelitis

DISCUSSIONS:

The classic presentation of SEA is a triad of back pain, fever and neurological deficits² which was not present in our case. Diagnosis was made when she developed cauda equina syndrome with positive MRI findings. Urgent decompression was performed to avoid permanent neurological deficits. SEA is a diagnostic challenge especially in children with CA-MRSA increases its severity. There is increasing prevalence of CA-MRSA infections in children without risk factors and could potentially leads to severe infection and even death^{3,4}. Prolonged antibiotics coupled with surgical decompression are needed to prevent devastating complications.

CONCLUSION:

Clinical presentations of SEA in children may not be obvious until cauda equina has developed. Urgent decompression is required to avoid permanent neurologic sequelae. Antibiotic therapy is equally important particularly in dealing with CA-MRSA, known to cause severe infection. In our case, prolonged antibiotics were given in view of severe infection.

REFERENCES:

1. Sapico FL. Microbiology and antimicrobial therapy of spinal infections. Orthop Clin North Am 1996; 27:9-13.